8 A-262

MORBID HISTOLOGY

Digitized by the Internet Archive
in 2025

https://archive.org/details/textbookofmorbid0000rube

A TEXTBOOK

OF

MORBID HISTOLOGY

FOR

STUDENTS AND PRACTITIONERS

BY

RUBERT BOYCE, M.B., M.R.C.S.

ASSISTANT PROFESSOR OF PATHOLOGY IN UNIVERSITY COLLEGE, LONDON

WITH 130 COLOURED ILLUSTRATIONS

LONDON
H. K. LEWIS, 136 GOWER STREET, W.C.
1892

4424

PRINTED BY
H. K. LEWIS, 136 GOWER STREET
LONDON, W.C.



TO

VICTOR HORSLEY, B.S., F.R.C.S., F.R.S.

PROFESSOR OF PATHOLOGY IN UNIVERSITY COLLEGE, LONDON,

THIS WORK IS DEDICATED

IN ADMIRATION OF THE READINESS WITH WHICH

HE IS EVER WILLING TO GIVE HIS ASSISTANCE TO THE STUDENT

OF SCIENCE

AND TO SHARE WITH HIM HIS RICH EXPERIENCE

AND

IN GRATEFUL ACKNOWLEDGMENT OF THAT FRIENDSHIP

TO WHICH THE AUTHOR OWES SO MUCH

PREFACE.

In the following pages the author has endeavoured to lay before the reader a short account of the chief histological changes met with in disease. An endeavour has also been made to obtain as natural an arrangement of the subject matter as possible, little stress being laid upon arbitrary methods of classification. It is owing in a very great measure to the teaching of Professor Horsley that this plan has been followed.

Pains have been taken to make both the illustrations and descriptive matter as accurate as possible.

The author has had the advantage of a large amount of pathological material, consisting in great part of that collected by Professor Horsley, and of that contained in the Museum of University College, which, the successive Curators, Mr. Stonham and Mr. Lawrence, kindly permitted the author to examine. Friends also have rendered valuable assistance in lending and giving material, and it is a great pleasure, in this place, to thank Dr. Mott for numerous slides and material; more especially for the slides from which figs. 82, 87, 88, and 108 were made. In like manner to thank Dr. Crocker and Dr. John Williams, Drs. Ransom, Gray, Herbert Spencer, Risien Russell, Bruce, Murray, Collins

and R. G. Cunningham, Messrs. W. Spencer, Johnson, Dean, White, J. L. Hamilton, and Stonham.

The author is deeply grateful for the friendly advice and assistance of his former teacher, Professor Marcus Beck.

The illustrations are micro-photographs with one exception, and the author takes this opportunity of thanking his friend Walter Collett, Mr. Swift, and Mr. Lewis for valuable assistance in this connection. Mr. Lewis has spared no pains in the selection of a good process for reproducing the photographs, and in colouring and printing.

For his kind assistance and guidance in revising the early chapters the author is greatly indebted to Professor Horsley; he also desires to express his thanks to Dr. Deansly and Mr. L. Hill for subsequent help in this connection. Mr. Butler Harris has kindly undertaken the drawing up of the index, and for the care and labour which he has bestowed upon this most useful portion of the work the author is extremely grateful.

Pathological Department,
University College, London,
April, 1892.

CONTENTS.

INTRODUCTION—By Professor Horsley, F.R.S.

CHAPTER I.

DIRECTIONS FOR HARDENING, EMBEDDING, CUTTING, STAINING, etc. . . . . *pages* 1-19

CHAPTERS II.—X.

OUTLINES OF INFLAMMATION, REPAIR, DEGENERATION AND NEOPLASMS.

Chap. II.—The acute phenomena of inflammation—the marked retrogressive tissue changes and the vascular phenomena. The various varieties of inflammation of the lungs, serous and mucous surfaces and parenchymatous organs. Pus, suppuration and the acute abscess; the slough vesicle and pustule . . . . . *pages* 20-37

Chap. III.—The fate of the exudates and repair, or the reparative side of inflammation. The means of repair; the macrophages and organisation *pages* 38-46

Chap. IV.—Progressive tissue reaction or inflammatory hyperplasia. The granuloma. The fibrous, hyaline and caseous transformation. The chronic sinus and abscess. Catarrhal inflammation . . . *pages* 47-59

Chap. V.—Absorption of solid bodies. Healing. Repair of muscle, nerve and bone . . . . . *pages* 60-73
(*See also the Special Tissue systems*).

Chap. VI.—Degeneration, pigmentation and allied processes. Degeneration of the differentiated cell substance. The ground tissue changes—the mucoid and colloid, the hyaline and lardaceous. Iron, blood, bile and melanin pigmentation. The crystals and crystalline deposits. Calcification and coagulation necrosis . . . . . *pages* 74-97

CHAP. VII.—The infective processes—chiefly the mycotic. The localised and spreading processes and general infection. The primary lesion, infective embolism, metastasis and pyæmia. The changes associated with fever and cachexia. *Examples*:—The specific sores, spreading gangrene, diphtheria, pneumonia, typhoid, cholera, "pyæmia," glanders, anthrax, relapsing fever and malaria. The zooparasitical granulomata, actinomycosis, tuberculosis, pseudo-tuberculosis and leprosy. Syphilis. The hyphal fungi of the skin and lung . . . . . *pages* 98-125

CHAP. VIII.—The simple tumours and tumour-like hyperplasias of the more highly specialised tissues, and those of the tissues of the framework. The rapidly growing and malignant forms of the preceding (the sarcomata). The simple and malignant epithelial tumours, superficial and glandular. The psoriases, irritation and congenital growths; the malignant transformation *pages* 126-178

CHAP. IX.—Cystic neoplasms; inflammatory and congenital cystic formations *pages* 179-197

CHAP. X.—Certain congenital formations. Branchiogenous, hypophyseal and coccygeal tumours. Dermoids . . . . *pages* 198-207

CHAPTERS XI.—XX.

OUTLINES OF THE DISEASES OF THE SPECIAL SYSTEMS.

CHAP. XI.—The vascular system. Blood. Thrombosis. Embolism and infarction. Lesions of the heart and vessels. The varieties of endarteritis *pages* 208-224

CHAP. XII.—The adenoid tissues. The lymph glands, spleen and marrow. Inflammatory hyperplasia and leucocytosis. Malignant disease, lymphadenoma and leukæmia . . . . . *pages* 225-237

CHAP. XIII.—Addison's disease, myxœdema and acromegaly. Rickets, osteomalacia and Paget's disease. Rheumatic arthritis, tubercular and syphilitic osteitis. Hyperostosis and osteosarcomata. Diseases of the skin—atrophy and hyperplasia . . . . . *pages* 238-256

CHAP. XIV.—The kidney. Action of toxic agents, of heat, of ligature of the renal artery, of the renal vein, of the ureter. Hydronephrosis. Suppurative nephritis. The nephritis of cachexia and fever, of diabetes, of lead, alcohol and gout; the nephritis of Bright. The arterio-sclerotic and granular contracted kidney. The primary tumours of the kidney. The pelvis, ureter and bladder . . . . . *pages* 257-280

CHAP. XV.—The liver. The parenchymatous changes. Some forms of cirrhosis. Occlusion of the hepatic artery, of the portal vein, of the bile ducts. Acute yellow atrophy. The hepatitis of cachexia. Tumours of the liver and gall bladder. The pancreas. The peritoneum . . . *pages* 281-304

CHAP. XVI.—The mouth, stomach and intestines. Inflammation and necrosis. Inflammatory hyperplasia. The gastritis of anæmia, phthisis and cachectic conditions. Typhoid, dysentery and cholera. Tubercle. Effects of toxic agents. Tumours . . . . . *pages* 305-319

CHAP. XVII.—The respiratory system. The nasal cavity and larynx. Pachydermia laryngis and laryngeal tumours. The lungs and pleuræ. Inhalation experiments, pneumokoniosis. Bronchopneumonia, chronic pneumonia, croupous pneumonia. The pneumonias of tubercle, actinomyces and syphilis, verminous pneumonia. Atelectasis, bronchiectasis, emphysema and cysts. Embolism and infarction. Tumours . . *pages* 320-341

CHAP. XVIII.—The genital organs and breast. Lesions of the prostate, accessory genital glands and urethra. Of the testis and ovary. Of the tubes, uterus and vagina. Hyperplasia (endometritis), cancer and the rhabdomyomata. The breast; a classification of tumours into congenital and acquired; division of mammary tumours . . . . . *pages* 342-364

CHAP. XIX.—The muscular and nervous systems. Atrophy, degeneration and tumours of the muscles. The nervous system. Büngner's neuroblast theory. Secondary tract degeneration. Atrophy, pigmentation and fatty degeneration. Acute myelitis and softening. The chief scleroses of the brain and spinal cord – disseminated sclerosis, tabes and congenital tabes. Meningites. Neurites. Syringomyelia and tumours of the nerves, spinal cord and brain. Certain tropho-neuroses. Perforating ulcer, Raynaud's disease, Morvan's disease. Sclerodermie and sclerodactyly. *pages* 365-407

CHAP. XX.—The tissue reactions excited by the animal parasites. Acute inflammation and necrosis, hyperplasia. Pneumonia verminosa and pseudotuberculosis. Enteritis and diphtheritis verminosa, Egyptian chlorosis, trichinosis, chyluria. Bilharzia disease, distomatosis. Psorospermosis and gregarinosis. Darier's disease. Miescher's tubes. Parasites and cancer *pages* 408-419

BIBLIOGRAPHY.

Arranged for the most part according to the order of the chapters . *pages* 420-456

LIST OF ILLUSTRATIONS.

FIGURE

1. Congestion in lung . . . . . *facing page* 22
2. Fibrinous exudation in pneumonia . . . . . „ 22
3 *and* 4. Corpuscular exudation in pneumonia . . . . „ 24
5. "Catarrhal pneumonia" . . . . . „ 26
6. Acute pleurisy . . . . . „ 26
7. Acute pericarditis . . . . . „ 28
8. Acute peritonitis . . . . . „ 28
9. Acute bronchitis . . . . . „ 30
10. Broncho-pneumonia . . . . . „ 30
11. Diphtheritic enteritis . . . . . „ 32
12. Acute nephritis . . . . . „ 32
13. Inflammation of areolar tissue . . . . . „ 34
14. Formation of abscess . . . . . „ 34
15. Spreading gangrene . . . . . „ 36
16. Pus . . . . . „ 36
17. Vascularisation in lung . . . . . „ 44
18. Vascularisation in lung in a thrombosed vessel . . . „ 44
19 *and* 20. Miliary tuberculosis of lung . . . . . „ 50
21. Caseation in lung . . . . . „ 52
22. Fibrosis in lung . . . . . „ 52
23. Wound of 4th day . . . . . „ 60
24. Wound of 10th day . . . . . „ 60
25. Median nerve (normal) . . . . . „ 68
26. Ulnar nerve (peripheral end after section) . . . . „ 68
27. Callus . . . . . „ 72
28. Fatty degeneration of cardiac muscle . . . . . „ 72
29. Perilobular fatty infiltration of liver . . . . . „ 78
30. Lardaceous degeneration of kidney . . . . . „ 78
31. Lardaceous degeneration of liver . . . . . „ 84
32. Lardaceous spleen . . . . . „ 84
33. Liver in pernicious anæmia . . . . . „ 90

FIGURE

34. Muscle in gout . . . . . *facing page* 90
35. A small round celled focus . . . . . „ 100
36. Kidney in ulcerative endocarditis . . . . . „ 100
37. Anthrax bacilli (œdema fluid) . . . . . „ 106
38. Anthrax bacilli in kidney . . . . . „ 106
39. Actinomycotic lung . . . . . „ 114
40. Miliary tuberculosis of lung . . . . . „ 114
41. Tubercular giant cells . . . . . „ 116
42. Gummata in liver . . . . . „ 116
43. Section of gumma . . . . . „ 120
44. Diffuse syphilitic fibrosis of lung . . . . . „ 120
45. Syphilitic cirrhosis (congenital) . . . . . „ 122
46. Syphilitic endarteritis . . . . . „ 122
47. Amputation neuroma . . . . . „ 128
48. Fibroma of uterus . . . . . „ 128
49. Fibroma of uterus more highly magnified . . . . . „ 132
50. Cutaneous fibroma . . . . . „ 132
51. Nasal polypus . . . . . „ 134
52. Adeno-fibroma of breast . . . . . „ 134
53. Fibro-papilloma . . . . . „ 136
54. Small round-celled sarcoma . . . . . „ 136
55. Infiltrating sarcoma of optic nerve . . . . . „ 150
56. Spindle celled sarcoma . . . . . „ 150
57. Giant celled sarcoma . . . . . „ 152
58. Chondro-sarcoma . . . . . „ 152
59. Papilloma . . . . . „ 156
60. Wart . . . . . „ 156
61. Papilloma of bladder . . . . . „ 158
62. Cancer of cervix uteri . . . . . „ 158
63. Warty and cancerous condition of labium . . . . . „ 162
64. Squamous epithelioma of skin . . . . . „ 162
65. Rodent ulcer . . . . . „ 166
66. Early cancer of fundus uteri . . . . . „ 166
67. Epithelioma of uterus . . . . . „ 170
68. Sebaceous adenoma . . . . . „ 170
69. Adeno-fibroma of mamma . . . . . „ 172
70. Acinous cancer of mamma . . . . . „ 172
71. Acinous cancer of mamma (hyperplasia) . . . . . „ 174

FIGURE

72. Scirrhous cancer of breast . . . . . *facing page* 174
73. Encephaloid cancer of mamma . . . . . ,, 176
74. Malignant adenoma of uterus . . . . . ,, 176
75. Columnar epithelioma of rectum . . . . . ,, 178
76. Cancer metastasis in liver . . . . . ,, 178
77. Cysto-adeno-sarcoma of ovary . . . . . ,, 182
78. Acute cystic dilatation of renal tubules . . . . ,, 182
79. Chronic interstitial nephritis and cystic dilatation . . ,, 186
80. Epithelial cyst . . . . . ,, 186
81. Wall of atheromatous cyst . . . . . ,, 199
82. Thrombus absorption . . . . . ,, 196
83. Fat emboli in lung . . . . . ,, 212
84. Infarct in kidney . . . . . ,, 212
85. Cardiac sclerosis . . . . . ,, 216
86. Acute valvular endocarditis . . . . . ,, 216
87. Fibroid basilar artery . . . . . ,, 812
88. Atheroma of artery . . . . . ,, 218
89. Leucocythæmic liver, low power . . . . . ,, 232
90. Leucocythæmic liver, high power . . . . . ,, 232
91. Gland in lymphadenoma . . . . . ,, 242
92. A rickety rib . . . . . ,, 242
93. Bony hyperplasia . . . . . ,, 248
94. Pityriasis rubra . . . . . ,, 248
95. Small-pox pustule . . . . . ,, 256
96. Granular contracted kidney . . . . . ,, 256
97. Pressure atrophy of kidney . . . . . ,, 264
98. Proliferation of glomerulus . . . . . ,, 265
99. Contracted glomerulus, chronic nephritis . . . . ,, 266
100. Surgical kidney . . . . . ,, 266
101. Congestion of kidney . . . . . ,, 268
102. Phosphorus necrosis of kidney . . . . . ,, 268
103. Parenchymatous nephritis . . . . . ,, 280
104. Cirrhosis of liver . . . . . ,, 280
105. Congested liver, low power . . . . . ,, 286
106. Congested liver, high power . . . . . ,, 286
107. Enteritis . . . . . ,, 320
108. Swollen Peyer's patch . . . . . ,, 310
109. Typhoid ulcers of intestine . . . . . ,, 312

FIGURE
110. Tubercular ulcer of intestine . . . . . *facing page* 312
111. Chronic pleurisy . . . . . ,, 332
112. Emphysema . . . . . ,, 332
113. Alcoholic neuritis, low power . . . . . ,, 372
114. Alcoholic neuritis, high power . . . . . ,, 372
115. Sclerosis of posterior root zones . . . . . ,, 380
116. Scleroses of Goll's columns . . . . . ,, 380
117. Sclerosis of posterior columns . . . . . ,, 382
118. Degeneration of pyramidal tract . . . . . ,, 382
119. Congestion of cord, hydrophobia . . . . . ,, 388
120. Acute myelitis . . . . . ,, 388
121. Anterior poliomyelitis . . . . . ,, 406
122. Acarus scabiei . . . . . ,, 406
123. Tænia mediocanellata . . . . . ,, 410
124. Tænia solium . . . . . ,, 410
125. Wall of hydatid cyst . . . . . ,, 412
126. Scolices . . . . . ,, 412
127. Trichina spiralis . . . . . ,, 414
128. Filaria sanguinis hominis . . . . . ,, 414
129. Ova of bilharzia . . . . . ,, 416
130. Flukes in a bile duct . . . . . ,, 416

ERRATA.

Page 14, *read* "Ziehl" *for* "Zeihl."
,, 15, in Pal's method *read* ·25 per cent. *for* 25 per cent.
Fig. 63, *read* "labium minus" *for* "labium minoris."
,, 64, transpose the numbers 1 and 2.
,, 74, *read* "malignant adenoma" *for* "malignant œdema."
Chap. XI., *read* "Hayem" *for* "Hyem."
Page 292, *read* "Audigé" *for* "Aucigé."

INTRODUCTION BY PROF. VICTOR HORSLEY.

To found a work on Morbid Anatomy, except upon some special plan, is only likely to result in the formation of a catalogue of anatomical changes, and not a scientific exposition of the causes that have led to such changes, and yet it is the causation of disease which we hope to elucidate by a study of the structural metamorphoses produced by the diseased processes. In the teaching of Morbid Anatomy at University College, this has always been kept in view, but certainly it has been reserved for Mr. Boyce to bring together the facts of Anatomy in such a way as to present the most modern views of the origin and action of the causes of disease.

The subject essentially demands that it shall be treated both from a general and a special point of view. It is impossible for instance to deal with the common appearance of conditions like inflammation in special parts of the body without a previous survey of the process so far as its stages are successively brought out, and clearly dependent upon the action of some well-known cause. In the plan of this work, therefore, the subject of

Inflammation is first discussed in the fullest manner, and as an example of the general plan the Lung has been taken as a tissue, which happens conveniently to present very obviously a view of the changes in the vessels and perivascular tissues, while at the same time in the alveolar cavities the various forms of inflammatory exudate are collected and can be critically examined.

Looking upon the Inflammatory Process as the outcome of something which has reacted injuriously upon the tissue it is clear that the next most fitting subject to discuss is that of Repair, and more especially since in chronic inflammation the two things, destruction and recuperation, may be seen side by side. Built upon this subject, viz., Repair after inflammation, is the most practical one of Repair of Wounds and Solutions of Continuity; and inasmuch as these conditions, as well as the inflammatory state result in destructive degenerative alteration, the great question of Degeneration in all its forms constitutes the next point in the development of the subject. The anatomical study of Degeneration involves the concomitant examination of other conditions which, though not called Degenerations, are so closely allied as to signify a similar origin from imperfect nutrition of tissues, and therefore it certainly will be conceded that all forms of Trophic

disturbance are most properly aggregated under the head of Degeneration.

We are thus brought up to such pathological states as include the combined action of Inflammation and Degeneration, and such are of course the infective processes. Mr. Boyce's work in no sense is imagined by him to do more than demonstrate the groundwork of the changes effected by the activity of micro-organisms. But it will, I think, be fully admitted that in designing the sketch in Chapter VII. of the most important diseases proceeding from the most simple in which we have the direct action of the organism evidenced by the production of acute inflammations to the chronic infective processes which lead to the formation of Granulomata, a perfectly natural sequence has been observed. Without going afield to discover the relation which the elder pathologists were always looking for between Inflammations and Neoplasms, the diseases Tuberculosis and Syphilis very conveniently illustrate the severest forms of the infective granulomata. In developing this view of these conditions Mr. Boyce has dexterously employed as an introductory demonstration the lesions which are set up by a relatively coarse parasite, and then is able to develop in a striking manner the origin and evolution of the conditions just alluded to, which are of such immense

practical importance. Leaving the now well understood infective granulomata, the next question to be discussed is the subject of Neoplasms, which, connected as it is, in its most developed condition with the obvious existence of the process of infection on the one hand, and the formation of new tissue on the other, constitutes an immense field for conjecture and research. Most difficult is it at the present time, when the causation of Neoplasms is yet so obscure and indeterminate for anyone to put forward any division of Tumours, except I think that which Mr. Boyce has wisely determined upon, namely, to take the tumour-like hyperplasias of the more highly specialised tissues on the one hand, and of the simple tissue of the framework of the body on the other; to regard these as connected first more specially with chronic inflammatory states as the precursory condition, and only after a thorough examination of these in the minutest detail, proceeding later to discuss the malignant forms of the preceding simple groups, thus drawing a distinction in Anatomy between the simple Hyperplasias due to no special cause so far as is known at the present time, and conditions like those of Sarcoma and Carcinoma in which there is unquestionably some condition at work which leads to multiplication and reduplication, and which is commonly termed malignant. I would

specially draw attention to the original division of Neoplasms which Mr. Boyce has developed in Chapter XVIII. on morphological lines into forms of congenital origin, *i.e.*, anterior to obvious differentiation, and on the other hand forms in which some exciting cause has evoked the neoplasm from the developed tissue. In dealing with intermediate forms of tumours a fresh difficulty arises when we consider the heterogeneous mass of conditions which are customarily grouped under the head of Cysts. For anyone to neglect to classify Cysts, according to the manner in which they may have been supposed to have been brought about, *i.e.*, by retention, &c., is to embark upon a course not unlikely to be provocative of unfavourable criticism, but it really is impossible to attempt to deal with the various conditions that are grouped under the term of Cystic formation, unless we place them together in the regions of the body where they are found, and forbear from assuming unwarrantably that we can dogmatically attribute their existence to any definite cause. Mr. Boyce has therefore, I think, judiciously contented himself with placing the Cysts in a very practical order, namely, according to the particular system of the body in which they happen to have been developed; besides, too, no undue importance has been given in this work to the question of the formation of Cysts, the enumeration indeed of the principal features

of their structure being all that is really required in a work on Morbid Anatomy where clinical considerations are out of place. With the discussion of congenital formations which is so very naturally appended to the description of Cysts, as the last class of morbid new developments, the student is taken from general to special points. Suggestions as to the best way in which specific changes are observable in the organs of the body are to be found in every work on this subject, but I do not think that we can obtain a clearer presentation to our minds of such changes by any other scheme than the successive examination of the individual systems of the body as they are arranged in works on Normal Anatomy. Hence it will be found that the Vascular System is first treated, then the Adenoid structures, and so we come to the skeletal elements, following upon which are arranged the various organs, terminating finally with the Nervous system; in each case the discussions of the specific changes in any given system are grouped together, and stress is laid upon them, according to so-called practical requirements, that is to say, in a work which does not pretend to be exhaustive, the commoner morbid processes such as are met with every day in clinical work of necessity receive fuller consideration than rarer conditions, unless indeed these latter possess the inestim-

able advantage of revealing some truth of fundamental value and importance in elucidating the means whereby a morbid state has been brought about. To effect this critical arrangement and to make a judicious employment of exceptional cases constitutes a difficulty of almost insuperable nature, but so far as such a result can be obtained it is, I believe, to be found in the following pages. I cannot deal in such a general survey with the extent of Mr. Boyce's work, nor have I been able to effect more than a mere sketch of the general plan which should constitute as we think the teaching of Morbid Anatomy. I cannot bring even this short outline to a close without dwelling upon the fact that although for the experienced student and original investigator the pictorial representations of disease are comprehensible and admittedly accurate, yet nevertheless to anyone commencing the subject diagrammatic and even careful artistic rendering of microscopic objects lack what is indispensable, namely, the natural appearance of the structure under examination. It was always my object to obtain this by photography, but until Mr. Boyce most kindly took the matter up and placed it on a proper footing, nothing in the way of the general extension of this method could be dreamt of. It was therefore with great satisfaction to myself when I understood from him that he

would publish not only the general results of his most extensive knowledge, both practical and literary, of this subject, but that he would illustrate his ideas by reproduction of his photographs. The happy combination of literary research and of the very intimate knowledge of the anatomical changes of disease which he possesses, has under the circumstances produced, I think, a work which cannot fail to be of much service to the student, whether at home or in the laboratory, and of helpful suggestiveness to the original investigator.

BOSTON MEDICAL LIBRARY
SEP 22 1904

MORBID HISTOLOGY.

Chapter I.

PRACTICAL DIRECTIONS.

1. **The Microscope.**—The following are recommended, namely :—

Objectives.—1 in., $\frac{1}{4}$ in., and $\frac{1}{12}$ in. oil immersion, or $\frac{1}{2}$ in., $\frac{1}{6}$ in., and $\frac{1}{12}$ in. oil immersion.

Two Eyepieces.

A good *substage condenser* with *iris diaphragm.*

Rack and pinion coarse adjustment in addition to the fine.

A *nose piece.*

2. **Hardening.**—Methylated spirit, absolute alcohol or ammonium dichromate (or pot. dichromate) will harden most satisfactorily any morbid specimen.

(*a*) *Methylated spirit.*—It should not be used diluted, nor sparingly. It hardens rapidly, and very good sections, sufficient for diagnostic purposes, may be made from small pieces of tissue which have lain in it for as short a time as 12 hours ; it is usual, however, to allow a week, and after that the tissue may be kept in it until required.

(*b*) *Absolute alcohol.*—This is still better, since it fixes and hardens more rapidly, and should therefore especially be used for fresh tissues. A small mass may be cut after two or three hours immersion ; but as before give a much longer time when possible.

Methylated spirit is sometimes treated in one of the following ways* in order to render it absolute—by calcined cupric sulphate, dry potassic carbonate, strips of gelatine, and by *quicklime and distilling*.

Spirit should be used for micro-organisms and spreading gangrene, and lardaceous degenerations. Do not use it for nerve tissue, nor where osmic acid will be subsequently employed to stain.

(*c*) *Ammonium dichromate* as a two per cent. solution is a hardening reagent which is displacing the other chromic salts, including Muller's fluid. It is extremely good and is better than alcohol in a very great number of cases, only it takes three or four weeks to do its work thoroughly, and longer if the tissue is very bulky; but by cutting up a piece into slices just thick enough for a few sections, the hardening may be accomplished in two or three days, or as soon in fact as it feels firm; with the same object in view, the solution may be increased to four per cent.

The dichromate should always be used in large excess, and be changed several times in the first two or three weeks. When sufficiently hardened, tissues should be stored after washing, in methylated spirit; or better still when frozen sections are to be made, in a solution of gum kept pure by thymol or camphor.

It is very essential that nerve tissue be not kept in it too long, as it gets exceedingly brittle and discoloured, it should therefore be transferred to gum, or to alcohol if

* Mr. Gerrard has reminded us of the old plan of suspending spirit in a bladder—the water diffuses out to the surface and evaporates, the alcohol remaining. We have tested this in the case of methylated spirit, but found the specific gravity increased 10°, instead of having decreased.

collodion or paraffin preparations are to be made. Some at the outset add gum or glycerine to the hardening fluid.

Ammonium dichromate is exceedingly good for almost any tissue, especially so for nerves and for preserving the colour of the blood corpuscles in the vessels, or where osmic staining will be used; it should also be employed where colloid matter is present, and it is perhaps the best hardening fluid for all tumours.

(*d*) *Other Hardening reagents.*—These include, perchloride of mercury which fixes rapidly; *Muller's fluid* which consists of

Potassic dichromate . . .	2 parts
Sodic sulphate	1 part
Water	100 parts,

and is commonly used with the addition of one-third alcohol; chromic acid, and zinc chloride.

*Osmic acid** is a special fixing and hardening fluid and is used in two ways, as a *half per cent. solution* and in the form of *vapour* from a one per cent. solution. It has the property of *staining* tissues generally a light brown, and fat and myelin especially a *black*. The *vapour* is a very rapid fixer, entailing the least disturbance of the object, which is hung up in it or spread out on a cork or cover slip and inverted over the mouth of the bottle. The brown colouration of the tissue indicates when it has been sufficiently acted upon, which is from a few minutes to several hours (Lee).

The *solution* may be employed to fix and harden fresh tissue, and is more especially useful for this purpose in

* It is usually kept in the dark, as also when hardening and staining.

the case of small nerves. But is wasted on post-mortem specimens, for which it is much better to use ammonium bichromate and then to stain the sections, if necessary, in the half per cent. solution, which is accomplished in from a few minutes to several hours.

3. **Decalcifying.**—First harden thoroughly in the usual way, then proceed to soften the bone or calcified tissue with the following solution :—

Hydrochloric acid	3 c.c.
Sodium chloride	10 grm.
Methylated spirit	30 c.c.
Water	70 c.c.

The smaller the pieces of bone, the sooner the decalcification, hence when possible saw into slices the $\frac{1}{8}$ or $\frac{1}{6}$ in. in thickness and suspend in the fluid. Trial should be made from day to day to ascertain when the bone is sufficiently soft; as soon as it so, transfer and keep in plenty of strong alcohol. It is exceedingly difficult to cut decalcified bone in gum, and collodion or paraffin must be used.

4. **Cutting.**—(*a*) The *Microtomes*.—There are several of these made, of which the Cathcart, Swift and "Rocking" are well known; the first two can be used for gum, collodion and paraffin; whilst the Rocking is a special and very good apparatus for wax and for cutting ribbons of sections.

The *Cathcart* is cheap, simple and efficacious. The knife, as recommended by Délapine, is an ordinary good and well sharpened *plane iron* and is passed rapidly forwards and backwards on the glass runners, by movements of the right hand, whilst with the left, the tissue is elevated by a screw at an equally rapid rate. It cuts quickly and finely, and but very little practice is

required to manipulate the iron and to hold it at the right level, and finally to keep it sharp.

The *Swift*.—This is a very simple instrument, and can be employed with facility, but it is expensive. It is a favourite amongst section cutters.

(*b*) *Preparation and imbedding*.—There are three principal methods of imbedding.

1. Gum.
2. Paraffin.
3. Collodion or celloidin.

Not more tissue than is absolutely necessary should be prepared, as large masses cause delay—$\frac{1}{8}$ to $\frac{1}{12}$ of an inch will be found of sufficient thickness.

By gum.—If the tissue has been in alcohol, thoroughly remove it by steeping in luke-warm water for half an hour.

Then soak in gum, fairly thick, clean and clear, and to which some thymol, menthol, or camphor has been added. Allow the tissue to remain in it if possible for several hours, or indefinitely until wanted. When in a great hurry the gum is merely used to fix the piece to the carrier of the microtome.

Have ready a black photographic tray, filled with warm water, to receive the sections.

A camels hair brush to lift the sections off the knife.

Place the piece with some gum on the carrier and freeze carefully and gradually, until it is solid like cheese, but not hard nor crisp. Adjust the knife and remove a thick top slice, and then proceed to cut as thin sections as possible; remove them with the brush, or in the case of the "iron" plunge into the water. The knife must not be wet, and its edge must be perfectly

keen as small teeth cause furrows. A stone and strop should always be at hand.

Leave the sections in the water for about half an hour to get rid of the gum, then stain.

The above process is very generally applicable, but is of no use for frail and brittle objects. Tissues containing micro-organisms should be prepared in paraffin.

By paraffin.—Only a small block of tissue should be cut.

Thoroughly *dehydrate* in absolute alcohol. Then *clear* by immersion in spirits of turpentine or cedar wood oil, until the block is rendered semi-transparent. Transfer to plenty of paraffin melting at 45° and kept just melted in a regulated oven—or manipulate in a watch glass, renewing the paraffin once or twice in the course of an hour. Keep in the melted wax for an hour or longer.

When ready pour the block with a little paraffin on to a glass or smooth metallic surface, and it will set in a very few minutes.

Remove, and having warmed the carrier of the microtome sufficiently to just melt the wax, allow the block to adhere firmly, and when cold, cut. Hold the knife as horizontally as possible.

When the sections are made there are two methods of procedure. *Firstly*, when there is no fear of them falling to pieces, remove the wax by allowing them to soak for a few minutes in xylol; then steep in absolute alcohol for an hour if possible; then transfer to methylated spirit, and the sections are ready to stain. *Secondly*, when they are brittle and may fall to pieces, have ready the following solution:—

Egg albumen and glycerine, equal parts.

One per cent. salicylate of soda, or crystal of thymol. Filter.

With this paint a cover slip, and unroll and flatten a section upon it by means of a brush and light touches with the finger. Hold the slip between the fingers and warm over a flame to just melt the wax; the heat coagulates the albumen and the section is firmly bound to the glass, and must next be treated with xylol and alcohol as above, and then stained. (Small glass troughs grooved on each side are made to take the cover-slips and the reagent).

By collodion or *celloidin*.—The collodion of the B.P. does instead of the celloidin.

Much larger blocks can be cut. Thoroughly dehydrate in absolute alcohol. Place in ether for about a quarter of an hour. Then soak in collodion for 12 hours allowing a slight evaporation, so that the solution concentrates. Make a mould by wrapping a little blotting paper round the top of a cork and fixing it with a pin. Pour the block of tissue and some collodion into it, and expose to the air for a few minutes in order that a film may form on the surface. Then immerse in methylated chloroform, which in the course of an hour or two will bring the collodion to a beautiful firm white of egg like mass. When ready remove the blotting paper, and fit the cork into a clamp which is made for this special purpose in connection with the Cathcart machine; or cut away a thin strip of cork with the collodion adherent to it, then dry and freeze it with gum to the carrier; or wash and then steep in gum and freeze.

When cutting, hold the knife as horizontally as possible, and draw it across the section obliquely and

from heel to point,* at the same time keeping it and the preparation well wetted with *methylated spirit*, except of course in the case of the frozen sections.

As they are cut transfer the sections to methylated spirit, not absolute which dissolves the collodion. Stain with logwood and subsequently pass through very dilute acetic acid to remove the stain from the collodion.

Mount in glycerine, or pass through methylated spirit and mount in spirit varnish; or after thorough soaking in spirit, clear in cedar oil, which takes some time, or *on the slide* with clove oil, mount in Canada balsam.

5. **Staining.**—(*a*) *In mass.*—In the foregoing pages it was directed to stain after the sections were cut, and this is still to be preferred; but since the method of staining in bulk is adopted by a great number, we give it here.

Procure or make Grenacher's *borax carmine.*

Carmine (the best) . . .	2 grm.
Borax	4 grm.
Aqua dest.	100 c.c.

To this add an equal volume of 70 per cent. *alcohol*, and allow to stand for a week or two, then filter.

Put the tissue, which must be free from any trace of acid, into the stain for 24 hours or longer, until it is thoroughly penetrated. There is no risk of over-staining.

Transfer directly to spirit acidulated with hydrochloric acid, in the proportion of 4 drops to 100 c.c., and leave for 3 hours or longer.

* In the Cathcart a long razor blade or section knife ought to be used instead of the plane iron.

Wash in methylated spirit; finally dehydrate in absolute, and it is ready for collodion or paraffin; it may also be cut in gum.

(*b*) *Sections.*—The sections, or the cover slips bearing the sections (as in the paraffin method), are transferred from water or methylated spirit, as the case may be, into one of the following stains:—

(1) The *logwood* and *hæmatoxylin* group.—These are of the greatest service. The nuclei are stained deeply, the protoplasm slightly, and the cell structures are differentiated. By using them very weak or concentrated, or by treating over-stained sections with dilute acetic acid, various degrees of contrast may be obtained. In combination with eosin still more beautiful colour effects are produced.

Gerrard's logwood.—The following formula of Mr. Gerrard, of University College Hospital, has been found most useful:—

Clean logwood chips	8 ozs.
Ammonia alum free from iron . . .	2 ozs.
Spirits of wine	1 oz.
Water	1 pint.

Dissolve alum in water, add logwood infused 24 hours, strain, add spirit.

The stain may be used diluted with distilled or tap water (there is no precipitate), and the sections may be allowed to soak in it for several hours, a proceeding which gives good differential effects; or the sections may be rapidly stained in the strong solution; or they may be over-stained, and then treated with weak acetic acid, which partly removes the logwood from the non-cellular parts. After this proceeding carefully remove all trace of acid by washing.

Slightly different shades of blue and red are obtained according as distilled or common water is used.

After staining, allow it to remain some time in water, which imparts a deeper tint to the sections.

Attention to the above points will give a variety of different effects. Thus, for instance, caseous material may be made to take up very little colouring matter or to stain intensely.

Ehrlich's hæmatoxylin.—This is very good and produces different results according to how it is manipulated. For instance, the growing cartilage in normal or rickety bone will stain almost black after a few hours soaking in a very weak solution, whilst in a strong solution a much more diffuse result is obtained. Dilute with distilled water where necessary. Wash in common water to bring out the deep blue colour.

Note.—Collodion sections stain rapidly with this group. It is as well to remove the stain from the collodion by weak acetic. Paraffin sections stain slowly. Sections can be mounted in any of the media but balsam is the most useful. These stains improve on keeping but protect the sections from the light.

Hæmatoxylin and *eosin.*—Stain as before, wash and transfer to a watch glass of methylated spirit, to which one drop of a strong solution of eosin or common red ink has been added, and leave it there two or three minutes or even longer. Then pass *directly* through cloves and mount in Canada balsam. The nuclei remain stained with logwood, but the eosin seems to displace the blue colour from the protoplasm, fibroid and necrotic structures, imparting to them a marked pink colour. With the coloured corpuscles it gives an important redish reaction, which contrasts with their previous almost invisible condition.

2. *Osmic acid.*—Place the sections in a half per cent. solution, protected from evaporation and light, until they have acquired the desired tint. *Fat* and *myelin* are stained black, hence it is very good and useful for all cases of fatty change, and by contrast for sclerosis of the cord and nerve degenerations, the fibres only becoming black.

3. *Carmine.*—In addition to staining in mass, it gives good results with sections of the spinal cord, bringing out sclerosed patches. Use as directed for staining in mass.

4. *Picrocarmine.*—With some this takes the place of the logwood group. It yields good double staining effects. Lift the section from water on to the slide and pour over it a few drops of the solution, in a minute or so run only the excess off and mount directly in glycerine.

5. *The aniline group.*—Saturated solutions are made with water or alcohol.

They are all readily extracted by alcohol, and this fact is made use of in staining. Thus, the sections are over-stained and then treated with spirit, or spirit just acidulated with hydrochloric acid until the proper staining effect is obtained. They are then rapidly passed through cloves and mounted in balsam. They must not tarry in the oil of cloves as it likewise extracts the dye. To obviate this, cedar oil is sometimes employed.

Methyl violet.—This is especially useful for *lardaceous degenerations* and *fat*, to the former of which it imparts a pink, and to the latter a deep violet colour.

It is perhaps best to use a dilute watery solution (a drop or two of purple ink will do), and to stain for some time. In the case of waxy degeneration, subsequent treatment with half per cent. acetic acid heightens the

contrast between the blue of the unaffected, and the pink of the affected portion. But always remove every trace of acid and mount in glycerine.

Aniline blue black is used extensively for the central nervous system, especially to reveal degenerations.

Employ a weak solution and stain for several hours. Any chromic salt should be thoroughly removed by washing, and the fresher the cords the better. The black inks are used by some.

Methyl blue.—This should be reserved for sections of fresh unhardened tissue, and glycerine is then used for mounting.

Gentian violet, *fuchsine*, and *safranine* are other useful aniline dyes. Gentian violet and fuchsine are especially serviceable for micro-parasites.

(*c*) **Especially for micro-organisms.**—In logwood prepared tissues, micro-organisms may be recognised when they occur in masses, as they stain more deeply than their surroundings; but when they are scattered, it is quite impossible to do so owing to the complex nature of the field. The same may be said when the carmines are used. But the *aniline dyes* have a special affinity for vegetable and even some animal parasites, and when sections of tissues in which they are present have been well over-stained, and have then passed through a solution of iodine or of strong acid, such as sulphuric or nitric, the colour may be further removed by spirit from everything but the organisms, whilst with a second or *contrast stain*, the structure of the tissue may be revealed, without in any way interfering with the visibility of the parasites.

A great many anilines are used, of which gentian violet and fuchsine are perhaps the commonest; the

contrast colours being eosin for the violet and methyl blue or Ehrlich's logwood for fuchsine; but there are numerous other combinations.*

Gentian violet.—One of the best solutions is that of Ehrlich's.

Saturated solution of gentian violet—

Gentian violet	1 grm.
Alcohol	15 c.c.

Saturated solution of aniline oil—

Aniline oil	3 c.c.
Aqua dest.	80 c.c.

Mix and filter.

Stain from a few minutes to a half hour or longer, then transfer to *Gram's solution of iodine*, prepared thus:—

Iodine	1 grm.
Pot. Iod.	2 grm.
Water	300 c.c.

Allow a minute or so for this, the preparations meanwhile turn brown.†

Then wash the sections in methylated spirit until they are almost white, and counterstain with watery (or alcoholic) solutions of *eosin*, *bismarck brown*, or *safranine*.

Dehydrate rapidly, pass through cloves and mount in balsam.

* There are special staining methods for nearly all the organisms of importance.

† This operation aids in fixing the stain in the organisms, and facilitates the next process, that of the decoloration of the tissue elements by alcohol, or if necessary, by cloves in addition.

Fuchsine.—Zeihl-Neelsen's formula. Carbolic acid is used instead of aniline oil.

Fuchsine	1 grm.
Alcohol	10 c.c.
Carbolic acid	5 grm.
Water	100 c.c.

This is a most useful stain for Tubercle, Leprosy and Actinomycosis. In the case of the first, cover-slip preparations require about half an hour's immersion in the warmed solution, and sections of tissues a very much longer time, often days.

Preparations of Tubercle must pass through a 10 to 25 per cent. solution of sulphuric acid, or nitric acid 1 in 3, whilst Actinomycosis is usually treated with Gram's iodine.

Complete the decolorisation in spirit, and stain with a contrast colour such as methyl blue or Ehrlich's log-wood. Mount as before.

(*d*) *Especially for nerve tissues.—Weigert's method.*—The tissue should be hardened in potassium dichromate or Müller's fluid, or if previously hardened in alcohol must be allowed to acquire a brown tint by immersion in the dichromate.

As soon as it is ready it is placed in gum, and sections made; or it is dehydrated and soaked in collodion and kept in mass for the next stage, when the sections or the collodion blocks are transferred for a day or two to a half saturated solution of acetate of copper, kept at a temperature of about 38° C. After this the collodion mass may be cut.

The sections are next allowed to stain from two to several hours (cortex) in the following *hæmatoxylin solution of Weigert*, which is kept warm.

Hæmatoxylin . . . . . 1 part
Alcohol . . . . . 10 parts
Water . . . . . 90 parts
Lithium carbonate (saturated solution) 1 part

When they have acquired a sufficiently black colour wash in water and treat them with—

Potassium ferricyanide . . . 2·5 grm.
Borax . . . . . 2 grm.
Water . . . . . 200 c.c.,

which produces in about half an hour or longer a differentiation between the grey matter or sclerosed parts and the medullary fibres, the former assuming a *light brown*, the latter retaining a fine *blue black* colour.

Finally wash and mount in the usual way in balsam.*

Pal and Weigert's method.—Dilute an equal quantity of the hæmatoxylin with distilled water in a watch glass, and add a drop or two of lithium carbonate. Place the sections in this solution for several hours or until they assume a very dark tint.

Wash in distilled water and subject for half a minute to a 25 per cent. solution of potassium permanganate.

Wash and transfer to the decolorising and differentiating solution :—

Potassium sulphite . . . . 1 grm.
Oxalic acid . . . . . 1 „
Distilled water . . . . 200 c.c.

until good contrast effects are produced, which is generally in two or three minutes. Eosin can be used with advantage to get still stronger contrasts.

6. **Mounting.**—*The media.*—Glycerine, glycerine jelly,

* This method often gives a beautiful black reaction with red corpuscles.

Canada balsam, and occasionally spirit varnish, are the common mounting media.

Canada balsam is made of equal parts of dry balsam and xylol, and the following is the method to be adopted for mounting in it.

Stain the sections, whether they are free, or in collodion or fixed to the cover-glass. Wash in water.

Transfer, on a section lifter if necessary, to spirit, in order to dehydrate thoroughly. See that they do not become crumpled up in this process.

With a needle or section lifter, transfer to cloves, if a section was previously folded it now usually unrolls.

Immerse a well polished lifter into the cloves and draw the section on to it, undoing any folds. Lift up with plenty of oil and flow the section on to a slide. Allow what will of the cloves to drain off and remove the rest and at the same time *flatten the section* by the following means:—hold a small piece of white filter paper on the slide with the left hand, then press it firmly on the section by a sweeping movement of one of the fingers of the right hand. There is no fear of bringing away the section on the paper if it is held firmly.

Place a drop of Canada balsam on the cover-slip and invert over. If there are any air bubbles these are absorbed.

Shield from the light, as most colours fade.

Note.—Collodion preparations if to be clarified by cloves, must be cleared on the slide, as the collodion is almost instantly dissolved. Cedar oil takes a very long time to clear. Or the sections may be transferred directly from spirit to spirit varnish, or mounted in glycerine or glycerine jelly.

In the paraffin method, sections if stained may be transferred directly from the xylol to balsam.

Glycerine and glycerine jelly.—Immerse the *slide* beneath the (stained) section in water, float on to it and lift out. Run off the excess of water, place a drop of glycerine upon the section and cover over with a slip.

In using jelly, place a piece about the size of half a split pea upon the cover-slip and very gently warm till it melts, then invert over the section.

In both cases, cement the edges with gold size, asphalte, or other substance.

Bubbles are often a source of great trouble. To get rid of them before mounting, transfer the sections from the water into spirit for a moment, and shake, then put back into water and mount.

Cover-slip Preparations.—For sputum, blood, pus, exudates, cultures, &c.

Smear a small quantity on a perfectly clean cover-slip, with or without diluting with a drop of pure water, or spirit, and spread it all over by rubbing it with another cover-slip, thus at the same time making two preparations.

Allow to dry. Then fix by rapidly passing through a Bunsen flame, to coagulate the albumins and to produce a certain amount of transparency (*see* Note, p. 19).

Stain in a watch glass containing the selected aniline dye. For tubercle bacilli use Neelsen's fuchsine, and warm; leave the slips in it for half an hour or longer.

Treat with Gram's iodine, or in the case of tubercle with the sulphuric or nitric acid mixture. Decolorize with spirit; and use a contrast stain if necessary.

Dry and mount in xylol balsam; or melt a piece of

the dry balsam on the slide and press the cover-slip firmly down upon it.

Cutting Fresh Tissues.—For purposes of diagnosis.

Place on the carrier of the freezing microtome with plenty of gum, freeze and cut a few sections. Transfer them to water, and float them on to slides.

Pour over a few drops of methylene blue, and when sufficiently stained drain off and cover with glycerine.

7. Injecting.—Carmine and Prussian blue are the commonest colours.

Carmine—

(*a*) Carmine 3 grms. rubbed up with a little water and enough ammonia to dissolve it.
Glycerine . . . . . 50 c.c.
Filter.

(*b*) Glycerine . . . . . 50 c.c.
Acetic acid . . . . . 5 c.c.

Add (*a*) to (*b*) and see that the resulting mixture is just acid.

For use.—Add one part to four of a *glycerine* or *gelatine* vehicle, such as—

(1) Glycerine . . . . . 2 parts.
Alcohol . . . . . 1 part.
Water . . . . . 1 part.

(2) Gelatine . . . . . 1 part.
Water . . . . . 10 parts.
Dissolved and kept warm.

Prussian blue—

Soluble Prussian blue . . . . . 5 parts.
Water . . . . . 60 parts.

For use.—Add in the same proportions as above to the glycerine and gelatine mixtures. Acidulate just before using.

For injecting use a syringe and fine cannula or a pressure bottle. There is no trouble with the glycerine solution, but the gelatine requires to be kept warm; therefore all the utensils must be warmed, and if possible, the tissue to be injected.

NOTE.—*Fixing and staining nuclear changes.*—One of the best fixing reagents for this purpose is the chromo-aceto-osmic acid solution of Flemming. As recommended by Lee it is well to keep a stock solution of two per cent. osmic acid in one per cent. chromic acid; this will serve not only for making the following solution but for all the purposes of osmic acid; it should be preserved in a *lead free glass* bottle. For Flemming's solution mix one part of the above with four parts of the following:—

1 per cent. chromic acid	11 parts.
Aq. dest.	4 ,,
Glacial acetic acid	1 part.

Harden a small piece of the tissue in this for about 24 hours, well wash, and then continue hardening in alcohol for a day or longer. *Stain* in a concentrated alcoholic solution of *safranin* for half an hour or longer, wash out in pure alcohol then clear in cloves and mount.

Fixing and staining micro-organisms.—Instead of the heat method for fixing cover-slip preparations, a drop of a solution of equal parts alcohol and ether may be used. As some organisms are decolorised by Gram's iodine, they should after staining be simply washed in water or alcohol. The most serviceable stains are Ehrlich's gentian violet, Fuchsine, Löffler's or Kühnes' blue.

The following method, of *paraffin* embedding and *double staining with picro-carmine and gentian violet*, will be found useful. To embed:—Transfer the piece of tissue from absolute alcohol to ether, then to a saturated solution of paraffin in ether, then to the melted paraffin. Allow several hours for each process. When the sections are cut, remove the paraffin by successive washings in ether; transfer to alcohol and ether, then to alcohol alone, and proceed to stain. First stain from half to one minute in Orth's carmine, then well wash out all excess with the following solution—alcohol 70 per cent., saturated watery solution of picric acid 30 per cent., and HCl half per cent. The nuclei remain deeply stained. Next proceed to stain with *picric acid*, allowing as long a time as possible in order to colour the protoplasm, &c. Wash in water and stain micro-organism, if present, with the gentian violet, pass through Gram's iodine, wash, just dehydrate with alcohol and quickly decolorise with oil of cloves, then wash in xylol and mount in xylol balsam. Instead of gentian violet, Löffler's blue may be used (longer to stain); in this case wash out in water, rapidly dehydrate and decolorise in aniline oil, then to xylol, &c.

Chapter II.

ACUTE INFLAMMATION.

I. The outlines of inflammation, including the retrogressive tissue changes and the vascular phenomena. The reparative or progressive changes and the chronic inflammatory conditions.

II. Illustrations of the retrogressive and vascular phenomena as seen in *acute inflammation* of the

1. Lung—
   - (*a*) Congestion and œdema (serous exudate).
   - (*b*) The fibrinous exudate.
   - (*c*) The leucocytic exudate.
   - (*d*) The hæmorrhagic exudate.

2. Serous Surfaces—
   - (*a*) Serous pleurisy.
   - (*b*) Sero-fibrinous pericarditis.
   - (*c*) Suppurative peritonitis.

3. Mucous Surfaces—
   - (*a*) Bronchitis—congestion stage.
   - (*b*) Bronchitis—leucocytic exudation.
   - (*c*) Croupous and diphtheritic inflammation of the intestine.
   - (*d*) Diphtheritic inflammation of the mucous membrane of the pharynx.

4. Parenchymatous Organs. *Ex.* The Kidney.
   The vascular and parenchymatous changes.

5. Connective Tissue and Skin—
   - (*a*) Leucocytic exudation.
   - (*b*) Pus, suppuration and the acute abscess.
   - (*c*) Gangrenous inflammation. The formation of the slough, vesicle and pustule.

Introductory.

We cannot attempt in the following pages to give more than a sketch of the tissue changes observed in such a wide and definitionless a subject as *Inflammation*. In almost every chapter examples of inflammation of some form or another will be discussed, striking illustrations being furnished by the mycotic and zooparasitical affections.

In studying the tissue changes which are grouped under inflammation and which are the outcome of many different causes, we will be struck by the varying degrees of prominence which the following phenomena assume under different circumstances, viz. :—

1. The *vascular phenomena*—engorgement, exudation, stasis.

2. The *leucocytic massing*.

3. The evident *injury of the tissue* as shown by the swelling, vacuolation and subsequent necrosis of the cells, the softening of the ground substance and the dilatation and permeability of the vessels.

4. The *proliferation of the tissue elements*.

The various interpretations which have been put upon these phenomena will be found partly detailed in the Bibliography. For in the present and subsequent two chapters we will confine ourselves to a grouping (*artificial though it be*) of the above changes, such for example as, the acute retrogressive and vascular changes (Chap. II.) the reparative and progressive (Chap. III.) and the more chronic hyperplastic changes (Chap. IV.).

The vascular phenomena, which are especially well-marked in the acute forms of inflammation are :—

1. The *dilatation of the vessels*.

2. The *retardation of the blood stream*.

3. The *exudation of a serum like fluid rich in albuminoids*, which if the injury continue or increase is supplemented by 4, a *coagulable exudate*.

5. The *exudation of white* and *red corpuscles*.

6. *Stasis* and *thrombosis*.

They appear to be due to the softening of the vessel walls (the result of the "injury") and taken in the above order they very often correspond to increasing degrees of injury. The tone of the walls of the vessels gives out and distension and slowing of the blood stream result; the endothelium no longer possesses a selective influence over the serous fluid which normally transudes, but allows one highly charged with albumin to filter through in increased quantity; and what is still more remarkable permits the escape of leucocytes and red corpuscles, though no actual channels can be demonstrated.

If the injury is only slight engorgement is the chief result; if very severe hæmorrhagic exudation and ultimately stasis and thrombosis; but in many cases apparently, more dependent upon the NATURE of the injury than upon its intensity, is the phenomenon of leucocytic massing or exudation.

Supposing the irritation to cease relatively early, *repair* takes place, and the necrosed elements are removed and replaced by new tissue. Of the exudates, the fluid constituents—the source of the swelling—are rapidly removed by the lymphatics; whilst the deposits of fibrin and red corpuscles take a much longer time to disappear; but what becomes of the leucocytes is less certain. Whether like the red corpuscles they are removed before healing is complete, or whether they

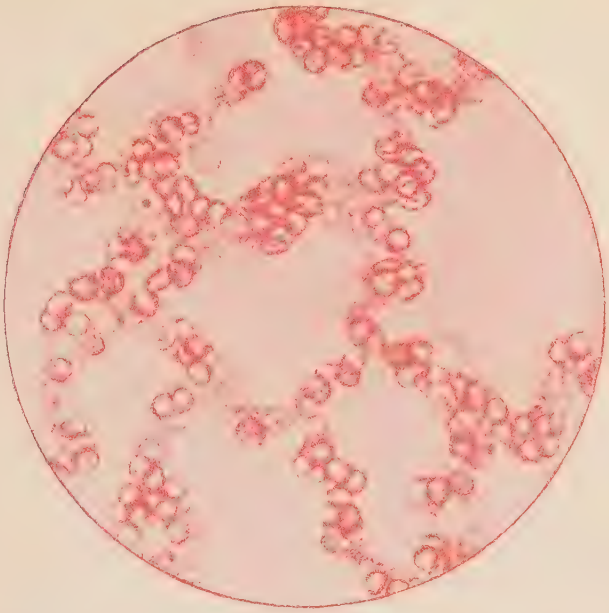

Fig. 1. STAGE OF CONGESTION IN THE LUNG

The capillaries of the alveolar walls are distended with red corpuscles.
Obj. $\frac{1}{12}$ without eyepiece.

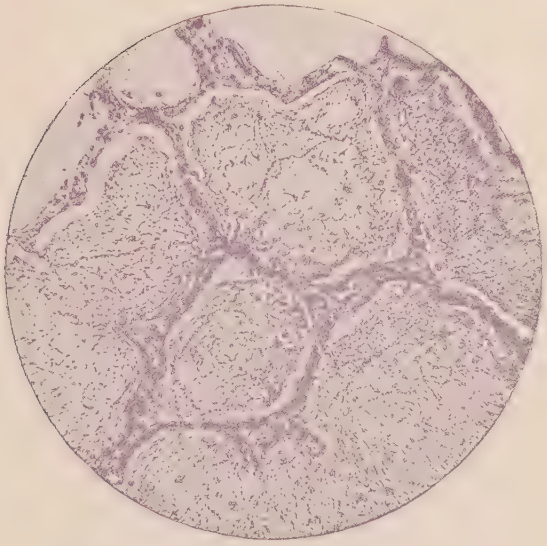

Fig. 2. LUNG. CROUPOUS PNEUMONIA

Stage of fibrinous exudation. The alveoli being filled with a fibrinous meshwork.
Obj. $\frac{1}{4}$ without eyepiece.

take an active part in the formation of new connective tissue has long been debated. The inflammation producing irritant kills many of them, just as it does the tissue corpuscles, and as pus cells we are familiar with their consequently degenerated forms. Those that survive may find their way into the lymphatics, or undergo fatty change, after having perhaps proliferated a few times ; or they may act as scavenger cells. But some still think they are capable of higher development, viz., of forming connective tissue and capillaries ; and granulation tissue is said to contain them in all stages of development.

By those who adopt this view, the *progressive* changes which take place in the escaped corpuscles are spoken of as *productive inflammation ;* and repair is said to be a combination of the *regeneration of the original tissue* and productive inflammation.

The new tissue, whether produced by both these processes or by regeneration only from the original tissue, (the commonly accepted view), is made up of numerous cell forms, round and spindle cells, and often epithelioid and giant cells. There are many newly formed capillaries. An over-production of tissue is very often seen, but in time *contraction* is sure to occur. The delicate vessels are readily affected by the least irritation, and a slight inflammatory exudation is very common and apt to be prolonged over a considerable period. Thus a chronic inflammatory condition supervenes.

II. Illustrations.

To investigate the above changes we will take as examples and illustrations the pulmonary alveoli, serous

and mucous surfaces, a glandular organ, and connective tissue.

I. **Pulmonary Tissue.**—We take the lung first because of the numerous and delicate vessels in the walls of the alveoli which readily reveal early inflammatory changes, and because the air cells form convenient receptacles into which transude the fluid and corpuscular elements characteristic of the advancing stages of exudation. Inflamed or Pneumonic Lung will therefore serve our purposes.

Fig. 1.—This shows the alveolar walls irregular and wavy from the distension of the vessels which are engorged with blood. In the recent state of this specimen the alveoli contained fluid, *œdema fluid* or "*serous*" *exudate*, which had transuded through the pulmonary endothelium from the vessels. It did not coagulate spontaneously, nor was it precipitated by the hardening reagent, hence the alveolar spaces now appear empty.

The injury or irritant which had thus damaged the vessels and brought about these changes, was the prolonged inhalation of ether in a dog. The stages there reached are *congestion* and "*serous*" *exudation*.

The next stage is shown in **Fig. 2.**—A section of part of a pneumonic lung in an adult. The alveolar walls are slightly swollen and the cavities filled with a faintly staining fibrinous material entangling a few corpuscles.

The injury in this case was more profound, and has allowed a coagulable fluid more nearly resembling blood plasma to filter through the capillaries. We may call this, therefore, the stage of "*fibrinous*" *exudation*.

To exhibit the corpuscular exudate, a more advanced specimen of pneumonia, as in **Figs. 3** and **4,** serves very well. Under the low and high power is

Fig. 3. LUNG. CROUPOUS PNEUMONIA.

Stage of leucocytic exudation. The alveoli are widely distended.

1. The exudate in the alveolus.
2. The alveolar wall.

Obj. 1 in., without eyepiece.

Fig. 4. Part of above with Obj. $\frac{1}{6}$, without eyepiece.

1. The exudate consisting of innumerable leucocytes.
2. The alveolar wall, which appears to have been compressed by the exudate.

seen a section of an intensely inflamed portion of a similar lung to the last. It represents one of the most characteristic appearances of acute inflammation, viz., the *exudation of leucocytes*. The alveoli are over-distended by masses of small round cells, held together in a delicate "fibrinous" network. The alveolar walls appear compressed and are either ill-defined or conspicuous as thin red lines of congestion, contrasting with the logwood stained exudate.

Not only, therefore, has fluid escaped from the vessels, but a plasma rich in white corpuscles. The latter had wandered out more especially from the small veins, having first, owing to the sluggish blood stream, accumulated on the inner surface of the vessel walls. A few red ones may have also escaped, but they do not appear in great numbers unless the irritation is still more intense and the congestion very marked. If this is the case, a *hæmorrhagic exudation* takes place from the capillaries, and the alveoli become filled with red blood discs, a condition which was shown in the section from which **Fig. 5** was made; but in the figure the corpuscles are now almost invisible owing to decolorisation. What are, however, most conspicuous, are new elements, corpuscles (1 and 2), very many times larger than the scattered leucocytes around, and which give to the section a distinctive appearance in marked contrast with the former preparations.

The section represents an acute inflammation, of a hæmorrhagic type, *several days after the cessation of the exudation*, and was made from a broncho-pneumonic lung. The large corpuscles are commonly looked upon as derived by proliferation from the alveolar epithelium; and this condition in the lung is spoken of as *catarrhal*

inflammation. Some of them might be epithelial cells which, in the process of degeneration, have fallen from the walls; but as many are furnished with amœba-like processes they were probably *living cells;* and, further, as red corpuscles and particles of soot are seen in their interior, they may be looked upon as *phagocytes* or *scavenger* cells. They are wandering cells of some kind which have become greatly enlarged, for proliferating alveolar epithelium as a rule, gives rise to smaller and more gland-like cells. In the next chapter on Repair we shall return to the origin of these corpuscles.

Summary.—We have now observed the *congestion* or *engorgement* of the capillaries and small vessels, the *exudation of "serous"* then of *coagulable* fluid, the *escape of leucocytes* and of *red corpuscles.* Stages which have been assumed to represent increasing degrees of injury to the vessel walls, produced in the first instance by the contact of a chemical irritant (ether vapour), in the others by the probable presence in the lung of an intensely pathogenic microbe.

In the recent state, *i.e.*, macroscopically, the lung tissue corresponding to Figs. 2, 3, 4 and 5, was solidified or "hepatised." Under these circumstances it is *swollen, very friable* and *inelastic,* and often bears the impress of the ribs. The great distension of the alveoli in **Figs. 3** and **4** shows a diminution of elastic resistance on the part of the walls.

In **Fig. 5** progressive changes may be said to have taken place, the irritation having ceased.

II. The next series of examples are illustrated in **Inflammation of Serous Surfaces.**—Pleura. Pericardium. Peritoneum.

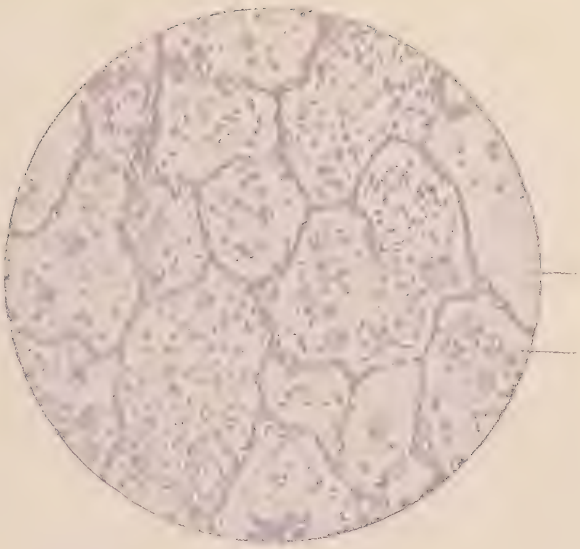

Fig. 5. LUNG. CATARRHAL OR BRONCE

The alveoli are filled with masses of red blood corpuscles, but these are invisible in the figure.

1 & 2. Macrocytes ('catarrhal cells') which give the section its characteristic appearance.

Obj. ¼, without eyepiece.

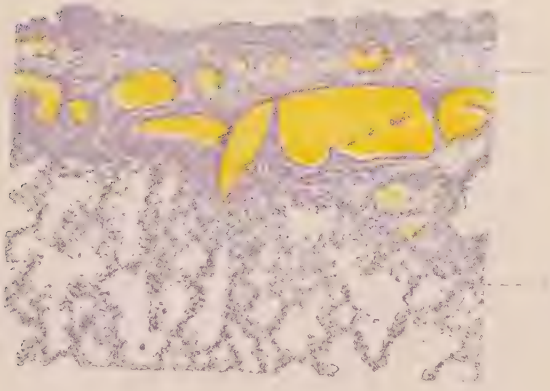

Fig. 6. ACUTE PLEURISY.

1. Superficial roughened layer of the pleura.
2. Deeper layer full of engorged vessels.
3. Œdematous lung structure.

Obj. 1 in., without eyepiece.

Commencing with the pleura, **Fig. 6** shews the pleura from a case of Acute Pleurisy.

The engorged vessels in the deeper layer of the pleura are especially noticeable. The congestion extends into the walls of the neighbouring alveoli, which are swollen and covered with numerous small round cells. The surface of the serous layer is rough, the epithelium having desquamated.

The pleural cavity in this case contained a considerable quantity of "serous" highly albuminous fluid, as also the adjacent alveoli (œdema fluid).

There is, therefore, *congestion* and *exudation of "serum,"* a *slight thickening* of the whole pleura and a roughening of the serous surface, but as yet no formation of fibrin in the exudate.

Fig. 7 exhibits the surface of the heart in acute exudative Pericarditis.

At the lower part of the section are the muscular fibres, above these is seen a layer of areolar tissue, containing abundant fat cells and blood vessels; but it is more corpuscular than normal, especially as it passes into the denser layer of the pericardium, where also a mass of small round cells is seen. From this condition there is an almost imperceptible transition to the structureless sponge work on the surface, which is composed of fibrin with a few entangled leucocytes, and has assumed its present characteristic appearance from the rubbing movements of the heart. There is no longer a layer of serous epithelium to mark the commencement of the exudation, but in its place and in its neighbourhood are numerous corpuscles, of which, though the majority are escaped leucocytes, yet some are proliferating connective tissue and endothelial corpuscles,

and these are beginning to grow outwards as well-defined spindle cells.

The above specimen was taken from a case of acute pericarditis, of five days' duration, occurring in a boy of nine. The pericardium contained turbid fluid and fibrinous flakes of the lymph of older writers, and there was every reason to suppose that the inflammation was caused or aggravated by the presence of pyæmic organisms.

On summing up the condition just observed and comparing it with the specimen of "serous" pleurisy, the inflammation is evidently more intense and has progressed a stage further; for there is abundant *exudation of fibrin* from the pericardial vessels, coagulated into a well-marked layer or *false membrane* on the surface, and floating free as *flakes of so-called "lymph."* In addition there is an abundant *exudation of leucocytes*, (1) in the substance of the pericardium, (2) entangled in the solid exudate and (3) rendering the fluid turbid. Finally, the tissue corpuscles are showing signs of activity by growth and proliferation—phenomena which might lead us to suppose that the injurious influences had ceased and reparation commenced.

As an illustration of Acute Peritonitis shewing leucocytic exudation, *i.e.*, the formation of adhesions and pus **Fig. 8** affords a good instance. It is a preparation of mesentery from a rat which died of localised peritonitis on the third day. Crossing the field is a slightly raised dark band (1) composed of numerous exuded leucocytes, fibrin and granular débris. It conceals a small vessel.

The irritation has led to the exudation of leucocytes and fibrin both in the substance of the mesentery and

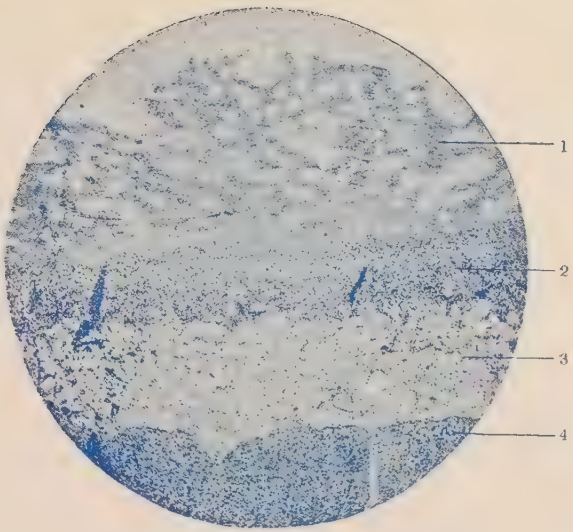

Fig. 7. FIBRINOUS PERICARDITIS.

1. Layer of spongy fibrin.
2. Serous epicardium, infiltrated and œdematous.
3. Subserous areolar tissue.
4. Cardiac muscle.

Obj. 1 in., without eyepiece.

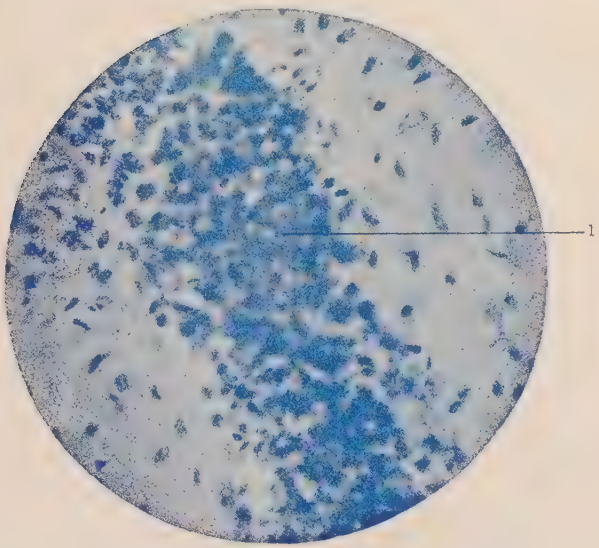

Fig. 8. PORTION OF MESENTERY, FROM A CASE OF SUPPURATIVE PERITONITIS.

1. Small vessel surrounded and obscured by numerous leucocytes, many of which are disintegrating. There was an adhesion along this line.

Obj. ½ with eyepiece.

on its serous surfaces, where the exudate constitutes a false membrane. Owing to its sticky nature the band had become adherent to an adjacent piece of mesentery and had to be torn away to allow of the preparation being made. There was no fluid in the abdominal cavity, but the vessels were injected and at one spot there were adhesions caused by fibrinous exudate.

NOTE.—Like the alveoli of the lung the serous cavities are convenient receptacles for the exudates. The liquid poured out can be readily analysed and the large excess of albuminoids which inflammatory "serous" fluids contain, demonstrated. The walls are very often encrusted with a thick deposit of fibrin, which interferes greatly with absorption, and which may remain for an indefinite time, becoming, as we shall see later, partly vascularised; or the deposits on opposite walls may adhere, and vascular channels be established across. The exudation may become purulent.

III. **Inflammation of Mucous Surfaces.**—The inflammation of mucous surfaces introduces some special points for consideration.

Fig. 9 is a section of early ACUTE BRONCHITIS in the stage of engorgement. From the surface of the bronchus the ciliated epithelium has become detached. This does not necessarily imply that during life the cells were not still present, for there are the effects of the delay post-mortem, and the handling incidental to frozen gum sections; but from other evidence we know that the epithelium does show an undue tendency to fall off early in inflammation. The subepithelial homogeneous ground substance, or basement membrane, is slightly swollen. The other noticeable

feature in the section, is the great engorgement of the vessels.

Fig. 10.—This represents a much more intense condition in the smaller bronchi. The lumen of each bronchiole is filled with a granular plug, the bronchiole itself looks like a thickened ring of the same material and many of the adjacent alveoli are filled with similar granules. The high power shows at once that these granules are leucocytes; and, further, that the columnar epithelium has lost the well-defined appearance of health, is wanting in places, or is obscured by leucocytes; and that here and there the nuclei of the columnar cells are undergoing proliferation.

The appearance of the section, with the inflammation obviously centering around each bronchiole, is such as at once to suggest BRONCHO-PNEUMONIA.

On the right the mucous membrane is a swollen mass of distended capillaries, extravasated red corpuscles, numbers of shrivelled leucocytes and other cells, whilst granular débris and a few distinct gland cells towards the mucularis mucosæ are the only remains of the crypts of Lieberkühn. This condition passes insensibly into the exudate above, composed of faintly staining cells of various forms, amongst which the red and white corpuscles are abundant, all being entangled in a fibrinous network. Muscularis mucosæ is scarcely to be distinguished. The submucous areolar tissue contains many widely dilated lymphatics with dark fibrinous coagula in their centres. Distinct degenerative changes are seen even in the muscular coat.

The appearances are such as at once to lead us to conclude that the tissues have been killed down to the areolar layer, and that the successive changes which

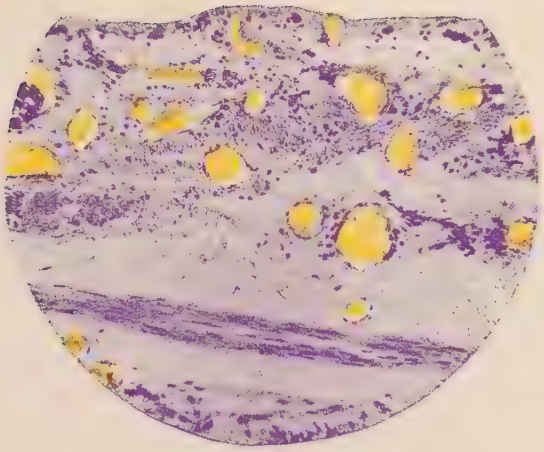

Fig. 9. ACUTE BRONCHITIS.

Section of a mucous membrane of a bronchus. The epithelium has become detached, the vessels are engorged, and the tissue is œdematous. The muscularis mucosæ is seen at the lower part of the section.

Obj. ½, without eyepiece. (Logwood).

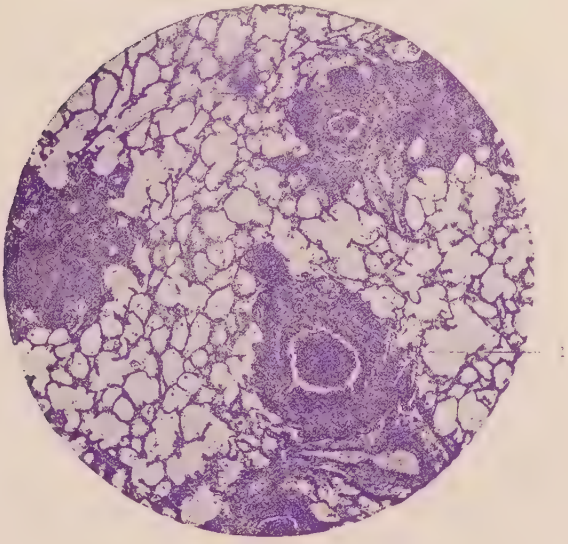

Fig. 10. BRONCHO-PNEUMONIA.

1. One of 3 bronchioles in the field, each of which is filled with exuded leucocytes and surrounded by alveoli filled with the same.

Obj. 1 in., without eyepiece. (Logwood).

lead to this might be summed up as, *congestion* of the great vascular network of the mucous membrane (accompanied by increased secretion of mucus); *desquamation* of the surface epithelium and loosening of the crypts from their attachments; *serous exudation; fibrinous* and *leucocytic exudation* with considerable *extravasation of red corpuscles;* arrest of the circulation by *thrombosis* and finally *necrosis.* Inflammation accompanied by signs like these may be termed *diphtheritic.*

On the left the mucous membrane is scarcely swollen and the vessels are not as engorged as on the right; the glands are recognisable and are not much altered, a few are loosened and the surface epithelium has gone; leucocytes have wandered out and a membrane has formed, but as the figure shows it is easily detached.

This milder form of inflammation may be called *croupous.* We must bear in mind, however, that the terms croupous and diphtheritic are names only used in connection with ordinary types of severe exudative inflammation occurring on mucous membranes, and occasionally on granulating surfaces elsewhere, and that they do not as terms express a truly scientific distinction.

Diphtheritic pharyngitis.—In diphtheritic pharyngitis a section through the soft palate, the root of the tongue, or the epiglottis, when covered with membrane, shows that the epithelium and sub-epithelial tissue, to a variable depth, are infiltrated with both leucocytes and red corpuscles entangled in richly fibrinous material. That most of the epithelial cells have disappeared and that those which remain are with difficulty recognised, having become vacuolated and undergone coagulative necrosis. This necrosed mass constitutes the *membrane,*

and immediately beneath it the tissue is œdematous, infiltrated and the vessels congested.

A bacillus (Klebs-Löffler) has been found to be the cause (*see* pp. 97 and 103).

IV. **Inflammation of Parenchymatous Organs.**

The inflammatory process as seen in a glandular organ may be considered from several points of view, *e.g.*, the changes in the vessels, in the gland cells, in the supporting stroma or framework, &c. A good example is the acutely inflamed *kidney*.

The kidney is composed of special vascular mechanisms, the glomeruli, and of gland tubes. The former excrete (roughly) the fluid, the latter, the solid constituents of the urine. They both form part of a common apparatus and are dependent upon one another, so that the lesion which affects the one, reacts also on the other, though not necessarily with the same force.

Each glomerulus is a tuft of capillaries which projects into the dilated extremity (Bowman's capsule) of a renal tube, from which it receives a reflection of epithelium of extreme delicacy. An afferent arteriole, derived directly from an interlobular artery, feeds it, and the blood after circulating around finds its way out by a very much finer efferent vessel, into a vast interlobular network of capillaries in close contact with the remaining gland tissue of the kidney; finally it passes into an interlobular vein.

Inflammation of the kidney in the large majority of cases commences as a *glomerulo-nephritis*, the delicate walls of the capillaries and their equally delicate epithelial investment being the earliest to suffer; and instead of the non-albuminous urine, one laden with albumin escapes. If the inflammation still progresses,

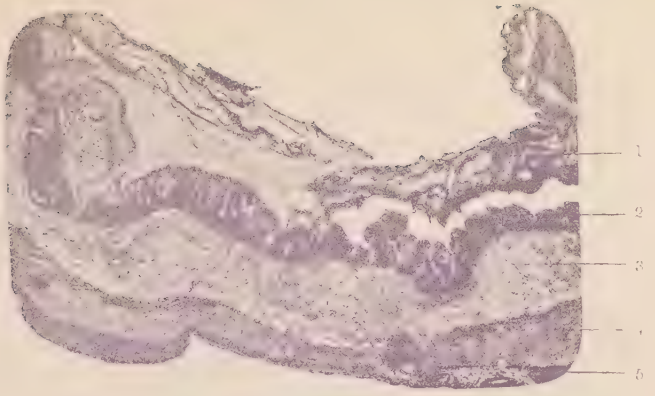

Fig. 11. CROUPOUS (to left of fig.) DIPHTHERITIC CONDITION (to right of fig.) OF THE COLON OF MONKEY, WHICH CAUSED COMPLETE BLOCKING OF GUT.

1. The fibrinous and corpuscular exudate (membrane).
2. The glandular layer.
3. The submucosa.
4. The circular muscular layer.
5. One of the three longitudinal muscular bundles.

Obj. 4 in. (Logwood).

Fig. 12. ACUTE NEPHRITIS. Scarlatina, early stage.

1. Bowman's capsule.
2. Glomerulus, increase of nuclei and swelling of ground substance.
3 & 4. Hyaline casts in renal tubes, the appearance of the nuclei in places is such as to suggest nuclear figures.

Obj. ⅛ without eyepiece. (Eosinated Logwood).

corpuscles, especially the red, make their way out, and produce smoky or bloody urine, the naturally high pressure in the glomerulus no doubt greatly facilitating the diapedesis. The casts which may now appear consist for the most part of fibrin, of red and white corpuscles, and of renal débris, moulded in the tubes.

The glomerular disturbance is followed by that of the rest of the vascular network and of the gland cells. The latter become swollen and "clouded" and are readily detached. The swollen cells may occlude the lumen of the ducts and press upon the vascular tissue without. Or the capillaries are congested and exudation swells the intertubular tissue. In any case the kidney is enlarged and softened. Sometimes during life, the signs of nephritis are well marked, but after death the anatomical lesion appears very slight; in these cases comparison with a normal kidney, both to the naked eye and under the microscope is invaluable, as then some change can usually be detected.

Fig. 12 is a section, under the $\frac{1}{4}$ in. obj. with eye-piece, of a glomerulo-nephritic kidney, from a patient who died in the course of an attack of scarlet fever. Before death the urine was loaded with albumin. 2 points to an enlarged glomerulus, the ground substance of which is swollen and softened; it is likewise more corpuscular than normal, many of the nuclei belonging to exuded leucocytes. 1 is Bowman's capsule, and a space intervenes between it and the glomerulus which is often filled with exudation products. 3 and 4 point to hyaline casts in two renal tubes which are dilated, whilst their epithelium as well as that of the other tubes is undergoing fatty disintegration.

V. **Inflammation of connective tissue.**

There has been connective tissue in all the organs which we have hitherto examined and it has been affected in every one. But we have now to deal with inflammation of larger masses, such as the subcutaneous tissue which is accompanied during life by the familiar and characteristic symptoms—*redness*, *swelling*, *heat* and *pain*, which were understood to signify inflammation long before the microscopic changes were known.

As before, we shall look for the various stages of congestion and exudation. The first specimen taken to illustrate this very important division of our subject is shewn in :—

Fig. 13. This is a section of inflamed areolar tissue, showing typical appearances.

Grouped around a small vein, which has bifurcated, are innumerable extravasated leucocytes, whilst some have penetrated amongst the neighbouring fat cells. There is also proliferation of the tissue corpuscles.

The part was slightly œdematous and the vessels engorged. The effect of the œdema is not so obvious in the section as it was not sufficient to prevent the skrinking of the specimen.

A further stage is shewn in **Fig. 14.**

In this figure the most prominent feature is a large collection of deeply stained leucocytes contrasting with the pale areolar tissue around, which is much softened and swollen from the effects of the serous exudation.

This preparation was made from a case of marked cellulitis of the finger accompanied by the typical cardinal signs. At one spot, deeply under the skin, pus had formed in considerable quantity, and in the immediate vicinity were scattered several smaller foci of

Fig. 13. INFLAMMATION OF AREOLAR TISSUE.

1. Small vessel surrounded by small round-celled infiltrat
2. Fat cells (fat dissolved out).

Obj. ¼, without eyepiece. (Carmine.)

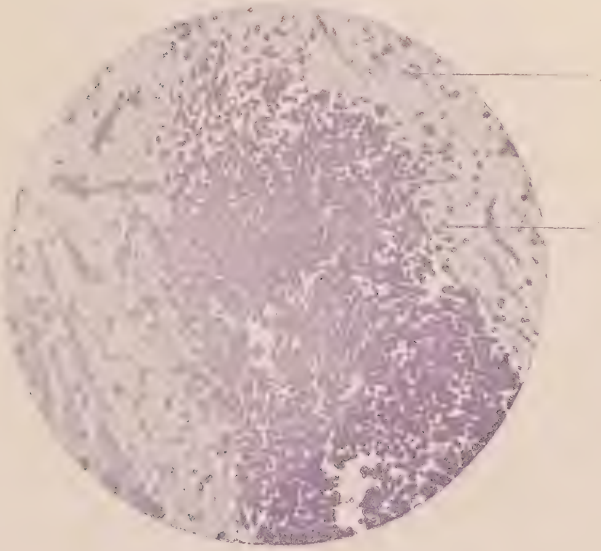

Fig. 14. COMMENCING ABSCESS FORMATION IN AREOLAR TISSUE.

1. The œdematous areolar tissue.
2. Focus of leucocytes.

Obj. ⅛ in., without eyepiece. (Logwood.)

suppuration. The section passes through the early stage of one of these, and its history is as follows:—

The irritant, undoubtedly a micro-organism, has brought about the usual inflammatory changes, congestion, serous exudation, and in places of still greater intensity, escape of leucocytes. These form masses, as in the illustration, and show a remarkable tendency to undergo fatty degeneration and so to become *pus cells*. The softened and œdematous tissue in which they lie disintegrates, *i.e.*, the ground substance liquefies, and the sero-fibrinous exudation accumulating, a creamy fluid or *pus* results.

If the irritation continues the pus focus enlarges, for as new vessels are involved in the widening area, so fresh fluid and corpuscles accumulate, and further breaking down occurs.

In this way an *abscess* is formed. In the centre is the cavity filled with pus, then comes a wall of disintegrating tissue infiltrated with leucocytes, which, so long as the irritation progresses, is being continually added to externally, and as incessantly breaks down. On the outside of this layer the vessels are engorged with blood, the connective tissue swollen and œdematous and the lymphatics distended. From time to time slight hæmorrhages may take place into the cavity from rupture and disintegration of the small vessels exposed in the wall, but it is prevented to any great extent by previous thrombosis.

A further stage in the severity of inflammation in a connective tissue is well seen in the condition known as spreading gangrene and as sloughing phagedæna. In these cases the inflammation is so severe as to cause necrosis or death.

Fig. 15 is a section slightly magnified of the skin and subcutaneous tissue of the arm at the margin of a spreading gangrene.

Stretching obliquely from left to right is an irregular deeply stained zone (3), composed of leucocytes and comparable to the abscess wall described above. On the left of it, the tissue is sodden and swollen, the lymphatics much dilated and the vessels congested. As we approach the corpuscular zone, the leucocytes form small groups around the vessels from which they have escaped, and indeed if any one such collection were more highly magnified it would be precisely like the preceding illustration (**Fig. 13**); the areolar tissue here also becomes loaded with coagulated fibrin in place of the œdema fluid nearer the skin. The band itself is made up of a great mass of leucocytes with a few red corpuscles, but immediately beyond there is considerable extravasation of the latter. Then connective tissue bundles, ground substance and fibrin become fused into a nearly amorphous mass (4), red corpuscles, and faintly staining leucocytes being visible here and there. Beyond this the gangrenous *débris* has fallen away.

If we now compare this condition with the preceding, we find the main difference is in the rapidity and intensity of the inflammatory process. The irritant, likewise a micro-organism, is more virulent and spreads more rapidly, and induces a copious fibrinous and leucocytic exudate with considerable extravasation of red corpuscles, thrombosis and necrosis.

The necrosed elements form a coagulated mass or *slough*, rather than fluid pus. A wall of leucocytes marks the junction between the living and the dead and the place where the slough will be separated

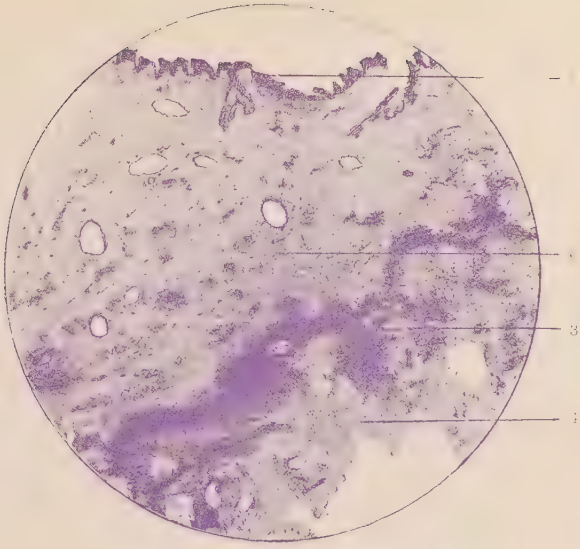

. Epithelium.
. Œdematous areolar tissue with dilated vessels and lymphatics.
. Leucocytic zone.
. Sloughing Tissue.

Obj. 4 m Logwood.

Fig. 16. COVER SLIP PREPARATION OF PUS

1. Chain of streptococci.
2. A pus cell with quadripartite nucleus
3. Scattered streptococci

Obj. $\frac{1}{12}$ without eyepiece

by ulceration when the spreading sphacelation is arrested.

In still more rapid and intense inflammatory processes as in spreading traumatic gangrene, the tissues are distended throughout with extensive fibrinous, leucocytic and hæmorrhagic deposits, the wavy bundles of connective tissue being widely separated. The vessels are much engorged and filled with fibrinous coagula. There may be numerous *vesicles* on the surface; in some places the horny layer being separated from the rete mucosum by the rapid transudation of exudation fluid across the more pervious rete, in other places the whole thickness of the epidermis being raised from the papillæ by a hæmorrhagic and pustular exudation. The epidermal cells are in all stages of destruction.

In these necrotic changes the tissues give a different logwood reaction, the white corpuscles scarcely staining at all, whilst the fibrous and epidermal structures assume a redder tint.

(Acute Catarrhal Inflammation and Acute Ulceration are described in the chapter on Chronic Inflammation).

Chapter III.

FATE OF THE EXUDATES AND REPAIR.

As soon as the cause of the acute inflammatory process ceases to operate, repair commences and is marked by the regeneration of tissue, and the removal of exudations and dead tissue. Also, according to many by productive changes in the escaped leucocytes.

In slight inflammation injured cells and vessels are restored to their normal condition, and that which is actually dead is removed. New scaly epithelium and new connective tissue replace their kind; but the reparative powers of the higher tissues, such as the nervous, glandular, and muscular is not so marked, and connective tissue most commonly fills the gap.

The new tissue is exceedingly vascular and may grow to excess while the cells around are often stimulated to increased activity of growth. In this way are produced the large polypoid hyperplasias of mucous membrane which often fringe a dysenteric or tubercular lesion in the intestine, and the great overgrowth of bone which may take place around a necrosed fragment. Apart however from these hyperplasias, it is exceedingly characteristic for the new tissue to finally become dense and bloodless and to contract. Taking these facts in more detail it will be best to consider:—

The fate of (1) the *Serous Exudate.* The serous fluid which may have exuded in excess is soon absorbed, more especially by the lymphatics, and in many of the preceding specimens these can be seen to be widely

distended. If it collects in a cavity like the pleural and if in addition the walls are coated by a dense fibrinous exudate, the absorption takes a much longer time, since the absorbent surface is considerably injured.

The fate of (2) the *Fibrinous Exudate*. In phlegmasia alba dolens, the swelling and induration take a much longer time to disappear than in a simple œdema, because in the former the injury is more severe and has led to a fibrinous exudate and to the occlusion by clotting of many of the absorbent lymphatics and veins. A thick coat of fibrinous exudate on a free surface like that of the pericardium or pleura, may remain as a finely stratified and nearly structureless deposit for an indefinite time. An attempt is made towards absorption, by the ingrowth of small vessels and fibroblasts which channel it in all directions and replace it here and there by a fibrillated growth of connective tissue which ultimately tends to contract and produce puckering of the surface.

The fate of (3) the *Red Corpuscles*. The red corpuscles are removed as follows:—While some may be directly reabsorbed into the circulation, the major part undergo disintegration, the colouring matter separating from the stroma, and months after the infliction of a wound, their pigment may be seen deposited in large cells or free in the areolar spaces at the seat of the exudate. Some of the pigment likewise finds its way into the nearest lymphatic glands.

The fate of (4) the *Leucocytes*. Of the leucocytes many pass into the lymphatic streams, and as in several of the former sections, the dilated lymphatic channels may be filled with them. But numbers remain in the damaged tissue and from their appearance in crowded

masses look very much as if they had proliferated. These foci as we have already seen are very prone to degenerate and form pus, which is subsequently absorbed, or becomes concentrated into a cheesy mass which may calcify.

The mixture of exuded fluid and corpuscles with the liquefied débris of the inflamed tissue is known as *pus*. We must therefore devote a little space to its consideration.

Fig. 16.—This is a cover slip preparation of pus from a spreading cellulitis of the leg. The multipartite or fragmented nucleus of the pus leucocyte is characteristic, and is usually looked upon as a sign of the degeneration of the leucocyte. Slight granular and fatty changes are commonly seen in the protoplasm, though in many instances the latter may appear quite normal. Various other cells are met with and of course many such exuded corpuscles have been shown to be alive.

Corpuscles with a divided but more often a *lobed* nucleus, are sometimes seen in the blood vessels and are very common in the corpuscular deposits of pneumonia; the lobes together are larger than the original nucleus, and the appearance is more suggestive of division than of degeneration.

Micrococci scattered and in chains are also seen in the figure; and there can be no doubt that the formation of pus is closely connected with the presence of microbes, of which the Staphylococci and Streptococci are the commonest, the former in localized, the latter, as in the figure, in diffuse suppuration. The consistency of pus varies. Usually a creamy fluid in which the cells and particles of necrosed tissue are suspended, it may, from the small amount of fluid present, form a

soft mass of caseous material, in which no cells or at most a few breaking down nuclei can be recognised.

Pus in small quantity is probably completely absorbed; or a larger collection becomes walled in by repair or granulation tissue in which both retrograde and reparative changes takes place, but these details we shall deal with under *chronic abscess*. Sometimes the fluid portion is absorbed, and the solid constituents remain as an encapsuled mass of caseous material in which lime salts may subsequently be deposited.

Leucocytes as Phagocytes.—We have noted the association of an abundant small celled migration with micro-organisms, especially the cocci, and we have shown the almost constant presence of the latter in pus. Now in cases of acute inflammation, they have been actually demonstrated to be present in the leucocytes and it is most probable that the latter seize, and render them inert, thus acting as phagocytes. For instance the cells massed together into a band in **Fig. 14,** and which is similar to that seen stretching across the ear of a mouse inoculated with the virus of spreading gangrene,* form probably the barrier where the struggle takes place with the invading micro-organisms. The virus in these two examples, however, is so intense that numbers of leucocytes are destroyed and converted into pus cells, or lose their outlines by necrosing into a gangrenous mass; the inflammation therefore spreads and fresh leucocytes take the place of those which have perished and so the struggle goes on. Later on under the *chronic infective inflammations* (as Tubercle), attention will be directed to the constant presence of numerous and characteristic cells—macrocytes—which

* Koch "Infective Traumatic Diseases."

are usually included under the term "epithelioid," many times larger than leucocytes, and sometimes immense giant cells in which a precisely similar struggle goes on and which are in all probability phagocytes. The question of course will arise whether these have sprung from migrated leucocytes or from the pre-existing tissue corpuscles. The origin of the *macrocytes*, *fibroblasts* and *capillaries* of the repairing tissue, is a matter of dispute which we may now proceed to study.

The Repairing Tissue.—The new growth of tissue is richly corpuscular and vascular. The cell forms are numerous. Preponderating are the *small round cells*, which are probably both leucocytes and proliferating connective tissue cells. Then there appear all transition stages between these and spindle shaped cells—the *fibroblasts* which are believed by some to form the fibrillæ of the new connective tissue—and between the large round or irregular cells, which we will term *macrocytes* and in whose interior very commonly indeed are to be found all kinds of foreign bodies, such as droplets of myelin in wounds of nerve tissue, and pus cells, red corpuscles or more often blood pigment in cases of corpuscular extravasation. The number of these large cells varies considerably under different conditions of repair, sometimes they are absent, at other times they are extremely abundant, and in the absorption of solid material as sponge they reach a great size.

(1) **The Macrocytes.**—In **Fig. 5** attention was directed to very large cells in the midst of an exudation rich in blood corpuscles contained in the alveoli of an inflamed lung. When they are examined carefully, particles of *soot* will be seen in several, whilst in a few

a *red corpuscle* or a *leucocyte* may be discovered, the latter very often appearing to lie in a vacuole. Usually possessing but one nucleus, some will be met with which are multinucleated and very large (giant cells). In shape they vary considerably, but are not merely flattened endothelioid plates, many of them having a distinct amœba-like outline with coarser or finer processes. The nucleus is often large and oval, though sometimes distorted ; it stains less deeply with logwood than does the nucleus of the small round cell. The protoplasm is granular or reticulated and is very often vacuolated.

These cells may be *Phagocytes* which appearing on the cessation of the acute irritation, help to get rid of the extravasated red corpuscles and fibrin and prepare the way for the next process, that of vascularisation.

Similar cells are normally present in the tissues (probably as "plasma cells") but it is in the lung, and in the alimentary tract, as has been more recently shown, that they are conspicuous and busy in removing foreign matter as dirt particles, microbes &c. For instance in the lung the familiar *soot-containing-cell* is present in the alveoli, in the lymphatic spaces of lung tissue, in the bronchial glands and in bronchitic sputum. In pulmonary *fat embolism*, the large cells contain fat droplets. In *chronic congestion* or *brown induration* of the lung the cells in the alveoli contain *red pigment*, which they have obtained from blood corpuscles. Similar blood-pigment containing macrocytes may be seen after a subcutaneous extravasation of blood, both around the clot, in the lymphatic interstices and channels for a considerable distance leading away from it, and perhaps in the nearest

lymphatic glands. If a focus of destruction of white matter in the brain or spinal cord be examined, numerous macrocytes are found containing myelin drops—their older names were "Gluge's corpuscles," "inflammatory," or "granule cells." In chronically inflamed granulation tissue, especially that due to Tubercle, the macrocytes are very prominent and in the case of Tubercle, the bacilli can very often be demonstrated in them.

Experimentally we can prove that the macrocytes are amœboid, and looking at them as a group it will be seen that we are dealing with migratory cells, capable in the highest degree of taking up foreign matter. They may be the offspring of the "plasma cells" of connective tissues, or be derived from leucocytes. The latter view certainly would explain the condition met with in **Fig. 5,** where there are all stages between the leucocyte and the macrocyte. It is difficult to say what may be their ultimate fate. In the alveoli of the lung their protoplasm very often *disintegrates;* and in lymphatic glands and in dense scar tissue we see them still containing soot or pigment—or simply the soot and pigment, the protoplasm having disappeared. But whether they are capable of becoming fibroblasts is doubtful.

(2.) **The Fibroblasts and Capillaries.**

Fig. 17.—This depicts a condition in the lung which very commonly follows that represented in **Fig. 5.**

Originally as in 5, blood corpuscles and fibrin, and macrocytes filled the alveoli. But now the exudate has contracted away from the walls except at one or two places where it remains adherent. As yet the walls are not thickened.

Fig. 17. VASCULARISATION OF ALVEOLAR DEPOSITS

1. Corpuscular and fibrinous material in the alveoli.
2. A small capillary cut across.

Obj. $\frac{1}{8}$, without eyepiece. (Eosinated Logwood)

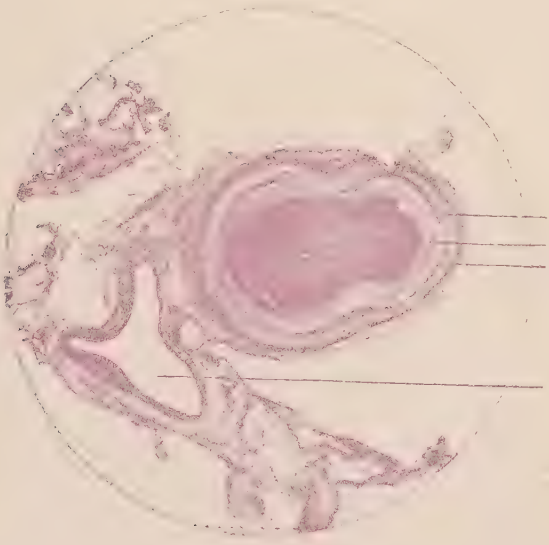

Fig. 18. VASCULARISATION OF A THROMBOSED VESSEL

1. Artery wall.
2. Layer of newly formed vascular tissue.
3. Thrombus.
4. Vein.

Obj. 4 in., without eyepiece. (Eosinated Logwood.)

The deposit consists of a ground work of the *débris* of fibrin and corpuscles. At the edge are numerous *macrocytes*, and in the centre is a group of elongated spindle like cells—*fibroblasts*—which surrounds two minute *capillaries* (2), and finally numerous *small round cells* are dotted about. Thus all the elements of granulation tissue are present.

The explanation of the above appearance is probably that the exudate has been invaded by an outgrowth of fibroblasts and capillaries from the vascular fibrous tissue of the wall. It is the final stage in repair, being the building up of tissue, which removing the last traces of the original exudate, contracts and remains as a slight thickening of the alveolar wall.

The terms *vascularisation* or *organisation* are usually applied to this process, when as above, there is an exudate to be removed. It is typically seen in the fibrinous formations of the pleura and pericardium, and is the means whereby permanent vascular fibrous union is effective between the opposed surfaces. It is especially well seen in thrombosed vessels, one of which is now figured in order to discuss more fully the cell forms mentioned above.

Fig. 18 is a section of a thrombosed artery under a very low power, but it serves to show where are the formative cells, and the changes in the clot they produce.

The wall of the artery is indicated by 1, 3 is the clot, and 2 contrasting with both of these, is the zone of all activity. The central portion consists of red corpuscles and fibrin; at its edge it is broken up into lumps, between which some macrocytes will be recognised (glycerine preparations); then as we get more into the

formative zone, small round cells markedly increase, the masses of clot are much attenuated, and between them and amongst the nuclei are one or two regular large oval nuclei belonging to peculiar oblong cells which can be traced to their connection with minute newly formed capillaries; these are in fact the growing offshoots of the capillaries, which apparently become hollowed out. Following these sprouting vascular channels back they are seen to form a network in a tissue, which here consists of 1, the *shreds* of the original clot, of 2, the fibroblasts which are elongated or angular, and which have long and delicate processes. The fibroblasts are embedded in a faintly staining homogeneous material, which is here and there fibrillated; macrocytes too are present and are conspicuous from the golden pigment they contain; finally there are a few small round cells.

Note.—The removal of masses of dead tissue by absorption or by sloughing, and also that of foreign bodies, is reserved for consideration in the special chapter on *Wounds and Foreign Bodies.*

Chapter IV.

CHRONIC INFLAMMATION.

In chronic inflammation there is often an abnormal exudation of serum from the vessels, and very often a leucocytic migration from them; but most characteristic is a progressive corpuscular multiplication, which under more favourable circumstances gives rise to a dense scar tissue, but which, subjected to unfavourable changes passes by an imperfect state of development into a harder or softer necrotic material; the growth and transformation being parallel.

The corpuscular mass is formed by the proliferating tissue cells of the part, chiefly the fibrous and endothelial. There are also leucocytes. The proliferation is not limited to these elements, but to a slight extent is shared by the more specialised, as the adipose gland, muscle, nerve, epithelium, cartilage, and bone cells. Very often these higher cells undergo degeneration and atrophy in the inflamed part, and this is especially liable to occur from the pressure and loss of vascularity induced by the growth and transformation of the new connective tissue. But constantly too they tend to alter their character, and by dividing they build up with the new connective tissue an imperfect structure, or even a neoplastic tissue; thus in the pulmonary infundibula and air spaces, the flattened lining cells, where present, multiply and assume a cubical shape, and may form almost gland-like crypts; whilst in the

kidney this is carried still further, and cystic, papillomatous and adenomatous formations may arise from the altered renal tubes. In striated muscle the "attempt at growth" is very instructive—the nuclei divide and the protoplasm around them increases, but the fibrillation of the latter being very imperfect, if at all, a multinucleated undifferential mass remains, which is practically a muscle giant cell.

The small round celled mass grows. *Connective tissue* being produced by the proliferating connective tissue corpuscles, but elastic fibres are not usually formed, nor is the fibrillation always complete, and often before this stage retrogressive changes occur. *Macrocytes*, and from them *giant cells*, in all probability originate from the leucocytes; some of the giant cells, however, appear, like those of the muscle mentioned above, to be undifferentiated connective tissue cell masses. Delicate *new vessels* are developed, the structure thus becoming a granulation tissue, but their formation like that of the connective tissue is very often imperfect, and they are prone to undergo degenerative changes. They are derived by proliferation from the endothelial cells of the pre-existing capillaries. Indeed it is usual for cell multiplication to take place in all the coats of the vessels, and this is especially so in some inflammations, and for transformations to occur just like those of the developing connective tissue. In this way many of the lumina become occluded.

The granulation-tissue assumes characters which are typical of certain classes of inflammatory agents. For instance in Tuberculosis there is a large growth of macrocytes and giant cells, in which the pathogenic

fungi can be demonstrated, whilst there is but a very imperfect formation of vascular fibrous tissue, and the whole exhibits a marked tendency to *caseate*.

In Syphilis the small cells for the most part develop into a dense fibrous tissue, which may become quite structureless, remaining hard, and rarely caseating. The vessels too in this disease are especially involved. In certain chronic inflammations of the kidney and liver, there is a less marked and a more gradual transformation from the young cells to a more fully developed fibrous tissue, in which many permanent new vessels can be demonstrated.

In chronic inflammation with its marked tissue cell proliferation and accompanying increased vascularity, one sees the older (Virchow's) view of inflammation. Whilst in well-marked acute inflammation, with its prominent vascular phenomena—notably the leucocytic, and with the less prominent tissue changes—and these mostly retrograde, we become acquainted with Cohnheim's view. These extremes merge into one another, on the one hand by the proliferative tissue changes decreasing, and on the other by the vascular phenomena increasing, and *vice versâ*.

Examples.

Fig. 19.—This slightly magnified section shows one of the small inflammatory nodules which are characteristic of tubercle. The appearance of the lung is considerably altered. The figure 1 points to a small consolidated patch, the tubercular **granuloma** (the well known grey granulation), many of which were scattered throughout the lung. Around are widely over-distended

air spaces, alternating with thickened septa and obliterated alveoli; the pleura is also thickened. The nodule is made up of nest-like formations, consisting of central lighter parts, surrounded by deeply staining tissue, whilst a couple of giant cells—the dark rings—form the centre of two of the nests. One of the nodules is seen more highly magnified in **Fig. 20,** and shows the typical appearance of tubercular granulation tissue. Figure 1 points to the encircling zone of *small round cells*—proliferating connective tissue corpuscles, endothelial cells and leucocytes; 2 is a second zone, *epithelioid zone*, invariably present in the tubercular inflammations, in which the cells and their nuclei are larger and fewer, and are markedly distorted, many of the nuclei appearing about to divide; they are derivatives of the small round cells. Some of the epithelioid cells may contain 2, 3, or more nuclei, and, in fact, all transition sizes may be encountered, up to the huge multinucleated masses—*giant cells*, 3. In the present instance (as usual in tubercle) these corpuscles, with the exception of the giant cells, are undergoing early necrotic changes, so that the outlines of the cells are lost or fused together.

BOSTON MEDICAL SEP 22 1911

The epithelioid is the zone of greatest activity of the fungus, and to this cause must be attributed the remarkable cell changes just described, and that which next ensues, namely, the transformation of this central tissue into a *caseous* mass, the giant cell nuclei being the last to resist the change. Occasionally, however, and denoting the cessation of the irritant action, a semi-structureless, but *fibrous* and harder material, is formed.

Giant cells vary. In tubercle the nuclei usually form

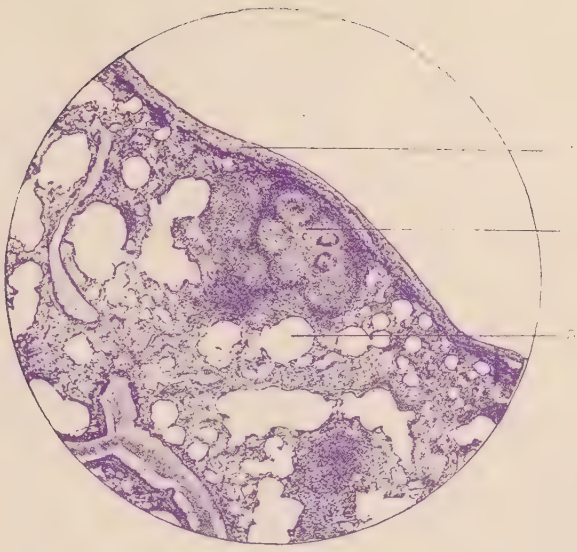

Fig. 19. MILIARY TUBERCULOSIS OF LUNG

1. Thickened pleura
2. A 'tubercle' composed of several small nests
3. Emphysematous condition of the alveoli.

Obj. 1 in., without eyepiece. (Logwood.)

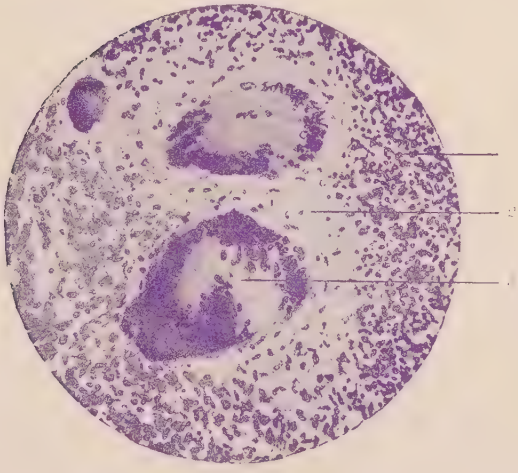

Fig. 20. PORTION OF THE ABOVE "TUBERCLE"
Under the $\frac{1}{8}$ in. Obj.

1. The small round celled zone.
2. The epithelioid zone and zone of necrotic changes
3. A large giant cell.

a ring near the margin of the cell, or have a bipolar arrangement, and are apparently always away from the bacilli. Their outlines may be well defined, like those of macrocytes, and from which they in many cases appear to originate ; sometimes they are irregular, and the margin is lost in the intracellular substance of the zone around. It is probable that they are derived both from the fixed tissue corpuscles (fibroblasts, endothelial cells, &c.), and from leucocytes. Though characteristic of tubercle, they are also met with in most soft granulation tissues, where all stages can be traced in their formation from smaller cells.

This too may be seen *in the alveoli* of tubercular lungs, where the giant cells may in addition contain carbon particles. Occasionally, in more vascular granulation tissue, the giant cell is composed of a ball of nuclei.

Very few new vessels are formed around the granuloma, and then only if the process is very prolonged, allowing time for their formation as well as of that of the connective tissue. In the present section, **Fig. 18,** there is considerable engorgement of the vessels, generally of the lung, and this is of common occurrence, as well as exudation into the alveoli.

Macrocytes are not numerous ; a few are in the central epithelioid zone. In pulmonary phthisis, however, they are extremely abundant, especially in the alveoli.

If the bacillary activity is not checked, caseation spreads, and with it the zones around. Adjacent alveoli become filled up with cells and included in the spreading granulomatous tissue ; nodules thus formed then coalesce, and large patches of consolidation result.

This spreading consolidation is seen in **Fig. 21,** a very low power section of a chronic phthisical lung.

Small caseating centres, as at 1 and 2, surrounded by inflammatory tissue, have spread, and by their union have caused the obliteration of the air spaces over a very extensive surface. The caseous material, it will be observed, stains deeply with the logwood, and this is especially so after prolonged treatment with the reagent. Around it there is not the marked and sharply defined small round cell zone, which is seen in the more acute inflammations; but the growths are more diffuse and the lines of demarcation for the most part absent. The zone of transformation may be recognised with its epithelioid and giant cells, whilst macrocytic forms are especially abundant in the alveoli. As the latter spaces become included in the imperfect granulation tissue, and as this undergoes the caseous transformation, the outlines of the macrocytes, as indeed of everything else, is lost, but the soot that some of them contained always remains as pigmentation.

Vessels of new formation are numerous, and may be seen growing into the alveoli in the process of vascularisation. The special epithelial cells, alveolar and infundibular, may be observed, becoming cubical and proliferating; but this is not so marked as where there is a more perfect fibrous vascular tissue formation as is seen in the following case.

Fig. 22.—An instructive section which shows the rarer occurrence in tubercular inflammation, namely, the building up, by the growth of the fibroblasts of the granuloma, of fibrous nodules. The tubercular process is slower (and the action of the poison much less intense), allowing of the formation of small vessels

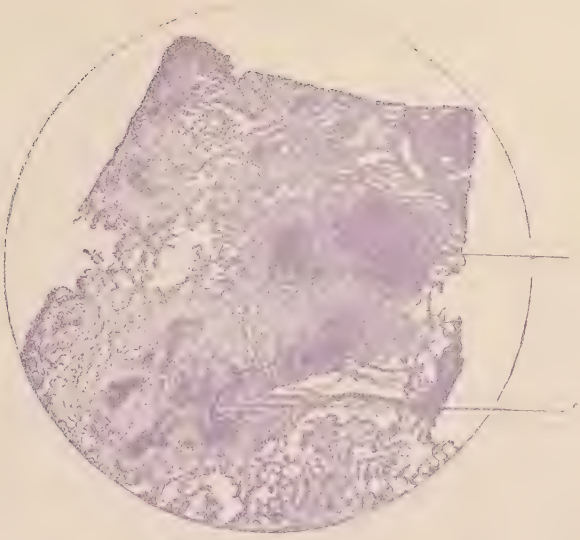

Fig. 21. CASEATING TUBERCLE IN THE LUNG.

1 & 2. The caseous centres which are causing considerable consolidation.

Obj. 4 in., without eyepiece. (L. Atwood.)

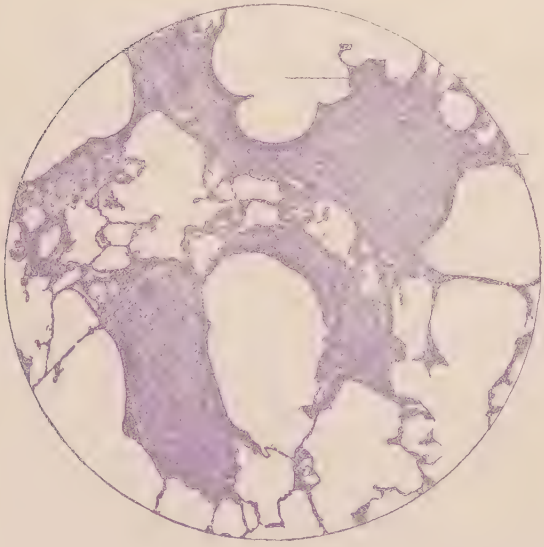

Fig. 22. FIBROID NODULES IN LUNG, MOST PROBABLY OF TUBERCULAR ORIGIN.

1. Most marked emphysematous dilatation of air spaces.
2. A fibroid nodule.

Obj. 1½ in., without eyepiece. (L. Atwood.)

and of an intracellular substance, which, however, does not fibrillate properly. Giant cells and large cell forms become included in the dense mass, preserving their outline, though they may be compressed. The ultimate fate of these nodules may be a hyaline or caseous change. Towards the edge of the nodules, corpuscles are more abundant, and here the growth of the fibroblasts, of the endothelial, and of the alveolar epithelial cells, may be studied. Sometimes the exuberant growth of these elements leads to papillomatous and gland-like formations.

The emphysematous condition of the intervening lung tissue will be especially noticed in the above figure. It is present in all chronic pulmonary inflammations, alternating with patches of consolidation. The septa become weakened and the new tissue is devoid of elasticity; this is well shown at the periphery of the nodules, where the air pressure has caused permanent moulding of the plastic granulation tissue.

As in acute inflammation, so in chronic, conditions are met with (corresponding to the acute) which have received special names, such as *catarrhal inflammation*, *ulceration*, *caseation*, the *chronic abscess* and *sinus*. They will be next considered, for they afford instructive pictures of the more chronic inflammatory processes.

1. **Catarrhal Inflammation and Ulceration.**—Catarrhal inflammation and ulceration are chronic inflammatory processes taking place in *skin* and *mucous membranes*. In both there is considerable connective tissue and endothelial proliferation, in both considerable serous and leucocytic infiltration. In *catarrhal* inflammation the surface epithelium remains, prolifera-

tion keeping pace with the degeneration and *desquamation;* there is a discharge—not a deposit as in the very acute and intense lesion of croup or diphtheria—which may be serous, mucous, muco-purulent or purulent, according to the share the vascular exudates (serum and leucocytes), or the products of cell secretion in the case of mucous membranes, take. Striking examples of tissue hyperplasia may occur, producing wart-like, papillomatous, polypoid, cystic, and adenomatous growths, according to situation; of these the *colitis polyposa* of chronic dysentery is an excellent example. On the other hand contraction and atrophy very often follow. In *ulceration* the protective epithelium is destroyed, either in the beginning in the course of an acute inflammation, or more gradually through the action of some deleterious agent. The result is a raw surface or *ulcer*, the connective tissue floor of which is occupied by proliferating fibroblasts, endothelial cells, numerous leucocytes, macrocytes and even giant cells. These tend to build up a cellular and very vascular fibrous tissue—the *granulation tissue;* on the surface, however, a progressive necrosis occurs, and degenerating tissue corpuscles and leucocytes mingling with fluid exudation form the *purulent* discharge characteristic of the ulcer. Sometimes a superficial *necrotic layer* of granulation tissue is actually formed, which corresponds to the pyogenic membrane of the chronic abscess (and exceptionally as a result of infection a true diphtheritic membrane is formed). If the inflammation is acute and severe, the ulcer may rapidly widen and deepen; more often, however, the process is spread over a longer period, and vascular granulation tissue is formed, which may keep pace with the super-

ficial destruction or even overgrow into luxuriant granulations, or perhaps step beyond this and form large fungating polypoid masses. Condensation and contraction usually ultimately occur in the deeper layers, and thus produce the induration and cicatrisation met with in old ulcers. (Compare the stenosis of the gut resulting from dysenteric ulceration).

The highest importance is to be attached to the processes at work in chronic ulceration. Not only do we meet with the above mentioned polypoid fungating masses (which appear to be but temporary hyperplasias though exceptions probably do occur), but also with fibrous neoplasms—the keloids ; and further, it is unquestionable that remarkable hyperplastic changes occur in the epithelium of the ulcer margin which often proceed to cancer (*see* Tumours).

When from diphtheria, spreading gangrene, or from other causes, visible masses of tissue necrose, ulceration with the formation of pus takes place at the junction of the living and dead tissue, and the latter separates as a *slough*,* leaving an ulcer, which continues to discharge until healing is complete. This is effected, if the sore is neither too deep nor too extensive, by the granulation tissue becoming covered by the growth of the marginal epithelium, as well as by that of any deeper epithelial structures which may have been spared in the ulcerative process.

When *acute* catarrhal inflammation and ulceration are spoken of, it may be understood that the retro-

* In necrosis of bone, a *sequestrum* separates and lies in an abscess cavity. Irritating foreign bodies, and dead tissue which acts as such, become surrounded by pus and a wall of granulation tissue.

gressive tissue-changes and the vascular phenomena preponderate.

Examples.—Acute and chronic cystitis and conjunctivitis, afford good examples of catarrhal inflammation. In keratitis the changes are very obvious, owing to the previous transparent condition of the parts, and both processes, catarrhal and ulcerative, may be seen side by side.

Keratitis.—The superficial flattened cells of the corneal epithelium fall off and expose the lower ones, some of which undergo vacuolation and degeneration; others grow to replace them; a few may be *pigmented.** Amongst them are leucocytes and pus cells, and sometimes a few macrocytes. The corneal tissue beneath is swollen, and the laminæ are separated and obscured by numerous small round cells, many of which are pigmented, whilst several large dilated vessels, and smaller delicate ones of new formation, vascularise this early granulation tissue.

But here and there the epithelium becomes more and more infiltrated, and finally gives place to small ulcerating surfaces of granulation tissue—corneal ulcers.

Lupus.—In lupus there is a slow growth of granulation tissue in the skin, closely resembling that of tubercle, and due to the same cause. Slight differences in microscopic appearances are to be found, in the bacilli, which are fewer, the granulation tissue which is more diffuse and more vascular, and in the formation of dense cicatricial tissue rather than in caseation.

On examination of sections it is seen that in the

* Pigmentation is an interesting phenomenon to be observed in nearly all chronic inflammatory processes in the eye, and often in its surroundings.

corium there are very numerous, deeply staining, small round cells massed, more especially around the vessels, and occasionally forming nest-like groups, whilst a few giant cells are usually scattered about. In addition there are very often present, and in marked contrast with the small round cells, the so-called epithelioid cells, which we have already seen in tubercle. In lupus they are larger, with vesicular, very lightly staining, and often distorted nuclei; their outline may be quite indefinite or defined (macrocytes), sometimes they possess more than one nucleus, and there may in fact be all stages, up to giant cells.

Cell proliferation is marked. The vessel walls become more corpuscular, their endothelial cells may enlarge, and new capillaries may form. The epidermis may grow deeply into the skin, with the formation of numerous epithelial papillæ, and very often of typical scaly nests, the appearance being strongly suggestive of cancer, which indeed often does supervene. Elsewhere the inflammation may be seen spreading to the surface and producing catarrh, in which condition the horny cells desquamate, whilst the deeper proliferate, and leucocytes find their way through the prickly passages of the rete. The epithelium may become still more infiltrated, and undergo further atrophy and degeneration, till finally an ulcerating surface of granulation tissue is exposed. Whether ulceration occurs or not, the granulation tissue contracts into dense, almost structureless, cicatricial tissue.

Chronic abscess, sinus and caseation.—A small focus of pus is often left after an acute inflammation, and instead of being absorbed, keeps up a slow productive

and destructive change in the tissue around, with the result that a chronic abscess is formed, walled in by some kind of granulation tissue. The process may be chronic from the first. The wall is made up of multiplying *small round cells*, which on the side furthest from the pus contribute to the formation of *vascular fibrous tissue*, but on the exposed side undergo gradual *disintegration*, many becoming pus cells with distorted and fragmented nuclei, whilst the fluid is furnished by slow "serous" exudation. As the granulation wall thus gradually breaks down, so new cells appear and more fibrous vascular tissue is formed. In the *Chronic Mammary Abscess*, and depending upon the duration of the process, a more or less dense fibrous wall may be formed, with corresponding differences in the number of small round cells in it; at the same time there is a cell proliferation in the adjacent acini, gland nuclei sharing largely in the process.

The *tubercular abscess*.—We have seen how in the process of caseation, there is a more or less well-marked small round celled zone, which passes outside into an imperfect fibrous and vascular tissue, and inside, after preliminary changes in some of the cells, passes into a fatty necrotic mass—the caseous material. If this from admixture with fluid exudation breaks down, an abscess containing a characteristic *cheesy pus* results. In contact with the pus, there is usually a well-marked layer—the so-called "pyogenic membrane"—consisting of the granulation tissue, which is undergoing caseous transformation, and in which a faint structure and nuclei may still be seen here and there; outside it is the granulation tissue—more corpuscular next the membrane, more

fibrous away from it. Sometimes, as in large tubercular gravitation abscesses, there is a great formation of large cells, which lose their outline, and form the membrane; a few giant cells are also developed from them, and these are the last to disappear in the crumbling layer. At the same time very firm fibrous tissue may be formed outside.

Ulceration and abscess formation are alike. When chronic there is a lining of granulation tissue which undergoes slow destructive and progressive changes; when acute there is marked congestion, exudation and leucocytic migration, followed by the formation of abundant pus. In abscesses the products of disintegration and exudation are pent up, whilst in ulcers they discharge freely.

Sinus.—The wall of a sinus is like that of a chronic abscess, having a well marked lining of granulation tissue. After a time this is wont to receive a complete epithelial investment from the down-growth of the surface epithelium.

For further examples of ulcerative processes, see especially the Follicular, Tubercular and Typhoid Ulcers, under the Alimentary canal; and for chronic inflammatory processes generally, consult the separate tissue systems in which marked examples occur (Liver, Kidney, &c.).

Chapter V.

HEALING OF WOUNDS.

This chapter follows naturally upon the others, and the information gained in them, especially in the 3rd, on the "fate of the exudates and repair," must be applied to this, which includes :—

1. Healing of incised wounds by first intent.
2. Healing by granulation.
3. Healing under a scab.
4. Absorption of foreign bodies and dead non-irritant tissue as
   Sponge,
   Ligatures,
   Dead tissue.
5. The several points to be noted in the repair and degeneration of the various tissues, more especially of
   Muscle,
   Nerve,
   Bone.

Note.—It would be well if in the practical study of these processes, the tissues were fixed in Flemming's solution, and afterwards stained with safranin, in order to make out direct and indirect (mitoses) nuclear division, for which this kind of material is peculiarly well adapted.

Wound of the Fourth Day.

Fig. 23.—Healing by first intent.—A clean incised wound was made through the skin down to the

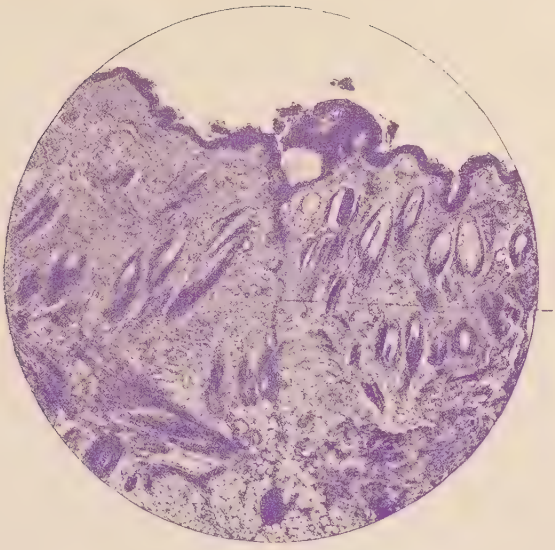

WOUND OF THE FOURTH DAY, HEALED BY FIRST INTENT

1. The line of incision.

... numerous hair bulbs in the section.

... ½ in., without eyepiece. Logwood

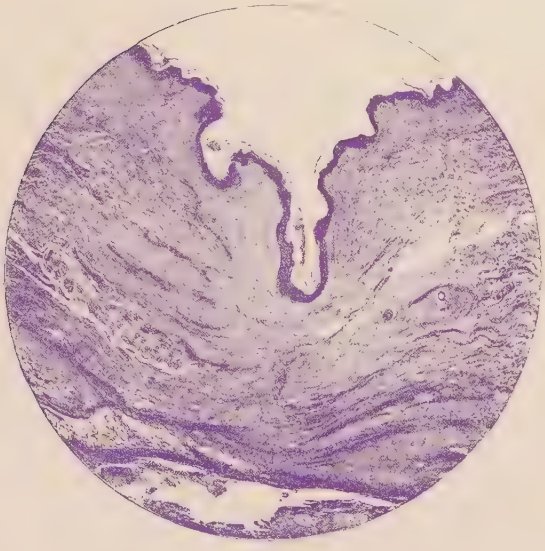

Fig. 24. WOUND OF TENTH DAY HEALED BY FIRST INTENT.

The depression on the surface marks the line of incision. At the lower part of the section, some blood-clot has fallen out

Obj. 1½ in., without eyepiece. (Logwood).

muscles, and the surfaces were brought into accurate and firm apposition by ligatures. The figure represents, under the one and a half inch, a cross section at the end of the fourth day.

A faint line (1) passing through the epidermis, dermis, and fat at the bottom of the section, marks the course of the knife, which having caused the least possible amount of injury and inflammatory reaction, has entailed a correspondingly slight amount of repair. Immediately after the infliction of the wound, a small quantity of coagulable exudate glued the surfaces together, and some oozing out above has since dried into the small wedge-shaped scab seen at the top of the incision; but there has been no marked leucocytic migration.

Examining the section with a high power, there is complete union of the epithelium, connective tissue and fat, the incision in the latter two layers being only revealed by a slight increase in the number of small round cells, and by the presence of fibroblasts, which even in this short space of time have effected a fibrous union. The numerous capillaries which have been divided have commenced to sprout, new anastomoses being subsequently formed.

Wound of Tenth Day.

Fig. 24.—This is a section under the one and a half inch objective, of a laparotomy wound of the tenth day, and but for the depression on the surface the track of the knife is no longer recognised under this power.

More highly magnified, however, new connective tissue, more delicate than the old, may be seen here and there, especially beneath the epithelium, and lower down uniting the cut surfaces of the retracted muscle. The new tissue has contracted slightly and has produced the depression on the surface, but this is never marked unless there has been considerable granulation.

In an extensive incision of this kind, larger vessels must necessarily have been cut across, and in the looser areolar tissue are several small extravasated blood clots which are undergoing organisation and pigmentary changes; in their vicinity are numerous large corpuscles which have taken up the hæmoglobin or the red corpuscles, and have elaborated a golden pigment (hæmatoidin).

If the surfaces happen not to have been brought into close contact, they are held together by a plug of coagulated exudate, in which there are numerous leucocytes, which increase in numbers, either by proliferation or fresh immigration; a few here and there become spindle-shaped, but it is doubtful whether they take a share in fibre formation; for it is at the edges of the wound where there are the fixed tissue elements that the formation of fibroblasts and capillaries is readily observed. A layer of granulation tissue is in fact formed on each side, which grows—commencing usually at the bottom of the wound, as this is the most fixed part—across the scaffolding of exudate till union is effected. Later contraction occurs, causing considerable dimpling on the surface. Amongst the numerous cell forms often present in the new tissue, may be noted macrocytes and giant cells, the latter especially in the lower animals.

Healing under a Scab.

This is a simple form of healing, which may either occur when the edges of a wound gape or after an abrasion. The exudation forms a glaze on the wounded surface, and dries into a SCAB, which may include a thin layer of tissue and various foreign bodies; orange blood pigment (hæmoglobin) is often present. It effectively protects the parts beneath, and repair is rapid, the epithelium growing in under the scab to cover the newly forming granulation tissue. Leucocytes probably help to loosen, by their phagocytic powers, the attachments of the scab to the granulation tissue, but there are no visible signs of ulceration. From the third day the changes which occur in the growing epithelium can be well studied.

Union by Granulation.

A wound very often does not (and sometimes cannot) heal by first intent, because the edges are not brought into contact. A raw surface may then be exposed to constant irritation and infection by pyogenic organisms, and as a consequence suppurates. Granulation tissue is, however, formed on the exposed surface and is ultimately covered in by the growth and extension inwards of the marginal epithelium. The new tissue may grow exuberantly, and even give rise to neoplasms, but more commonly it contracts and leaves a white scar.

The more protected and the cleaner the wound, the

less the suppuration, or there may only be a slight serous exudation.

If a considerable mass of tissue is killed on an exposed surface, it is usually thrown off as a *slough*. There is an inflammatory reaction in the living tissue in the immediate vicinity—the *line of demarcation*—and ulceration, starting immediately from the surface margin, spreads under and loosens the necrosed piece. Granulation tissue and epithelium grow and repair the loss, but considerable puckering may remain. If the amount of dead tissue is small, it may become dry and scab-like, and fall off without ulceration. Indeed, if a larger piece of dead surface tissue could be kept perfectly clean and free from irritants and infection, it would probably be absorbed and organised, like the sponge in sponge-grafting, or like small bits of non-irritant dead tissue artificially introduced into the body, or naturally produced as infarcts.

Sponge-Grafting. Absorption of Dead Tissue and Ligatures.

To facilitate the filling up of a deep wound with granulation tissue, a perfectly clean piece of sponge is often inserted to act as a framework upon which the growing fibroblasts and capillaries can develop. Organisation in this case is rapid, and by the tenth day is well advanced. If a section is made of the sponge it looks solid, and on more minute examination it is found to be infiltrated with small round cells, whilst at the periphery there are numerous fibre forming cells, and very delicate growing capillaries; macrocytes and giant cells are abundant, especially the latter, which lie in close connection with

the sponge trabeculæ, around many of which they form a multinucleated protoplasmic sheath; they call to mind the osteoclasts of bone, and are like them probably engaged in absorption, for the sponge ultimately disappears.*

Indeed, giant cells seem everywhere to take an active share in the absorption of dead tissue. They are seen investing the cut ends of degenerating muscle fibres in old wounds, as well as muscle fibres artificially introduced into the body. Typical ones have been produced by inserting hairs into the cornea. They are often to be beautifully seen surrounding thrombi in the interior of vessels, where they break down the clot and absorb the pigment. They have been met with surrounding infarcts, and apparently also engaged in the absorption of elastic fibres (Ssudakewitsch, V. A. 115), which when intussuscepted by them, give a strikingly different colour reaction or none at all. Around dead and *living* Hydatid cysts, Cysticerci and Nematodes, they appear nearly always present; their significance when associated with living animal and vegetable parasites will, however, be dwelt upon later on.

Absorption of Ligatures.—Catgut ligatures are readily absorbed by the action of phagocytes (small and giant-cell forms), which penetrate into them from the surface.

* If the green fresh water sponge, which is made up of a delicate cell structure, containing numerous chlorophyll corpuscles and silicious spicules, be used, it breaks down in a few days, without suppuration. When the débris is examined it is found to consist of the spicules, small round cells, and numerous macrocytes of various sizes; in the latter, chlorophyll grains and smaller cells are often enclosed.

Silk takes a very much longer time to disappear. At the end of two years we have seen the individual fibres of the thread stand strongly out in the granulation tissue matrix, and only a few of the fibres seemed to be attenuated. Giant cells have been described here also.

Absorption of Dead Tissue.—If dead tissue is unirritating it usually undergoes fatty changes,* and is invaded by phagocytes, fibroblasts and capillaries, which replace it by granulation tissue. If it is septic, it separates and disintegrates in an abscess cavity; but a sequestrum, surrounded by pus, does not dissolve, the latter having no effect upon it.

The following is a brief *resumé* of some of the changes (degenerative and regenerative), many of which we have already alluded to, which occur in the various cell-systems involved in a wound.

Epithelium.—Skin epithelium rapidly grows to repair loss, and many of the new rete cells may have their prickles so developed that they look like branched connective tissue corpuscles. Vacuoles are often present in the degenerating cells, and must not be mistaken for coccidia.

Pigmentation of the rete Malpighii is common in old wounds.

Connective tissue and Vessels.—Connective tissue is the great repairing medium, and by it, the divided muscle, nerve or gland, is bound together. The new tissue consists of fibroblasts, capillaries, and small round cells, and often in addition of macrocytes and giant cells, especially where absorption is going on.

How far these numerous cell forms are derived from those which pre-exist in the connective tissue, or to

* It often remains caseous for a long period, or calcifies.

what extent from leucocytes, is as before stated an open question. Probably the fibroblasts and capillaries originate from the pre-existant cells, whilst the leucocytes, macrocytes and the majority of giant cells, form a separate group, and which take no part in the formation of the fibrous vascular tissue.

The cells forming the coats of the larger vessels may be seen proliferating. If a vessel becomes plugged by a clot, the latter is organised.

Pigment deposits are nearly always present in old wounds, and the beautiful golden pigment is contained in cells (erythrophages) or free.

In small animals giant cells are more abundant in wounds than in man.

Fat.—In fat, groups of distinct granular cells of all sizes, and of amœba-like outlines, may be seen; they are very well represented in fig. 33 of Erichsen-Beck's *Surgery*, Vol. I. They are developing fat cells, though some would regard them as fat cells from which the fat has disappeared in the process of atrophy.

Muscle.—When a muscle is cut, very little change may be noted in the divided fibres. On the other hand, the cut ends may become infiltrated with leucocytes, or swell considerably and loose their striation, or split up into fibrillæ, or they may undergo rapid fatty transformation. Sometimes the ends stain intensely with logwood. Later on they may atrophy to mere shreds, or be directly absorbed, a process which appears to be effected by large multinucleated giant cells, for even small shreds of muscle fibre may sometimes be detected in their interior.

Regeneration is slight but occurs, and in the guinea pig by the fifth day, new fibres may be observed shooting away from the old, across the supporting granulation tissue. In this case the muscle nuclei divide into short chains, and the protoplasm around fibrillates longitudinally. But there may be no attempt at growth; or the nuclei and surrounding protoplasm increase, without corresponding fibrillation; the result in this case is a deformed muscle fibre which closely resembles a giant cell. The regenerative powers of unstriated fibres are probably very much greater.

Nerve Degeneration and Regeneration.—When the peripheral end of the divided sciatic of a guinea pig is examined at the end of seventy-two hours (after hardening in osmic and teasing in glycerine), a great number of the medullary sheaths and axis cylinders present a slightly moniliform appearance, and by the fifth day have broken up into fusiform, oval, globular or granular masses, staining deeply with osmic acid. The rest of the nerve sheath is occupied by a considerable quantity of very finely granular protoplasm, in which it is very difficult to make out the original nuclei, they are not proliferating, but probably do so later on. The droplets are finally absorbed by the agency of leucocytes and macrocytes (one form of Gluge's corpuscles), and still later all traces of the fibres are lost in connective tissue.

Whilst these changes are taking place, granulation tissue forms and unites the cut ends. In a short time fresh fibres begin to grow down from the central stump, and if the separation is not too great, they find their readiest way along the degenerated path; but if the

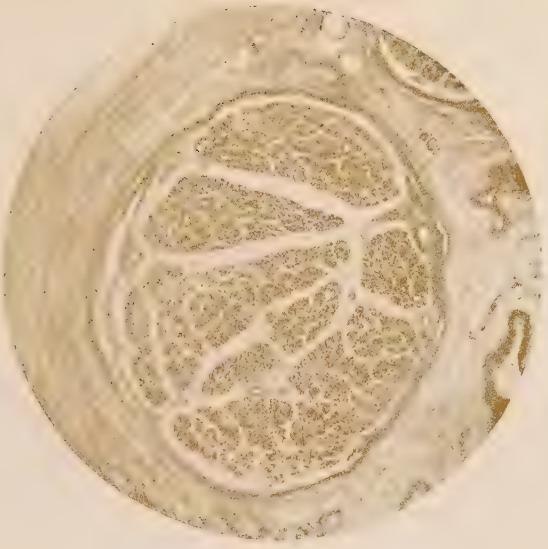

Fig. 25. MEDIAN NERVE. NORMAL.

Obj. 1½ in., without eyepiece. (Osmic acid).

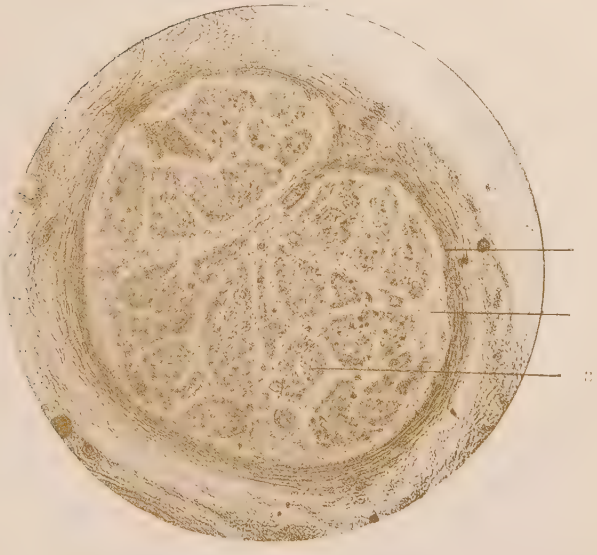

Fig. 26. ULNAR NERVE, PERIPHERAL END ONE YEAR AFTER SECTION.

1. Epineurium
2. Perineurium.
3. Endoneurium and degenerated nerve fibres.

Note the diminished osmic acid staining owing to the degeneration of the medullary sheaths.

Obj. 1½ in., without eyepiece. (Osmic acid).

intervening granulation tissue is too much owing to the retraction of the cut ends, they tend to grow round into a bulb of nerve fibres, which constitutes one of the simplest of tumours—the NEUROMA.

Figs. 25 and **26** are sections respectively of fasciculi of the *median* and *ulnar* nerves, to compare with one another, both being under a one inch objective, and stained with osmic acid. The first may be taken to represent a normal nerve, the second, an almost completely degenerate one, for only a few scattered healthy fibres remain. In the first the black nerve fibres contrast sharply with the endoneurium, whilst in the second the contrast is only just appreciable, the myeline and cylinders having been absorbed. This appearance of the degenerating end of a *divided* nerve differs from that seen in peripheral neuritis (which see) where the overgrowth of the endoneurium is very marked.

The above sections of the ulnar and median, as likewise the bulbous ending described under neuroma, **Fig. 47,** were taken from the same patient. A year previously both nerves had been accidentally divided at the wrist; ulnar sensation never returned, but curiously enough that over the distribution of the median was only partially impaired. When the upper and lower ends of both were removed with the view of suturing, the former were found to be bulbous. On microscopic examination of the lower ends, the ulnar as has been seen, had degenerated in the usual way, but the median had the healthy appearance of that seen in **Fig. 25,** only a comparatively few of the fibres being shown under the high power to have degenerated.

BONE—UNION OF FRACTURES.—When a bone is fractured there may be very little inflammatory reac-

tion at the seat of lesion and the less the speedier is the repair; abundant exudation and blood-clot only hindering the work. The regeneration is seen in its simplest form in fissures of the skull, where the edges are naturally held together. Proliferation occurs in the cancellous and periosteal tissues, in the immediate vicinity of the wound, and leads to the production of a small amount of new tissue. This differs from ordinary granulation tissue by the presence of numerous *osteoblasts*, which form upon the old bone new osseous trabeculæ which effect a union. The process is here a healing by first intent, as only a thin line of granulation tissue is formed between the opposed surfaces. Usually, however, there is considerable wounding and inflammation both at and around the seat of fracture, resulting in exudation and extravasation. In this case coagulation takes place and a temporary support is thus given to the broken ends. Cell growth soon commences in the medullary, periosteal and fibrous structures around, and organises and replaces the clot. By the tenth day the new tissue completely invests the broken ends both without and within and is termed the *provisional callus*.

Differentiation next occurs in this growing cell mass, that is to say, the **osteoblasts** in the new tissue near the shaft form bone or callus, the **fibroblasts** on the outside next the soft parts give rise to a dense tissue which becomes the fibrous layer of the periosteum, continuous with the old, and which invests the callus. In addition **chondroblasts** may produce cartilage especially when there is much movement; this material gives a firmer support and allows of subsequent ossification; sometimes the cartilage remains as the only

bond of union, and exceptionally, if the fragments cannot be kept at rest, fibrous tissue alone is formed.

The ossification (or chondrification) begins beneath the periosteum, at some little distance from the wound, and where the movement is least; it likewise takes place in the medulla, but is last to appear between the fractured ends (*definitive callus*).—

Small splinters which are detached and cut off from nourishment perish and are absorbed; the ends of the two pieces of bone also undergo partial absorption or as it is called **rarefaction,** to apparently adapt themselves for the implantation and the blending of the delicate new bone. The process is accomplished by the class of cells with which we are already familiar in granulation tissue,* namely phagocytes, but they have received the special name of **osteoclasts;** they scollop out the bone, and the depressions which they make are termed *Howship's lacunæ*.†

The spongy new bone becomes more and more dense owing to the deposit of new osseous material. Bone which is superfluous is gradually absorbed, until finally, in a well set bone, it may be very difficult to say where was the fracture.

Fig. 27.—This is a section of callus close to the seat of fracture, which was to the right of the swelling. The numbers 1, 2 and 3 point to the old shaft, 1, to the medulla, and 3, to the bone; whilst 2 indicates a large osteoclast lying in a lacuna.

Figures 4, 5 and 6 refer to the periosteum, 4 and 5

* Especially when solid tissue as sponge, muscle, &c., is to be absorbed.

† The osteoclasts are of all sizes from that of the "small round cell" to huge giant cells.

to newly forming bone in the callus, and 6 to the fibrous layer of the periosteum from which the muscle 7 arises.

The thickening of the deeper layer of the periosteum to form the callus is well seen; it grows in amount towards the side of the fracture, and on the right it tapers away. It is made up of a vascular corpuscular tissue, in which osteoblasts are very numerous; these are small slightly angular cells, around which is formed the bony substance; they leave a small space between themselves and the bone, which is bridged across by innumerable delicate protoplasmic branches. If there are chondroblasts, these lie in the cartilaginous matrix they have apparently formed. Fibroblasts occur especially near the dense layer of the periosteum, and produce the fibrous substance. Capillaries of new formation are abundant.

The structure of the medullary callus is more delicate. In the present specimen bone had not commenced to form in it, so there are no active osteoblasts as yet, but rarefaction is going on and there are very many osteoclasts of all sizes, one large one being shown in the section; they are at work on the bar of old bone (3). As often happens, however, new bone is being deposited on the other side (4) of the bar.

Fractures are wounds in which some of the most striking examples of fibrous, cartilaginous and bony hyperplasia may occur. Their possible causes of origin will be referred to under "Tumours."

Note.—It appears now well established that mitoses occur in all the cell elements engaged in the building up of the respective tissues, as for instance in the fibroblasts, endothelial cells, epithelial and gland cells and in muscle fibres. If multiplication, however,

1. Medi[illegible]
2. Oste[illegible]
3. [illegible]
4. Deposition of new bone on the surface of the [illegible]
5. Trabeculae of new bone in the calcus.
6. The newly forming fibrous layer of the periosteum.
7. Muscle fibres arising from the periosteum.

[illegible] 1½, without eyepiece.

Fig. 28. SMALL PATCH OF FATTY DEGENERATION [illegible] VENTRICULAR WALL.

1. Fatty degenerated muscular fibre.

Obj. ⅛ in., without eyepiece. Osmic acid.

takes place in these corpuscles in the direct manner, that is without the formation of mitoses, evidence tends to show that well-formed tissue elements do not result, but rather multinucleated masses or giant cells. Such at any rate seems to be the case in muscle fibres. It may here also be mentioned that according to some authorities leucocytes only divide in the direct manner.

Ranvier, *Comptes Rendus*, T. cxii., Av. 20 and 27, 1891, says, "that in incised wounds the fibrin scaffold which glues the surfaces together, is within a very short time replaced by a second living scaffolding of large anastomosing connective tissue corpuscles, which effect a firmer union. The same author describes a new cell, the *clasmatocyte*, a large cell derived from a connective tissue corpuscle, and which he believes is the source in inflammation of many of the small round cells."

Chapter VI.

DEGENERATION, INFILTRATION, PIGMENTATION AND ALLIED PROCESSES.

1. Cloudy swelling.
2. Fatty degeneration.
3. Fatty infiltration.
4. Glycogenous formation.
5. Mucin formation.
6. Colloid degeneration.
7. Hyaline changes.
8. Lardaceous degeneration.
9. Pigmentation.
10. Uratic, Guanin, Cystin and Cholesterin deposits.
11. Calcification.
12. Fat, Tyrosin, Leucin and Charcot's crystals.
13. Coagulation necrosis.

Cloudy Swelling and Fatty Degeneration.

Cloudy swelling and fatty degeneration are progressive steps in the destruction of cell protoplasm. They are present in the severer forms of inflammation, in some of the acute specific fevers, in hyperpyrexia, in poisoning by the phosphorus group and other metallic bases, also in many other cases.

1. Cloudy Swelling.*—This is one of the earliest

* This term was originally, and is still much used, as a naked eye term, to express a dull opaque condition of the parenchyma of an organ.

retrograde changes. It is described as a precipitation in the cell of minute albuminous particles, soluble in acetic acid but insoluble in ether. The nucleus is obscured, the cell is at the same time swollen and its outline ill-defined. It is to be noted that glycerine preparations bring out these changes, whilst mounting in balsam brings the specimens back to an almost normal appearance. In phosphorus poisoning the condition is very intense, and the nuclei are completely destroyed in the later stages.

Examples.

Kidney.—Tying the renal artery for twenty-four hours produces the cloudy change in the convoluted tubules, the epithelial cells of which are slightly swollen, granular and ill-defined in outline. Many of the nuclei are quite invisible, whilst others are only partially so. In many places the ducts are occluded.

Liver.—The cells are swollen and granular, and in glycerine preparations it is difficult to distinguish the nuclei.

Muscles.—The fibres of the heart are said to lose their striation, and to become finely granular. This condition is particularly seen in diphtheria, typhoid and typhus.

As a condition allied to cloudy swelling, apart from fatty degeneration, might be mentioned œdematous or dropsical degeneration. A condition in which owing to the imbibition of fluid, the cells are much swollen, sometimes even vacuolated, and the granules separated from one another; from this latter cause the nuclei are

often rendered prominent. This change may be observed in the epithelial cells of inflamed skin and mucous membranes.

2. Fatty Degeneration.—In all the following fatty changes it must be borne in mind that a previous prolonged hardening of the tissue in alcohol dissolves the fat. Hence they must be hardened in one of the non-alcoholic solutions and sections mounted in glycerine or glycerine jelly. It will be remembered that osmic acid gives a black and methyl-violet a beautiful violet reaction.

Fatty degeneration is a very common pathological process, and it has been referred to many times in the preceding chapters.

Where cloudy swelling can be seen passing into it (and this is very common in the kidney and liver where both processes occur side by side) the minute albuminous particles give place to very fine oil droplets, which may fuse into larger ones or even distend a cell with one large drop. More usually however the oil is in a finely divided state; the cells at the same time are often atrophied with occasionally a deposit of pigment in them.

Fig. 28.—Fatty Degeneration of the Heart.—This is a section of one of the small opaque pale yellow patches which occur scattered both in the substance of the heart and in the musculi papillaries, giving it its mottled, bird's-eye-maple or thrush-like appearance.

The fibres are here of normal size, nor is there any increase in the interstitial connective tissue, but they have lost their striation and are filled with minute oil globules stained black with osmic acid. (The figure has too light a colour).

Fatty Degeneration of the Liver.—Excessively marked examples of this are seen in phosphorus poisoning and in acute yellow atrophy.

A patient having died ten days after the extensive inunction of phosphorus, microscopic examination showed the liver cells reduced to mere skeletons, consisting of shrivelled nuclei and very thin walls, the rest of the cell being filled with oil.

In acute yellow atrophy, the cells are in much the same condition; they may in addition be very much atrophied and pigmented; in both, the nuclei may undergo destruction.

Fatty Degeneration of the Kidney.—Commonly this is part of a general degeneration of the kidney (then spoken of as secondary), but in phosphorus poisoning the primary form occurs. In the slower processes the renal cells enlarge, become finely granular and stain but very slightly with logwood. They disintegrate and give rise to granular and fatty casts (see "Kidney"). In phosphorus poisoning, the destruction of cells with the formation of large oil drops is very rapid.

Arcus senilis.—This is a senile change and consists in the deposition in the form of a partial or complete ring, of minute fatty particles in the cornea close to the cornea sclerotic junction just behind the anterior elastic lamina. This condition is by some described as a true fatty degeneration of the corneal corpuscles and laminæ, but others hold it to be an accumulation of fat granules deposited in the lymphatic spaces and channels, by the blood or some fat forming body in it.

Caseation, in the chapter on chronic inflammation, was demonstrated to be the transformation of tissue

into a cheesy amorphous or nearly amorphous mass, consisting of fat, albumin, cholesterin and some cell remains. It is characteristic of tuberculosis and some of the other chronic infective processes; it also occurs in many of the rapidly growing tumours, *e.g.*, sarcomata and cancers (the change here is often, however, of a more purely fatty nature).

3. Fatty Infiltration.—This is an accumulation of usually large droplets of fat in cells, and unlike fatty degeneration does not imply a destruction of protoplasm. There are two very familiar examples; one the infiltration with fat droplets of the liver cells; the other the accumulation of true adipose cells (fatty tissue overgrowth) in a special tissue such as muscle, leading to the impairment of its function and very often to the subsequent fatty degeneration or atrophy of its fibres.

Fatty Infiltration of the Liver.—**Fig. 29** is an osmic acid preparation of the liver under the 1 in. obj. It shows an accumulation of fat in the liver cells of the *portal zone*, a common situation in cases of portal obstruction. Under the high power, some of the cells are filled with small droplets, whilst others are distended with larger ones, by which their nuclei are quite flattened out. Fibrous tissue overgrowth, pigmentation and true fatty degeneration frequently accompany the above condition. Indeed to distinguish especially in the liver between fatty degeneration and fatty infiltration is very difficult, for as Cohnheim pointed out, the morphological distinction based on the size of the droplets is of course arbitrary. We can but state that an accumulation of fat takes place more especially in the portal zone, in cases of portal obstruction, in the



Fig. 29. PERILOBULAR (PORTAL) FATTY INFILTRATION OF LIVER.

1. Zone of liver cells containing large fat globules.
2. Portal vessel.

Obj. 1 in., without eyepiece. (Osmic acid.)

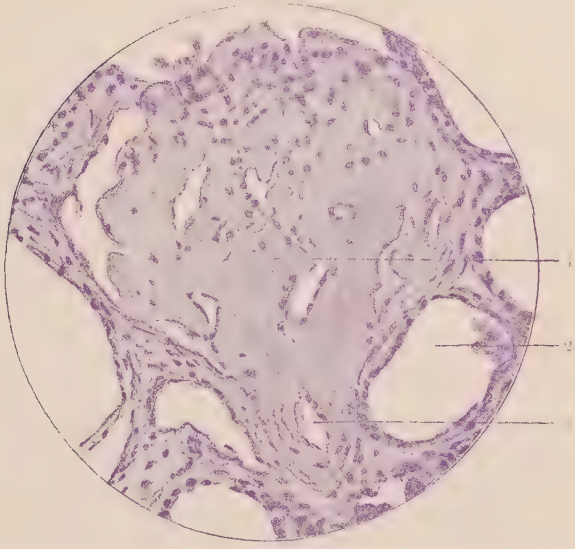

Fig. 30. LARDACEOUS DEGENERATION OF KIDNEY.

1. Glomerulus in which the lardaceous change is very manifest. Most of the capillaries are obliterated.
2. A dilated renal tube.
3. The afferent arteriole with waxy degenerated wall.

Obj. ⅛ in., with eyepiece. (Logwood.)

zone of the hepatic vein in cases of cardiac regurgitation, often uniformly distributed throughout the lobules in cachetic conditions, and irregularly in cases of tumours, lardaceous and other conditions in the liver.

Adipose Infiltration (Fatty tissue overgrowth).

a. Fatty Heart.—The subpericardial fat is usually excessive and in extreme cases the fat spreads widely into the muscle, following the lines of the perimysium. The muscle fasciculi become separated and the individual fibres usually undergo atrophy or slight fatty metamorphosis.

b. The Muscle of Pseudo-Hypertrophic Paralysis.—A section of an affected muscle shows an adipose infiltration separating the bundles of muscle fibres, the individual elements of which are markedly atrophied though preserving their striation. The nuclei in this and in other muscular paralytic affections often show a remarkable proliferation—so called atrophic proliferation. With the increase of the fat, as so often happens, there is considerable fibroid overgrowth.

4. Glycogenous Formation.—In severe diabetes hyaline formations giving with iodine the brownish-red reaction of glycogen, have been observed in the liver cells associated with a degeneration of the nuclei. A similar formation of glycogen is said to occur in the kidney in the epithelial cells of Henle's loops; further a true glycogenic degeneration of the muscle substance of the heart is described in severe forms of diabetes. It has also been observed in tumours especially in the *rhabdomyomata.*

5. Mucin Formation.—In this condition there occurs a formation of mucin in cells or more strikingly in the ground substance of the connective tissues and sar-

comas. In the latter examples the tissue is rendered soft and jelly-like, without, however, losing much of its elasticity, except in the case of cartilage. In MYXŒDEMA for example, the connective tissue bundles are separated by a thick mucin holding fluid, but the elasticity of the part is not lost as it is in œdema. There is a large group of *myxomatous tumours* and *polypi* in which there is from the beginning a formation of an abundant jelly-like substance, said to contain mucin, distributed in the areolæ of a delicate and reticulate fibrous stroma. See section of polypus, **Fig. 51.**

Mucin is insoluble in water and alcohol, soluble in lime water unless previously subjected to the prolonged action of alcohol.

6. COLLOID DEGENERATION.—This is well seen in colloid cancer of the breast and abdominal viscera. Globules of colloid substance are seen in the cells, which in advanced stages break down and are lost in an almost uniform jelly-like mass. Colloid differs from mucin in not being precipitated by acetic acid, and by undergoing considerable shrinking, but no precipitation in alcohol.

In the thyroid gland which normally contains it, such an extensive formation may occur as to constitute a goître, and in certain ovarian tumours likewise it may be present in large quantity.

7. HYALINE CHANGES.—A hyaline degeneration or change of connective tissue is very frequent and consists in the formation of a hyaline material very like amyloid, but without the reaction of the latter. Around the blood-vessels and the gland acini of many cancers, it often forms hyaline rings, and it is especially abundant in the stroma of certain *cylindromata* and *endotheliomata*.

Interesting cases are recorded in which large hyaline masses have been found scattered throughout the various tissues of the body. Thus in the alimentary tract, tumour-like swellings have been described in the mucous membrane, consisting of an extensive hyaline change surrounding for the most part the arteries ; if it penetrates the middle coat it causes extensive atrophy of the muscular fibres and the same is also strikingly the case in hyaline degeneration of the myocardium.

If muscle fibres divided in a wound be examined on about the second day, the sarcolemma will be found to be slightly distended somewhat irregularly, by a homogenous glass-like substance in place of the striated myosin. This is a form of coagulation necrosis, and when examined a few days later appears to undergo a further transformation into a fatty material.

A somewhat similar glassy change may be observed in muscle fibres in cases of exhausting febrile diseases such as typhoid, and has gained the name of ZENKER'S or GLASSY DEGENERATION.

The hyaline change is often to be observed in tubercular processes.

8. LARDACEOUS DEGENERATION.—Amyloid or lardaceous degeneration is a remarkable change, which starting in the coats of the very small vessels, leads to their complete transformation into a bulky wax-like material, and then spreading away, either involves or destroys by pressure the tissues around, until it may finally convert an organ into an almost solid mass of amyloid.

It is a condition which is closely associated with *chronic suppuration*, whether of bone, lung, kidney or other structure, and hence it is found in Tubercle,

Leprosy, Syphilis and Actinomycosis; but apart from suppuration, it occurs often in cachectic conditions, and is met with as a *local process*, in the form of small isolated specks—the CORPORA AMYLACEA—in scars, in old thrombi, in the brain and spinal cord, and in the prostate. The local formation is also sometimes observed in the conjunctiva.

It gives some very *distinctive reactions*, of which that with a solution of IODINE, or iodine in potassic iodide, is familiar in the post-mortem room, changing the glistening masses to a rich brown mahogany, the normal tissue staining a light yellow only. But when this method is used for a microscopic section, which is then viewed by transmitted light, the colour appears much redder. Dilute METHYL VIOLET, or even common purple ink, imparts to the waxy material a beautiful *pink*, markedly contrasting with the blue of the unaffected tissue around. In order to still further heighten the contrast, after staining, carefully wash in dilute acetic acid. Methyl green and gentian violet likewise give colour reactions. IODINE AND SULPHURIC ACID give a blue, but this test is so uncertain that it is rarely used; it is interesting because it suggested to Virchow the name *amyloid*, since cellulose stains similarly with the same reagents. Sections treated with the above dyes must not be mounted in Canada balsam; but extremely good results may be obtained with ordinary logwood and mounting in balsam, and it is advisable always to prepare in both ways. Ehrlich's hæmatoxylene gives the greatest differential effect, for the lardaceous substance is only just tinted blue, whilst the unaffected tissue stains the usual depth.

The SPLEEN, LIVER and KIDNEYS, and in a less

degree, the INTESTINAL MUCOUS MEMBRANE and the LYMPHATIC GLANDS, are the *seats of election*, but the change has been described in nearly all parts of the body. Sometimes it is the liver, at other times the kidney or spleen, which is most affected, or the change may be equally distributed amongst all three.

EXAMPLES.

Fig. 30.—KIDNEY.—This figure shows a glomerulus and a few adjacent renal tubes. At 3 the afferent arteriole is seen in section, its lumen is preserved and it is lined by *unaltered endothelium, for this appears to be the last part of a vessel to be affected;* outside this the coats of the arteriole and the fibrous investment of the glomerular capillaries (with perhaps the endothelial cells) have become transformed and swollen into the waxy material, 1. The majority of the capillaries have become impervious, but the epithelial reflection from the capsule remains, except at those places where the glomerulus has fused with the renal tissue around. 2 points to one of the dilated renal tubes, which is lined by a flattened cubical epithelium. In the pyramidal portion of the section (not shown), the numerous straight arterioles were deeply affected, being converted into veritable wax-like cylinders; and indeed, it is in this position that the change is sometimes most marked.

The lardaceous degeneration is always accompanied by other marked structural changes, interstitial or parenchymatous, one usually being in excess of the other. In the large waxy kidney, which is figured, the parenchymatous condition obtains, the tubules are

greatly dilated, and are lined in some places by flattened epithelium, in others by cells undergoing fatty degeneration and disintegration. Many contain HYALINE CASTS, giving a reaction with methyl violet, halfway between lardaceous and untransformed material. At other times the interstitial changes are more advanced, and there is a large overgrowth of fibrous tissue, with at the same time atrophy, dilatation and fatty degeneration of the tubes. Many of these become cystic and filled with a colloid material. Many glomeruli are fibroid.

Fig. 31.—LIVER.—This section shows under a low power, the extensive distribution of the disease in advanced cases. It is stained with methyl violet, so that the amyloid is pink and the unaltered liver substance blue.

With the high power, the lobules are seen to be composed of thick streaks and blocks of the waxy material, between which, and much compressed, lie degenerate liver cells; the latter are more numerous in the portal zone, and all contain fat globules, which are rendered a conspicuous violet blue by having absorbed this particular aniline dye. The change first appears around the hepatic arterioles and capillaries, so that in the early stage it occupies roughly a zone intermediate between that of the portal and hepatic veins; from the vessels it spreads into the fibrous tissue around where the increase of bulk causes compression and degeneration of the liver cells; here and there, however, groups of liver cells appear to become soaked in or transformed into the lardaceous substance.

Fig. 32.—SPLEEN.—A section of a "SAGO SPLEEN" under a low power. The MALPIGHIAN CORPUSCLES have undergone the degeneration, and are almost structure-

31. LARDACEOUS DEGENERATION OF LIVER

[illegible] lardaceous material. The purple-blue fatty liver cells

[illegible] 1 in. without eyepiece [illegible] methyl violet [illegible]

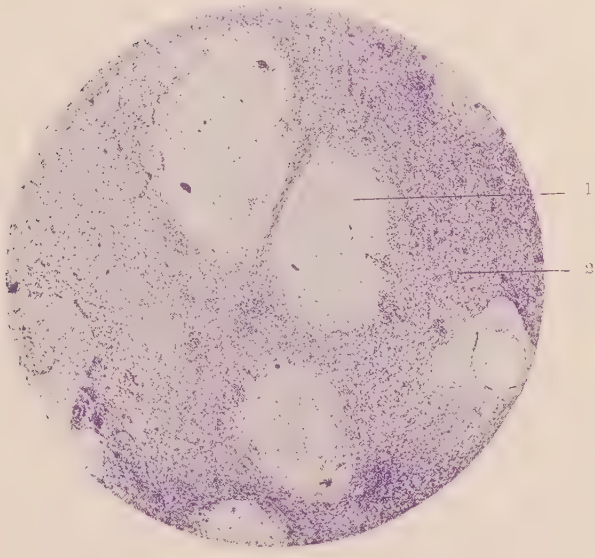

Fig 32. LARDACEOUS SPLEEN. SAGO SPLEEN

1. Lardaceous lymphoid nodule.
2. Splenic pulp.

Obj. 1 in., without eyepiece. (Logwood).

less and glistening, hence they strongly resemble translucent grains of boiled sago—whence the name.

In this form the change commences in the walls of the capillary meshwork of the lymphoid follicle and probably both involves and causes pressure atrophy of the lymphoid cells. The central artery, together with a small amount of tissue around, remains for a long time unaffected. Scattered about in the pulp are minute lardaceous vessels.

There is also a *diffuse* form, in which the sinuses, trabeculæ, capillaries and arterioles of the *pulp*, first undergo the change. There are, however, all transition stages between the two forms.

Lymphatic glands and Alimentary tract.—In these also the change commences in the minute vessels. In the alimentary canal the degeneration may be readily observed in the looped vessels of the villi.

Corpora Amylacea.—It is of interest to note that many of these bodies, previously referred to, possess, more especially when newly formed, the property of *striking blue with iodine* and of forming sugar on salivary digestion. For such the name of amylum bodies is more appropriate.

9. Pigmentation.—Under this term are included several widely different processes, viz :—

Tattooing.

Dust inhalation deposits.

Argyria.

Blood pigments.

Bile pigments.

Melanin.

Tattooing.—In tattooing insoluble foreign particles such as cinnabar or charcoal are pricked into the sub-

epithelial connective tissue where they are taken up by connective tissue and wandering corpuscles. A considerable amount of pigment may be conveyed to the nearest lymphatic glands, in fact its presence in them may be the only evidence of a former tattooing.

Dust Inhalation.—In dust inhalation a deposit of soot, stone, metallic or other particles occurs in the lungs and bronchial glands, occasionally also in the spleen. In dust inhalation experiments (Arnold's especially), a very rapid accumulation of the foreign material takes place beneath the pleura, in the interlobular septa and around the bronchi, so rapid indeed as to suggest a direct passage of the particles into the lymph stream. But dust particles, as has already been hinted, are also seized upon by leucocytes and macrocytes. These dust-containing cells are always to be found in numbers in the alveoli, in the interlobular septa, beneath the pleura and around the bronchi; they are of all sizes, from that of a leucocyte to that of a very large giant cell. After a time the protoplasm and nuclei usually disappear leaving the pigment free in the connective tissue. Examples of the deposition of inhaled particles are met with in stone masons', knife grinders', metal workers' and coal miners' lungs*; in the latter case—

* Dr. Coats has drawn attention to the fact that years after a coal miner has ceased working in a pit, he may when subject to a catarrh, have a black expectoration—the so-called *black spit*—the agents in the return of the pigment being probably the leucocytes.

N.B.—Besides anthracosis the terms *silicosis* and *siderosis* are used to designate stone and iron dust accumulations in the lung. Siderosis might however be used for iron deposits in other tissues, as in the liver, and which are due to other pathological causes.

anthracosis—owing to the intensity of the black pigment, the distribution of the coal-dust in the lymphatics can be accurately traced. Generally in the lungs of town-dwellers considerable deposits of carbon are to be found in the previously mentioned situations, but especially so in chronic inflammatory conditions such as around bronchi in chronic bronchitis and in the deeper layers of the pleura in thickened pleura. The presence of the foreign material predisposes to connective tissue overgrowth so that a fibroid condition of the lung and lymphatic glands is usually present. In addition to the microscopic demonstration of the inhaled matter both a chemical, qualitative, and quantitative analysis may be made.

In Argyria, owing to the absorption of silver salts by the *alimentary canal*, a most interesting pigmentation takes place, differing considerably from the above cited examples. The process consists in the deposition of minute black granules of some silver salt in the ground substance of the connective tissue. In the alimentary canal it occurs in the mucous membrane, especially around the walls of the lymphatics; in the liver in the connective tissue around the portal veins. Klebs (Allgemeine Pathologie) figures a case in which the glomeruli were converted into *black masses*, and a dark zone existed between the cortex and medulla, with radii extending along the straight tubes. Pigmentation in the sub-epithelial tissue of the skin likewise occurs.

Blood Pigments.—There are several forms of pigment which owe their origin to the red corpuscles, and which can be readily demonstrated in and around blood clots, and in glandular organs, such as the liver and kidney, which are concerned in the formation and excretion of pigment.

1. *Changes in Blood Clot.*—The red discs may fuse together into coloured masses, and subsequently undergoing disintegration form rich *brown granules*, or beautiful *ruby coloured crystals* of hæmatoidin.*

The hæmaglobin may diffuse out, leaving transparent discs behind, and collect into large deep red crystalline masses—the latter probably owing to the action of the alcohol in hardening. Or the hæmoglobin may be absorbed by the wandering and other cells around, which convert it into golden coloured hæmatoidin. The corpuscles themselves may be intussuscepted by these same cells, which are looked upon as phagocytes and have received the name of *Erythrophages* (Langhans). They are almost always to be found after the tenth day (often before), and are very conspicuous on account of their golden or brown colour and large size;† they lie both scattered around the clot and in the lymphatic channels leading away from it, and will often be met with in the nearest glands.

In brown induration of the lung, which is due to venous congestion, and in which there is some slight escape of blood discs into the alveoli, there are numerous corpuscles which contain brown pigment.

As in the case of the carbon cells, the protoplasm and nuclei may disappear, leaving the granules of pigment free.

Methæmoglobin crystals are sometimes found in ovarian fluids.

* The crystals may often be found in abundance at the site of the placenta, and in the retained extra-uterine fœtus. With H_2SO_4 they give a blue-green reaction.

† Reference has already been made to the absorption of blood clot by large giant cells.

2. *Changes in the Liver.*—Pigmentation may occur in the liver cells and in corpuscles free in the venous capillaries. The common example of the latter is the chronic congested or "nutmeg" liver, where numerous large cells, the GOLDEN CORPUSCLES, are to be met with in the dilated, mesh-like capillary system of the hepatic vein; they contain a bright yellow granular pigment and often enclose one or more red corpuscles.

Well-marked examples of cell pigmentation are seen in those cases, as *typhus*, *malaria* and *pernicious anæmia*, in which there is an abnormal destruction of blood discs in the circulation, and where the liver cells, owing to degenerative changes, are unable to deal with the consequent increase of hæmoglobin. The latter is decomposed by the cells, and a portion, like hæmatoidin free from iron, finds its way into the circulation, and is subsequently found in the urine as urobilin; whilst the iron-containing residue, instead of being excreted, collects in the cells, just as the fat drops do in fatty infiltration; and indeed, it is usual to find fat drops as well as ferruginous pigment in the same lobule.

EXAMPLES.

Fig. 33.—THE LIVER IN PERNICIOUS ANÆMIA.—A deposit of brown granules, consisting in great part of ferric oxide, in the portal zone of the lobules, is most characteristic of pernicious anæmia; sometimes the whole lobule is affected, more usually it is only the outer two-thirds, the inner being often infiltrated with fat. The pigment may be accurately demonstrated by the application of one of the familiar iron tests. The

figure, for example, represents a section which has been passed from potassic ferrocyanide into dilute hydrochloric acid, and the result has been that the granules have assumed a Prussian blue colour, and are seen to form an actual network, most marked in the vicinity of the portal vessels. Other reagents might be employed, such as potassic sulpho-cyanide, which gives a red, and ammonic sulphide, which gives a black colouration. In the same disease the granules have been shown in the convoluted tubules of the kidney.

MELANÆMIA.—This is one of the most marked changes in Malaria. In the BLOOD dark pigment granules occur, both free and in the white corpuscles. The capillaries of the brain, of the liver, and of the glomeruli may be so loaded with pigment as to appear almost black. The pigment which is said to give a Prussian blue reaction is probably derived from the destruction of the hæmoglobin of the red corpuscles, perhaps in the case of Malaria, through the agency of the Hæmatomonas. In the cells of the *liver* and *spleen* the pigmentation may be very great; in the latter organ the granules occur in the lymphoid cells and in larger often multinucleated cells. In the kidney the tubules may contain pigment; and the *brain* may appear as if rubbed with black lead.

BILE PIGMENTATION.—Apart from the diffuse pigmentation which the colouring matter of the bile gives rise to, yellow granules as well as ruby-red rhombic crystals are sometimes observed in the liver cells, uriniferous tubules and other tissues. In the kidney of the newly born, so great may be the deposit of golden glistening crystals in the tubes of the papillæ that a *bilirubin infarct* is spoken of. Gmelin's test, fuming

33. PIGMENTATION OF LIVER, PERNICIOUS ANÆMIA.

[illegible] granules, here converted into Prussian blue granules [illegible] and HCl, are [illegible] the li[illegible]

[illegible]

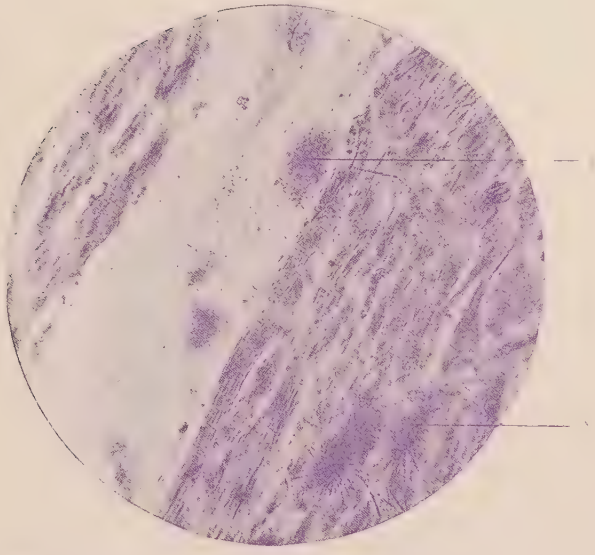

Fig. [illegible]. SMALL PORTION OF A BACK MUSCLE, SHOWING DEPOSITS OF URATE OF SODA CRYSTALS (1 & 2) IN THE INTERMUSCULAR CONNECTIVE TISSUE

From a case of well marked gout.

Obj. $\frac{1}{4}$ in., without eyepiece. (Legwood).

nitric acid, which gives a play of colours may be used to identify the crystals.

Melanin.—Dark brown granules of melanin are characteristic of a class of very important cutaneous sarcomata—the *melanotic sarcomata*, and it is worthy of note that in the metastases of these tumours the power of pigment formation may *increase* or *decrease*. Melanin is also found giving rise to scattered black patches in the skin; it is present in many cutaneous moles, warts, papillomata and in some of the cutaneous epitheliomata. Its formation in dermoid cysts—not uncommon—is of the highest interest.* In granulation tissue, and granulation tissue hyperplasia of the eye region, the same pigmentation is to be noted (compare sarcomata). Pigmentation occurs in the prolapsed cervix uteri of the negress. In all these cases the granules are found in the connective tissue elements and in the covering epithelial cells.

In *Addison's disease* there is a formation of dark brown pigment in the deepest layers of the rete Malpighii, as well as in many of the cells in the connective tissue beneath, some of which are said to send pigmented processes between the rete cells. Some maintain that the pigment is brought to the epithelial cells by wandering cells.

Brown atrophy of the Heart.—This condition affords an example of the formation of pigment granules in muscle fibres. Atrophic changes usually accompany the pigmentation.

* In the true pigmented "black tongue" brown granules containing iron are found; and it is perhaps worthy of note that Paget has recorded a pigmented dermoid of the tongue.

10. Uratic, Guanin, Cystin and Cholesterin deposits.—In *gout* in man, and in guanin gout in pigs the deposition of crystalline salts may be observed. In gout the common seat of the urate of soda is the cartilage of the joints and the synovial and fibroid structures around them and the cartilage of the ear. The next most frequent place is the kidney; its occurrence elsewhere is rare, though the illustration **Fig. 34** happens to be a section of part of a dorsal muscle in which deposition had taken place. It will be seen that the urate of soda has crystallised out in its typical form of bunches of acicular crystals, and has been deposited chiefly if not entirely in the interstitial tissue. Though not shown in the figure, the muscle was extensively infiltrated with fat cells and in some of the septa the fat and crystals occurred side by side.

Gouty cartilage.—If a section is made of a fresh piece of chalky articular cartilage, not too far advanced, a line of urates will be seen close under the surface. They are either crystalline or nearly amorphous in form and occur both in the matrix and the cells. Deeper down where the crystals are less numerous acicular bunches may be met with. On removing the deposit by soaking in warm water or dilute caustic alkali, the structure of the cartilage appears little altered.

In the *kidney* the deposit occurs both in the interstitial tissue and tubes of the cortex and pyramids, and without there being necessarily any fibroid overgrowth in the kidney. When a section is stained with logwood, the urate of soda which is mostly in the form of an amorphous crystalline mass, appears to have some affinity for the stain; this reaction is, however, not to be laid stress upon.

Apart from gout there may appear an extensive deposit of urate in the collecting tubules of the kidney in the newly born, which has been named the *uric acid infarct* of the new born.

Reactions.—It is often necessary to decide whether certain crystals or deposits in a tissue are urate of soda or not. Urate of soda occurs as seen above in the form of separate needles or stellate aggregates or in semi-amorphous masses. These are soluble in caustic potash. Amorphous deposits may be extracted with hot water and evaporated when the characteristic needles are formed; or if acetic acid be first added *uric acid crystals* may be obtained. The extract with the addition of a few drops of nitric acid, evaporated to dryness, gives on the addition of a drop of ammonia, the purple murexide reaction.

Guanin.—In "guanin gout" bundles of acicular crystals are deposited in the various tissues as in gout; this is of interest when it is remembered that guanin is an earlier nitrogenous product of metabolism than uric acid, and that it is probably an antecedent of the latter.*

Cystin.—Cystin in the form of yellowish transparent concretions is something found in the uriniferous tubules. The crystals are readily identified by their regular hexagonal shape.

Cholesterin.—The characteristic rhombic plates of

* *To test.*—Extract with a few drops of HNO_3 and evaporate to dryness in a porcelain capsule; cool, add a drop of caustic soda and an orange-colour develops which gives place to *purple on heating*, and this is especially well seen when the vapour is blown on to the warm sides of the capsule (Hoppe-Seyler, Ewald and Krukenberg).

cholesterin with notched angles are very common amongst fatty debris, as for instance in the atheromatous contents of dermoid, sebaceous and other cysts, and in the atheromatous patches of degenerated vessels. With sulphuric acid it gives a variety of colours such as orange and pink, whilst with iodine and H_2SO_4 a light blue.

11. Calcification.—This is an extremely common process in one form or another, and consists in the deposition in dying or dead tissue of calcareous salts, chiefly the phosphates, less commonly the carbonate, still less so the oxalate. They occur usually in the form of minute granules, although the oxalate may under other conditions, as when present in renal cysts, crystallise out. On dissolving away the deposit by dilute mineral acids the original structure of the part appears.

It has been long known that mercury poisoning in the lower animals (more especially perhaps in the herbivora), and occasionally in man, is associated with a deposition of calcium salts both in the renal epithelium and lumina of the straight tubes more especially of the cortex. The amount present may be slight or so excessive as to obscure all structure until dissolved away. The epithelium usually shows cloudy and necrotic changes and thus the deposition of the calcium is accounted for. Mercury is, however, not the only agent which produces these changes, as many other poisons and even tying the renal artery may do the same; oxalic acid in toxic doses gives rise to an oxalate deposit. Apart from the above causes the glomeruli may calcify and the renal epithelium may become encrusted with salts deposited from the urine, and

indeed in such abundance in the pyramids as to constitute sometimes the so-called *calcareous infarct.*

There are much more familiar examples of calcification than those just mentioned. Thus, it is extremely common in the herbivora for Tubercular, Actinomycotic and Zooparasitical granulomata to calcify in the early stages. This is probably owing to the larger amount of calcium salts circulating normally in their blood. It is interesting to note in man when a similar state obtains owing to caries or bone atrophy, that there is a marked proneness to calcification, or as it has been termed, to the formation of *lime metastases* (Virchow).

As a *senile* change it is familiar in the *arteries* in two forms; 1, in the atheromatous plaques of the larger arteries and left cardiac valves, where the calcium is deposited in the deeper layers of the intima and adjacent portion of the media (ramifications of the vasa); and 2, as minute calcareous rings in the muscular coat of the smaller arteries, such as the radial, a condition which may so far advance as to convert the media into a rigid tissue.

Some tissues are naturally predisposed to calcify with advancing age and then to undergo ossification, such as for example, cartilage. Calcification followed by ossification is also often met with in arteries and in the coats of the eye.*

Dead tissue is wont to become permeated or incrusted with calcium salts. For example, thrombi (phleboliths), infarcts, fibrinous deposits (notably in the pericardium and pleura), walls of sinuses and chronic

* The formation of cartilage and bone is natural in the eyes of some animals.

abscesses, the extra-uterine fœtus (lithopædion). Incrustations are met with in the urinary, salivary and bile ducts, and calcareous stones may be formed in these situations as well as in the tonsillar crypts (tonsillar stones) and beneath the prepuce. *Parasites* very often calcify, viz., Hydatids, Cysticerci, Pentastomata, and Trichinæ; the latter may retain their vitality long after their capsules have calcified.

Reactions.—Calcareous material dissolves with effervescence in dilute hydrochloric acid. Hæmatoxylin stains the carbonate and phosphate, but the oxalate and uric acid are said to remain uncoloured.

12. Fat, tyrosin, leucin, and Charcot's crystals. —These crystals are formed for the most part as the result of post-mortem changes.

i. *Fat crystals* occur in well marked separate needles or sheafs. They are insoluble in water but soluble in alcohol, both of which reactions distinguish them from tyrosin sheafs to which they have some resemblance.

ii. *Tyrosin* occurs also in the form of sheafs of delicately fine needles, and may often be obtained from the scrapings of the cut surface of the liver and spleen of patients who have died of septicæmia or high fever. The scrapings may be mounted directly, or the tissue extracted with hot water and the extract evaporated and allowed to crystallise.

iii. *Leucin* in the form of spheres may be encountered in the spleen and thymus.

iv. *Charcot's crystals.*—The nature of these is not accurately known. They are found in the form of minute colourless octahedra in the spleen, bone, marrow, and blood of Leukæmic patients, but not solely in Leu-

kæmia. Mount directly scrapings or a specimen of blood.

13. Coagulation Necrosis.—Typical examples of coagulative necrosis are seen in diphtheritic conditions of mucous membranes or of granulating surfaces. An intense inflammatory process rapidly leads to the formation of a tenacious or stiffened mass of dead tissue which can often be peeled off in the form of a distinct membrane. The necrotic mass consists both of the coagulated tissue elements and of the coagulated exudation from the vessels. The fibrin may be in the form of a network enclosing tissue and blood corpuscles, or all may be reduced to a firm granular mass. The vessels and lymphatics where recognisable contain thready or granular fibrinous coagula. The tissue corpuscles and leucocytes, when not reduced to a granular débris, often appear to have undergone but little change, seeming as it were to have been fixed, but they are with difficulty stained by logwood. So common is a disappearance or fading of their nuclei that this is regarded by some as characteristic. In coagulative necrosis the cells show no signs of fatty or other progressive degeneration, for which in fact there has been no time. The process also differs from that form of necrosis termed *necrobiosis*, which may often be observed in the centre of a rapidly growing sarcoma, in the croupous deposits in the pulmonary alveoli, in an aseptic infarct, &c., where the destruction is of a more progressive character and is therefore regarded as a vital process.

Chapter VII.

THE INFECTIVE PROCESSES.

There exists a very large group of diseases in the great majority of which the symptoms and tissue reactions have been shown to be due to the presence and growth of specific organisms. In each case in which these relations have not yet been actually proved, we still suspect, reasoning from analogy, a "living contagion" which only awaits more perfect methods of manipulation in order that it may be satisfactorily demonstrated.

The vegetable parasites furnish the largest number of exciting agents, and include very many species of *bacteria* with but a few examples of the budding and hyphal fungi. The animal parasites hold a less prominent position, though their importance is coming more to the front; only those of them, however, will be described in the present chapter which closely resemble and throw light upon the mycotic affections, the rest being reserved for a later chapter.

In the growth of the organism in the body the anatomical reactions which may be called forth by the increase of the virus may be very slight indeed (though the clinical symptoms may be very pronounced), and practically confined to the presence of the micro-organism in the blood or in the blood cells. Much more frequently, however, there are well-marked *inflammatory reactions* which, according to the virulence and distribution of the organisms, are more or less acute or

chronic, localised or diffuse. By reason of the latter, a rough grouping of the infective diseases is possible which fairly accords with the anatomical appearances. Thus they may be divided into acute and chronic, and each of these again into those which tend to run a local course and those which tend to generalise. But it must be well understood that between these groups there are all transition stages, and that often a locally infective process gives rise to general infection.

Commencing with the acute diseases* the following is the order adopted, beginning with the locally infective processes.

Soft chancre.
Cutaneous erysipelas.
Phlegmonous erysipelas.
Wound diphtheria.
Sloughing phagedæna, noma, and hospital gangrene.
Spreading traumatic gangrene.

Diphtheria.
Pneumonia.
Typhoid.
Cholera.

Pyæmic affections.
Glanders.

Anthrax.
Relapsing fever.
Malaria.

* The accompanying list is of course not complete, a selection has simply been made of a few which may serve as general types. Elsewhere in the text, the small-pox pustule, the cord in hydrophobia, &c., will be figured. But for an account of the very numerous infective diseases in man and animals, the reader is strongly recommended to seek a special treatise on the infective diseases or on bacteriology.

Chronic infective processes :—

Tuberculosis (and pseudo-tuberculosis).
Lupus.
Leprosy.
Actinomycosis.
Zooparasitical granulomata.
Syphilis.

Examples of lesions produced by some of the higher fungi :—

Thrush.
Favus.
Tinea.
Pityriasis versicolor.
Aspergillar affections.

Acute local infective processes.—In these affections probably specific micro-organisms excite at the place of inoculation an intense *locally spreading inflammation*, and lead according to their virulence and properties to serous and leucocytic exudation, suppuration, formation of membrane, sloughing or spreading gangrene. Only a few words of description are needed here, however, since the changes met with have for the most part been described in the chapter on acute inflammation.

Soft chancre.—The soft chancre is an example of an acute ulcer. The epidermis, with perhaps the exception of the deeper processes, becomes infiltrated and destroyed, exposing a raw ulcerating surface. The tissue around is œdematous, and the whole structure is soft, contrasting with the syphilitic or hard sore which will be described amongst the chronic infective processes. The virus has not been isolated.

Phlegmonous erysipelas.—**Fig. 35,** which has been dis-

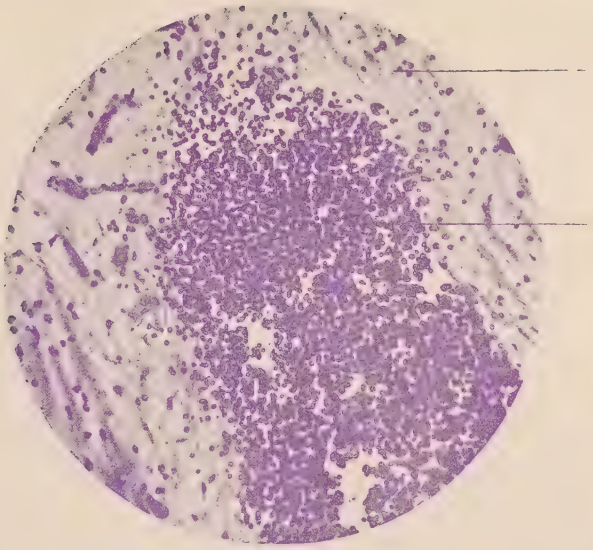

Fig. 35. COMMENCING ABSCESS FORMATION IN AREOLAR TISSUE

1. The œdematous areolar tissue
2. Focus of leucocytes.

Obj. $\frac{1}{4}$ in., without eyepiece. (Logwood).

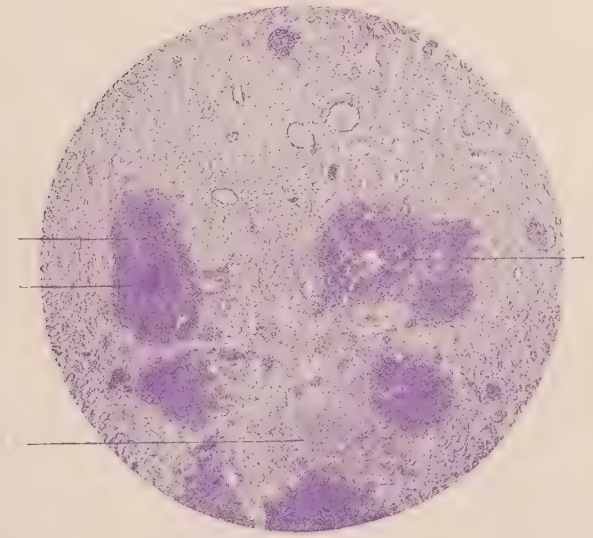

Fig. 36. KIDNEY FROM A CASE OF ULCERATIVE ENDOCARDITIS

Throughout the kidney are scattered numerous leucocytic foci (1, 4, etc.), in the centre of which a more deeply stained part 2 can be distinguished. The latter is the micrococcal embolus

Obj. 1 in., without eyepiece. (Logwood)

cussed before in Chapter II., shows a small centre of leucocytes, such a collection being highly characteristic of an inflammation excited by micro-organisms. There were numerous other foci scattered about the congested and œdematous tissue, some of which had fused and were breaking down into pus. A cover-slip preparation of the latter, stained with gentian-violet and partly decolourised in spirit, showed numerous chains of Streptococci.

Cutaneous erysipelas.—In this the local affection is milder, but the general symptoms may be very severe. There is some œdema of the skin and even vesicles may be formed. The congested tissue is infiltrated with leucocytes especially massed around the lymphatics and at the margin of the inflammation, where the Streptococci are found. Suppuration or abscess formation is rare. To demonstrate the organism which appears closely allied to, if not identical with, Streptococcus pyogenes, sections should be treated by the method of Gram.

Wound Diphtheria.—In a section through the wound, the healthy granulation tissue, consisting of the usual delicate capillaries, fibroblasts and small round cells, is found to pass at the affected spot into a well defined membrane. The latter is made up of a coagulated layer of granulation tissue, fibrin and leucocytes. Streptococcus pyogenes is nearly always to be found.

In *Noma* and *Hospital gangrene* or *sloughing Phagedæna*, the latter of which is described under fig. 15, a zone of leucocytes usually plainly marks the edge of the advancing gangrene. In noma bacilli, and in hospital gangrene streptococci have been regarded as pathogenic.

Spreading traumatic gangrene.—This is an intense spreading inflammation, which rapidly passes through the stages of congestion, serous, fibrinous and corpuscular exudation, to thrombosis and gangrene with the development of gases. So rapid is the inflammation and the effusion of serum, that the cuticle may be raised into vesicles and bullæ as in a burn. Characteristic rod-shaped bacteria in addition to others have been found.

Diphtheria, Pneumonia, Typhoid and Cholera may be next taken together. In these affections pronounced tissue changes are produced by specific micro-organisms in certain special seats of election as the mucous membrane of the pharynx, trachea and intestine, Peyer's patches, &c. The absorption of the products elaborated by these micro-organisms produces in certain cases, notably in diphtheria and in cholera, marked toxic symptoms; these are analogous to those which occur in *septic intoxication* or *sapræmia* and which are due to the absorption of septic products from foul and gangrenous surfaces. A striking sign of the sapræmic condition, is an intense *inflammation of the alimentary tract* precisely like that seen in mercury poisoning. Similarly in pneumonia, typhoid, diphtheria and cholera there are certain general parenchymatous changes which must be referred to the pyrexia and to the other derangements occasioned by the toxæmia. Such changes are the acute fatty degenerations which occur notably in the liver and kidneys and in the heart, especially in Diphtheria; the changes in the red blood corpuscles and vessel-walls leading to extravasations and staining, and perhaps to thrombosis; and the vitreous degeneration of muscle, early noticed by

*Z*enker in typhoid. These, together with other less marked changes, are not peculiar to the above affections, but are rather the rough anatomical evidences of any severe *fever*.

Diphtheria.—Under acute inflammation and coagulation necrosis, references to the anatomical appearances will be found. The exciting agent is very probably Löffler's bacillus, which is found beneath the membrane and thus differs from the streptococci and other organisms which may be encountered in the necrotic mass and which may be looked upon as accidental. The bacillus may be stained with Löffler's *alkaline methylene blue* solution (alcoholic solution of methylene blue, 30 c.c., solution of potash 1 in 10,000, 100 c.c.). After a short stay in this, the sections are decolourised rapidly in a very weak, ½ per cent., solution of acetic acid, and mounted.

Hæmorrhages in the lungs and kidneys, an acute fatty degeneration of the heart muscle, and of the glandular organs, and a pronounced nephritis form part of the general anatomical changes.

Pneumonia.—The acute changes which may be met with in the lung have already been described and illustrated in Chapter II. The virus is now usually considered as being Fränkel's bacillus, which closely resembles Friedländer's pneumococcus.

Typhoid.—The virus is a bacillus which can be demonstrated in Peyer's patches, mesenteric glands, spleen and liver. It may be stained with alkaline methylene blue or gentian violet, but by Gram's method it is decolourised. The early swollen or "mushroom" like appearance of Peyer's patches, followed afterwards by the well-known ulcers, will be figured under the

alimentary system. The mesenteric glands and spleen are swollen.

Cholera.—In this mycotic affection the mucous membrane of the intestine appears merely swollen and red, and there is an abundant watery discharge. If however the fever is prolonged, ulceration is excited by the presence of specific microbes. Cover-slip preparations or "flakes" of mucous membrane may be stained with warmed alkaline methylene blue.

Pyæmic Processes.—These processes are characterised by "the dissemination throughout the body, by the blood stream, of a pyogenic virus derived from a local centre of suppuration" (Marcus Beck). The staphylococci and streptococci are the common pyogenic organisms, and are found singly or together in suppurating wounds and abscesses. Their mode of entry is in many cases not clear, but it is probable that injured tissues are more liable to infection; this is for instance assumed in the case of ulcerative endocarditis, infective periostitis and osteomyelitis, and in other cases where, without the presence of an external wound, these parts appear to be the primary seats of suppuration. From these sources, and from suppurating wounds generally, dissemination may occur. The secondary foci, which are often numerous, are produced by embolism, *i.e.*, by the impaction of micro-organisms or portions of infected blood-clot, or tissue carried by the blood stream from the primary focus. The secondary foci may have the form of minute miliary nodules occurring in any part of the body, or of larger conical lesions—*infarcts*—found only in the periphery of certain viscera. In both cases suppuration usually occurs. The joints and serous cavities are frequent seats of secondary foci of suppuration.

Fig. 36 is a section of the kidney of a patient who died of ulcerative endocarditis, the diseased valves being covered with micrococci. There were several infarcts in the spleen, and the kidneys were dotted all over with miliary foci of inflammation, closely resembling tubercles ; some of these are indicated in this low power illustration. No. 1 points to one such group consisting of migrated leucocytes, which stain deeply and therefore offer a sharp contrast to the kidney substance around. In the midst of the corpuscles there is a darker patch (2) formed of a large colony of cocci, probably of the staphyloccus pyogenes. They have become detached from the parent growth on the valves and arrested in a small capillary, where they have multiplied and have excited intense local inflammatory reaction. Some of these leucocytic foci are already breaking down into pus, as at (4), where a small cavity has actually formed ; and they are each surrounded by a zone of extreme congestion, with in places actual extravasations. The renal epithelium too, in the immediate neighbourhood, is profoundly changed, the cells being swollen, vacuolated and disintegrating ; a few of the tubes contain casts of either red or white corpuscles. Further away the condition of cloudy swelling prevails.

Pyæmic Infarction.—In a section of a small renal infarct, the vessels of the affected area will be found greatly congested and there will probably be considerable extravasation of blood. The epithelium may be stained yellow by the discharged blood pigment, and may show well-marked degeneration and disorganisation. There may be a considerable infiltration of leucocytes, more especially near the seat of the embolus

and therefore towards the apex of the infarct; or the infarct may be surrounded by a conspicuous zone of leucocytes and congested capillaries. The tendency for the whole is to break down into an abscess.

In a pulmonary infarct the alveoli are filled with extravasated blood, which rapidly becomes infected from the embolus and undergoes purulent softening. Outside the hæmorrhagic area there is a zone of croupous consolidation, and outside this again, congestion and œdema.

The other changes which may be encountered in pyæmia are:—

Puriform softening of thrombi in veins leading away from the primary focus of infection.

Cloudy degeneration of parenchymatous organs.

Hypostatic congestion of the lungs, and often croupous consolidation.

Serous exudations, petechiæ, thrombus formation.

Enlargement and softening of the spleen, &c.

Glanders and Farcy.—The primary lesion is usually a well marked leucocytic infiltration of the nasal mucous membrane, which proceeds to the formation of pus and ulcerates. The secondary lesions, "farcy buds," consist of multiple abscesses in all stages of development. Commencing as local infiltrations in the *muscles*, lymphatic glands or other structures, they rapidly break down into a thick pus. The exciting agent is the *Bacillus mallei* which may be found in cover-slip preparations of the pus, or in sections of recently hardened tissues, by staining in the case of the latter for 24 hours in Löffler's methylene blue, and by subsequently carefully and quickly decolourising with very weak acetic acid. Its demonstration is usually

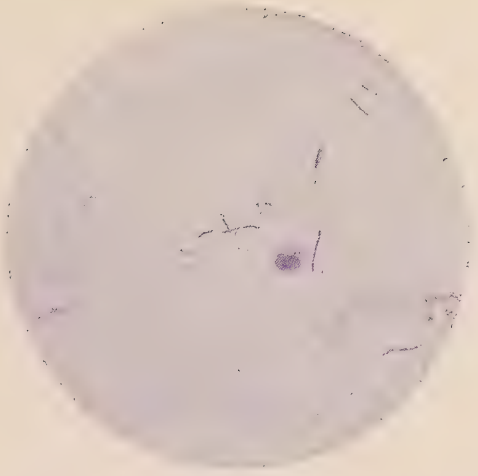

COVER SLIP PREPARATION OF ANTHRAX BACILLI MADE FROM ŒDEMA FLUID.

Obj. $\frac{1}{12}$ in., without eyepiece. (Gentian violet).

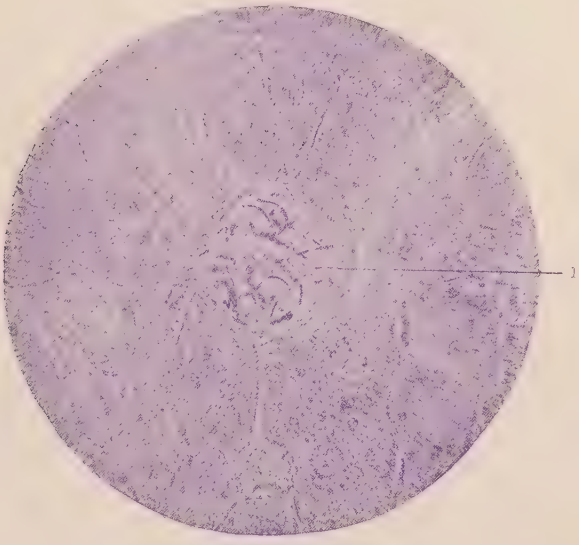

FIG. 38. ANTHRAX BACILLI IN A GLOMERULUS OF A GUINEA PIG'S KIDNEY

1. Glomerulus with bacilli.

Obj. $\frac{1}{12}$ in., without eyepiece. (Gentian violet and partial decolorisation).

however difficult, and, as in many other cases, inoculation is the best test. In addition to the ordinary pus cells there are much larger cells.

The *rash* consists of pustules and small ulcers. The epidermis is raised by a very abundant collection of white corpuscles, which rapidly degenerate, and the pustules bursting leave small ulcers. Inoculation usually gives rise to an indurated sore.

Anthrax (*malignant pustule, splenic fever*).—When a guinea-pig is inoculated with Anthrax, there follows, within a few hours, some serous and even slight hæmorrhagic exudation around the seat of puncture. If a cover slip preparation be made of some of the œdema-fluid, numbers of the bacilli will be discovered, and a little later they will be found in abundance in the blood.*

Fig. 37 is such a preparation of the œdema-fluid, stained in the usual way by Gram's method with gentian violet. The characteristic rod-shaped bacilli are seen, and their size may be compared with the scattered leucocytes around.

Fig. 38.—This is a section of the kidney of the guinea-pig, stained with gentian violet and partly decolourised by the iodine solution and alcohol. The bacilli are most abundant in the glomeruli, where they probably become first arrested, and subsequently segment and multiply. Their presence does not induce any marked histological change like the leucocytic exudation which surrounds pyæmic organisms.

The capillaries of the lung, liver and spleen may

* In the rabbit the local and general infection develops more slowly, but the former is most marked and takes the form of large collections of œdema-fluid in the neighbourhood of the inoculation.

this interesting fever a large spirillum, the Spirillum Obermeieri, can be observed in cover-slip preparations of the blood without staining. Towards the end of the relapse, the spirilla become abundant in the spleen. As a stain, fuchsine may be used.

Chronic Infective Processes or the Infective Granulomata.

In pyæmia, fig. 36, and in phlegmonous erysipelas, fig. 35, it was seen how pyogenic organisms excited in their immediate neighbourhood an intense inflammatory reaction, leading to the production of minute nodules of small round cells. It was further noticed how these inflammatory foci tended to spread and to suppurate. In the chronic infective processes it will be seen that a specific virus, acting more slowly and over a longer period, produces around it a localised inflammatory growth, the *granuloma*. As has been already learnt in the chapter on chronic inflammation, this consists in its most typical form of (1) a centre containing the *parasite*, be it the bacillus of tubercle, actinomyces or a zooparasite, enclosed in or surrounded by one or more *giant cells;* (2) of an intermediate zone made up of large cells, the epithelioid cells; and (3) of an outer ring of *small round cells*.

Like the acute infective processes, the chronic forms may be local or general, but as in their case so here, the one form may pass into the other. Usually in the general infective processes there is a *primary lesion*, a typical granuloma, of short or long duration; from this general infection ultimately results, and is manifested by the production of numerous secondary granulomata.

Apart from these specific reactions, there are, just as in the acute infective diseases, certain general tissue changes, viz., *fatty degeneration* of glandular and muscular organs, *fibrous tissue overgrowth* and *lardaceous degeneration* of the walls of the capillaries and small vessels. But these can only be regarded as evidence of a prolonged hectic or cachectic condition.

Examples.

Perhaps the simplest example of the mode of production of the characteristic lesions of the infective granulomata, is that afforded by a lung disease in dogs, which is due to a comparatively large parasite, the nomatode, *strongylus vasorum*.

According to Laulanié its discoverer, the adult strongylus lives amongst the trabeculæ of the right side of the heart and in the pulmonary artery, and produces its eggs there. These are washed away, just as minute fragments might be from the diseased valves in ulcerative endocarditis of the right side of the heart, and lodge, as might be expected of emboli, in the periphery and base of each lung. (Compare fat embolism).

Wherever an egg is arrested it excites at that spot an inflammatory reaction, and becomes the centre of a typical granuloma, which to the naked eye has a hyaline grey appearance and is somewhat smaller than a pin's head. On microscopic section the granuloma presents the following appearances:—

1. In the centre one or more giant cells, each containing or surrounding an ovum or embryo.
2. A zone of epithelioid cells.
3. An outer ring of small round cells.

After a short time the granuloma undergoes *retrogressive* metamorphosis and becomes converted into an *opaque yellow nodule*. The transformation commences in the epithelioid zone, the cells and ground substance of which pass into an amorphous cheese-like mass, in which the remains of one or more ova may be discovered. Exceptionally, however, fibrosis occurs in the epithelioid and small round-celled zones, and this *progressive* change seems to indicate that the parasite has ceased to be active.

Some of the giant cells are very long and cylindrical, and Laulanié is of opinion that they are formed inside the vessels by a proliferation of the endothelial nuclei around the arrested ova. It is common to find giant cells inside small vessels, and in Chapter V. this was noted in connection with the absorption of thrombi. It is quite possible that they are derived in this situation from a proliferation of the endothelium; they thus probably afford another illustration of the many ways in which giant cells originate.

The above is an example of the **zooparasitical granulomata**, which in the lower animals are common enough. They have been described in cats, dogs, sheep, cows and horses, both in the typical disseminated forms and in larger caseous or calcareous patches due to the extension and fusion of the smaller. The parasites usually encountered are numerous species of strongylus, echinococci and psorosperms, and their common seats are the lungs, kidneys and liver. In *man* they are no doubt often confounded with tuberculosis and other diseases, as the following cases tend to show.

Miura recorded a case of what appeared to be a

typical miliary tuberculosis of the peritoneum. On microscopical examination, however, ova of some parasite were found in the "tubercles."

Hadden described what appeared to be *miliary sarcomata* of the pericardium, pleura, peritoneum and kidney; calcification had commenced in the "tubercles," and in addition there were peculiar small cystic spaces which Cobbold and Goodhart considered to be in all probability stages of some parasite. Silcock mentions the presence in the liver and spleen of numerous tubercle-like caseous foci in which bodies resembling coccidia were found in groups.

The formation of tubercular-like tissue in man as in animals is not confined to the small parasites; a wall of giant cells, epitheliod and small round cells, with most externally a fibrous layer, very frequently surrounds a cysticercus or hydatid cyst.

As a practical point it may be observed that the presence of calcareous infiltration in a tubercle-like tissue should always suggest the possibility of an animal parasite.

Actinomycosis.

The Ray fungus or Actinomyces is the exciting agent of this chronic infective disease, which most commonly in the ox commences as a primary local affection of the tongue, to which organ it may impart a "wooden" or "scirrhous" induration. From the tongue the disease advances into neighbouring structures causing wide-spread destruction so that it has also been called "cancer of the tongue" or "osteo sarcoma." Much more rarely it *generalises*, involving secondarily the

lungs where it closely resembles Tubercle. Of interest is the occasional invasion of the spermatic cord of the ox after castration, the disease being the cause of one form of "scirrhous" cord. Other paths of infection, in both animals and man, lie through carious teeth, the tonsils, the alimentary tract generally, the respiratory system and the integument.

The parasite usually induces a typical granuloma, **Fig. 39.**

In the centre is the Ray fungus, usually in the form of a tuft or rosette; surrounding it are one or more giant cells, together with numerous epithelioid and small round cells. Sometimes the microphyte occupies the interior of a giant cell, whilst at other times, and this is very much commoner than in Tubercle, there are no giant cells, the fungus being closely invested by leucocytes. Small rosettes and individual clubs may be found in cells varying in size from the uni-nucleated leucocyte to the multi-nucleated giant cell, and even a leucocyte containing clubs has been observed enclosed within a giant cell (Crookshank).

Retrogressive change is usual, caseation or calcification (animals) often starting in the centre of a rosette, but softening with the formation of a pus-like fluid may also occur, and large abscesses have been formed through coalescence of the nodules. The pus should be carefully examined for SMALL SULPHUR YELLOW BODIES* about one-half the size of a pin's head, for they are the rosettes and are diagnostic of Actino-

* The colour of these bodies varies—the youngest, on the authority of Boström, have a gelatinous boiled sago-grain appearance, older ones may be white, yellow, greenish, brown and even black.

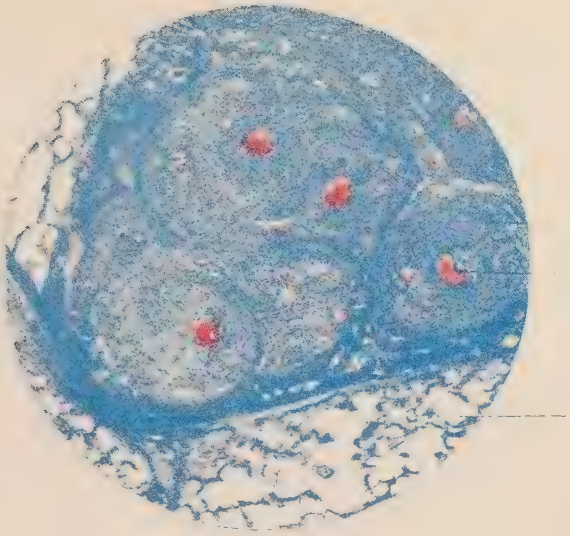

granuloma
2 Actinomyces in centre of granuloma
3 Lung tissue

Obj. 1 in. (Fuchsine and methylene blue).

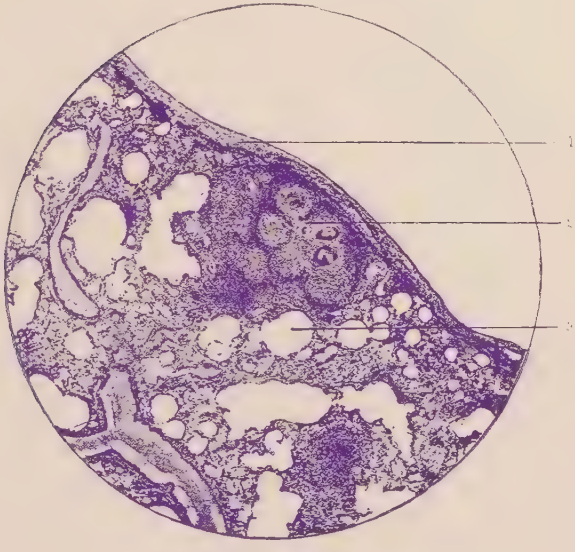

Fig. 40. MILIARY TUBERCULOSIS OF LUNG

1. Thickened pleura.
2. A 'tubercle' composed of several small nests
3. Emphysematous condition of the alveoli.

Obj. 1 in., without eyepiece. (Logwood).

mycosis. Examination is best made by spreading some pus on a slide and searching for the yellow specks; when found they are washed and some may be stained in a drop of logwood on a slide, then covered with glycerine and a cover slip and pressed so as to break up the clump, the stained clubs are then readily recognised; or one rosette may be pressed between two cover slips, and cover slip preparations made after the method of Gram.

In sections the Ray fungus is readily recognised, and may be stained more or less successfully and easily according to the presence or absence of calcification or other degenerative changes. The combination of Orth's carmine, with picric acid and Gram's method may be used; or as Boström recommends, the sections may be first stained with Weigert's gentian violet, and then, without passing them through the iodine solution, with Weigert's picro-carmine; the excess of the gentian violet is washed out with absolute alcohol, and sections are obtained in which the hyphæ are stained blue, their capsules (clubs) red, and the ground tissue the usual picro-carmine tints.

The actinomyces is a spore bearing and pleomorphic organism, showing many of the "form phases" seen in Cladothrix. When the resistance to the growth of the fungus is marked, as shown by the chronicity of the process and the greater tendency for the fungus to become encapsuled by the growing granulation tissue, the actinomyces tends to assume the rosette form with the formation of the clubs. This phase may be, perhaps, analogous to a protective zooglœa state, or as Boström suggests indicate a tendency to involution and degeneration. The greater resistance on the part of

the tissues is seen in the ox; on the other hand, in man, the inflammatory reaction is more acute, and tissue destruction and suppuration more marked. It is under these circumstances, as J. Israel remarks, that the fungus assumes its more vegetative or mycelial form.

Closely allied to Actinomyces, if not identical with it, is the cladothrix-like organism described by Eppinger, in a case of cerebro-spinal meningitis. It causes multiple lesions resembling tubercle, and he has, therefore, named the condition *pseudo-tuberculosis cladothrica*.

Tuberculosis.

"Tubercle" is the most important of all the infective granulomata, being widely distributed both in animals (domesticated) and in man. In the former its naked eye appearance has gained for it, in this and in other countries, the suggestive names of the "Grapes," "Angle berries," and "Duckweed," "Pearl," and "Potato" disease.

The exciting cause is the *Bacillus tuberculosis* of which the appearance differs somewhat in the various animals including man. The bacillus usually excites at the seat of its inoculation a chronic inflammatory reaction; occasionally, however, its mode of entry often escapes detection, and nothing is observed until some internal structure such as an epididymis or a bone becomes tubercular, or until an acute general tuberculosis manifests itself. At the seat of inoculation a struggle may be carried on between the organism and the system for months or years, healing (resistance)

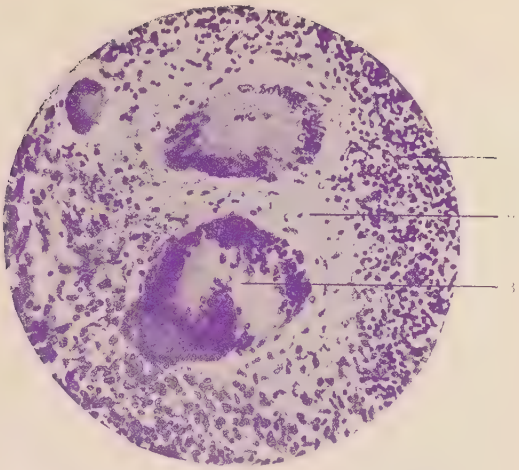

Fig. 41. PORTION OF THE ABOVE TUBERCLE

Under the ⅔ in. Ob.

1. The small round-celled zone.
2. The epithelioid zone, and zone of necrotic changes
3. A large giant cell



Fig. 42. GUMMATA IN THE LIVER

1. Liver substance.
2. Gumma

One half natural size

and destruction (invasion) going on side by side until one or other gains the final ascendency. Examples of this antagonism are seen in their different and varying aspects in chronic phthisis, tubercular and lupoid ulceration of the skin, tubercular ulceration of the intestine, and in the tuberculosis of certain internal structures, such as the lymphatic glands, epididymis and bones, which latter group are seats of election of the bacillus. From one of these primary foci dissemination may at any time occur and give rise to *acute miliary tuberculosis*. The less the resistance of the subject the greater is the liability to general infection; injured tissues are also more prone to suffer. As just mentioned the virus singles out certain tissues, others are more resistant, for example, the whole alimentary tract of the fowl may be infected with the exception of the gizzard. In general tuberculosis the meninges, serous surfaces, lungs, liver and kidneys, show innumerable lesions.

The tubercular tissue, both in the miliary (Figs. 40 and 41) and diffuse spreading forms, has already been described under granuloma, Chapter II. (figs. 19, 20, 21, 22). It will have been gathered from the description there given, and from the examples on the preceding pages, that there is nothing specific in the tubercular reaction and that it is not justifiable to make a diagnosis from the mere course and grouping of the lesions, the proneness to caseation and the presence of numerous giant cells—though these are certainly signs which are typical in a great number of instances—but that the bacillus ought to be sought for before a final conclusion is drawn. For this latter, as well as for other purposes, sections of the tissue should be stained

24 hours in Ziehl-Neelsen's fuchsine, and decolourised in nitric acid 1 in 3 (see p. 14).

In the granuloma the reaction of the tissue elements against the invading parasites is marked by proliferative changes in the nuclei of the connective tissue and other cell elements of the part; also, probably, by an increased gravitation of the wandering cell elements to the seat of disturbance. If the reaction is successful the bacilli are removed and new tissue marks the spot. Usually the reverse happens and the cells undergo peculiar epithelioid changes and subsequent necrotic transformation. This diversion of the normal tendencies of the proliferating corpuscles is in all probability, as has been previously pointed out, due to the injurious action of the parasite. Similarly the giant cells are perhaps not only in tubercle but also in other allied processes to be regarded as simply cell monstrosities produced by the altered conditions of growth imposed upon them by the presence in them or in their neighbourhood of some irritating foreign body, more especially a living parasite. They appear, moreover, in the chronic infective processes, to be the more resisting cells and the cells in which the reaction against the virus is kept up longest. Again, as has already been pointed out they have not an origin restricted to one cell form, and the fact that in tubercular tissue they may be met with amongst the small round cells, in the lymphatics, in the small vessels, free in the alveoli, as long cylindrical masses in the seminiferous tubules of the testis, helps to confirm the view of an origin from the various tissue and wandering corpuscles of the part.

Pseudo-tuberculosis. — Under this unnecessary

term are included certain diseases which resemble tubercle in the course, distribution and anatomy of their lesions. We have already become acquainted with Eppinger's pseudo-tuberculosis-cladothrica and the nematode pseudo-tuberculoses. In addition, Mallasez and Vignal, Eberth and others, have described tubercle-like conditions due to micrococci and short rods. Chantemesse and others have observed in animals similar appearances produced by general infection with Aspergillus fumigatus.

Lupus.—The cause of this very chronic tubercular inflammation of the skin and occasionally of mucous membrane, is a bacillus identical with Bacillus tuberculosis, but it occurs far less abundantly. Moreover caseation is not so common, dense fibrous tissue being more often formed. For description see p. 56.

Leprosy.—In this also very chronic infective disease, a small round-celled infiltration occurs in the skin, giving rise to nodules which may ultimately ulcerate; similar nodules are also formed in several of the nerves, but more especially in the ulnar. In the lymphatic glands, spleen and liver, granulomata may be demonstrated. In all these lesions, the Bacillus lepræ is found in great quantity, some are in corpuscles of various sizes, including giant cells, others form globular masses of various dimensions of which it is sometimes difficult to say whether they are altered giant cells filled with bacilli or plugs of organisms in lymphatic channels. To stain the bacilli proceed as for tubercle.

Syphilis.

After a period of quiescence or INCUBATION PERIOD, which lasts about three or four weeks, there usually develops at the seat of inoculation in the skin or mucous membrane, a circumscribed nodule of cartilaginous hardness which has received the name of the HARD SORE or CHANCRE. It is formed by an abundant small round-celled growth consisting of leucocytes and proliferating corpuscles in the connective tissue, vessels, nerves and glands of the part. The epithelium on the surface usually becomes infiltrated with leucocytes, and when it desquamates it exposes an indurated floor which then undergoes slight ulceration. The epithelium at the margin shows signs of hyperplasia. In addition to the small round cells, there are a few larger scattered corpuscles with one or several nuclei; but there are no typical giant cells as in Tubercle, nor does caseation occur. The growth is more vascular than the tubercular granuloma and tends to pass into well formed fibrous tissue.

Lustgarten has demonstrated bacilli in the larger cells, whilst Eve and Lingard describe others in the deeper layers of the chancre.

Occasionally inoculation elsewhere than on the penis gives rise to a much softer sore accompanied by congestion and œdema, indicating perhaps a lessened resistance at such a spot.

SECONDARY LESIONS follow after an interval of quiescence. They consist of (1) RASHES—roseolar (mere hyperæmia), papular, vesicular and pustular;—of (2) slight ULCERATION OF THE THROAT; and of (3) MUCOUS TUBERCLES OR FLAT CONDYLOMATA.



Fig. 43. PORTION OF ONE OF THE PRECEDING GUMMATA

It is composed of dense hyaline material, except at one portion where there is a patch of small round cells.

Obj. 1 in., without eyepiece (Logwood

Fig. 44. DIFFUSE SYPHILITIC FIBROSIS OF LIVER

1. Liver substance.
2. Large bands of fibrous tissue

One half natural size.

Of the rashes and ulceration nothing further need be said as they are quite simple, but about the syphilitic condylomata a few words are necessary. These occur only in places kept *moist* as around the anus, at the angles of the mouth, about the scrotum, &c.; they consist of raised, soft, flat, mamillated or slightly papillary patches of skin or mucous membrane, which on microscopic section present an infiltrated and œdematous papillary layer covered by a sodden and infiltrated epithelium. Their moisture is described as intensely infectious, and bacilli (Eve—Lingard) have been found in them.

Often after a long period of apparent inactivity, another series of manifestations—the TERTIARY may succeed the secondary. These chiefly consist of (1) *diffuse* and *localised chronic inflammations* of various structures, which terminate either in fibrous-like induration, caseation or suppuration; of (2) deep *ulceration* of the skin and mucous membrane; and of (3) chronic inflammatory changes in the walls of the blood vessels, namely SYPHILITIC ENDARTERITIS.

The localised chronic inflammations have received the name of GUMMATA or SYPHILOMATA and are characteristic of advanced syphilis. In size they may vary from that of a pea to a walnut, though occasionally they occur in a miliary form. They are most frequently observed in the liver, testicle, subcutaneous structures, submucous tissue of the tongue and pharynx, on bone, in muscle and in the brain, kidney, &c. **Fig. 42,** reduced one-half, shows the appearance of a group in the liver which was otherwise healthy. They commence, like the chancre, as small round-celled infiltrations, which become transformed in the

centre into a dense structureless fibrous material, which in its turn may caseate. **Fig. 43,** taken from near the middle of one of the above gummata, shows under the low power (1 in. obj.) this amorphous marble-like material, into which a group of corpuscles are undergoing transformation. In glandular organs there is considerable destruction of the parenchyma in the vicinity of the gumma, owing to the corpuscular and fibrous overgrowth, though some of the gland nuclei share in the proliferative changes. Sometimes too conspicuous fibrous bands radiate out, and as they contract cause much puckering of the organ. At the margin of the gumma, the filling up of small vessels by connective tissue overgrowth is more marked than in the chancre, and the consequent cutting off of the blood supply is one of the causes in the vicious circle which leads to the necrosis of the syphilitic neoplasm.

Gummata seated beneath the skin and mucous membrane show a much greater tendency to suppurate, in all probability owing to infection with micro-organisms.

The DIFFUSE CHRONIC FORMS OF SYPHILITIC INFLAMMATION are equally wide-spread, and as in the case of the gummata, the process is well seen in the Liver.

Fig. 44, is a section, one-half natural size, of part of a liver which shows the diffuse distribution of dense fibrous tissue and the marked irregular outline of the organ produced by the contraction of the larger bands. The condition altogether contrasts with that seen in fig. 42.

Fig. 45, is a magnified section from another case of advanced syphilitic cirrhosis, in which there is almost complete atrophy and destruction of the glandular sub-

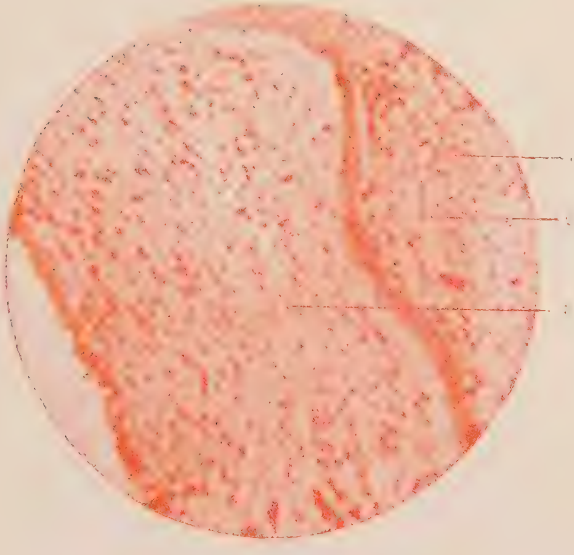

Fig. 16 SYPHILITIC ENDARTERITIS

1 Middle coat

2 Elastic lamina considerably thickened.

3. Inner coat, consisting of syphilitic granulation tissue.

Obj. ½ in., without eyepiece. (Carmine).

stance, which is only represented by a few scattered hepatic cells, as at 1.

Syphilitic endarteritis.—In syphilitic granulation tissue an overgrowth of the connective tissue elements of the vessels is a marked feature, and as has already been observed, often leads to occlusion. But apart from this, many of the vessels of the brain, more especially the basilar and middle cerebral arteries, are liable to a neoplastic formation limited to them and occurring both in the subjects of congenital and acquired syphilis. All the walls are involved in the growth, which is either limited and nodular or diffuse. The most noticeable change is, however, produced in the intima which becomes greatly thickened and often causes complete blocking. For example, **Fig. 46** represents under obj. $\frac{1}{4}$, a very small segment of the middle cerebral, part of the lumen being seen to the left of the figure. This wavy *elastic lamina* which is considerably *thickened* is indicated by 2; and it is a useful landmark, for it limits externally the inner coat, which is abnormally thick. This increase is due to granulation tissue, consisting of spindle and small round cells, wavy bundles of fibres and capillaries, with, in addition in some specimens, of a *new formation of elastic tissue*. The middle coat is infiltrated with the new tissue, and the adventitia, though not seen in the figure, is likewise affected; in both there is a considerable new formation of vessels.

In Congenital Syphilis the lesions are much the same as those in the adult. The liver and spleen are very often enlarged. In early stages of syphilitic liver, very numerous groups of deeply staining small round

cells may be found scattered everywhere; later these appear to give rise to either *miliary gummata* or to a *diffuse infiltrating growth* similar to that in Fig. 45. Sometimes the corpuscles seem to be grouped more especially around the branches of the hepatic artery; at other times there is considerable corpuscular infiltration and fibrosis of the portal canals.

Inflammatory Lesions resulting from the presence of the Higher Fungi.

Many of the Aspergilli are pathogenic and excite several interesting inflammatory processes which have been much studied by Grawitz and others. Leber showed their presence in suppurative keratitis; they have been also found in suppurative otitis; they are often found in the respiratory passages of birds, and may in some excite severe pneumonia. Sometimes the lesions produced by them are more chronic, giant cells being formed; the latter condition has been observed in the lungs of animals, and Chantemesse as has already been observed has described a pseudo-tuberculosis. The mycelium has been found in human sputa in chronic lung affections. The species most commonly encountered appears to be the Aspergillus fumigatus.

A *mycosis mucorina* has been described by Paltauf producing pneumonia and metastases in the human subject.

Achorion Schönleinii in Favus, and *Trichophyton tonsurans* in Tinea, are hyphomycetous fungi which excite chronic superficial inflammatory reactions in the skin. The ramifying hyphæ and spores may be observed amongst the epithelial cells and roots of the hairs.

They may be sought in epithelial scrapings after first treating with ether and dilute caustic potash. Staining is not necessary. In the lower animals there are several species of the above fungi.

In Pityriasis versicolor, a mycelial fungus, the *Microsporon furfur* grows in the superficial layers of the epidermis and produces a scaly desquamation.

In Thrush a yeast-like hyphal fungus, the *Saccharomyces albicans*, gives rise with epithelial and food débris to the white patches which are met with on the tongues of ill-nourished infants.

Chapter VIII.

TUMOURS.

The following is the order of description adopted in this chapter :—

A. Simple tumours and tumour-like hyperplasias of the more highly specialised tissues, as the

Nervous—neuromata.

Muscular—myomata.

Vascular and Lymphatic—hæmangiomata, lymphangiomata, endotheliomata.*

B. Simple tumours and tumour-like hyperplasias of the tissues of the framework, as the

Fibrous—fibromata.

Cartilaginous—chondromata.

Bony—osteomata.

Fatty—lipomata.

Myxomatous—myxomata.

C. The rapidly growing and malignant forms of the preceding group—*Sarcomata*.

Fibro-sarcomata = round-, spindle-, branched- and giant-celled sarcomata.

Myxo-sarcomata.

Osteo-sarcomata.

Chondro-sarcomata.

* The simple epithelial tumours will be described with the malignant forms (see below). The *tumours of the lymph glands*—lymphomata and lymphosarcomata—will be reserved for description in a separate chapter.

D. Epithelial tumours (simple and malignant) :—

1. Of epithelial surfaces { stratified. / columnar. / serous and endothelial.
2. Of glands.

NEUROMATA { medullated (myelinic). / non-medullated (amyelinic). / ganglionic. / gliomata and fibroneuromata (false neuromata).

The amputation neuroma, which is the bulbous ending of the central segment of a divided nerve, is a simple example of the formation of a *medullated* nerve tumour, or to be more exact, of a tumour-like hyperplasia. In the chapter on repair, it is described as due to a hemming in by the scar tissue of the down-growing nerve fibres, which are consequently forced to twist and run round, and so to form a ball of interwoven nerve bundles. **Fig. 47** is a section through a typical one, and was made from the bulbous end of the ulnar nerve mentioned on page 69. It is stained with osmic acid, and the deeply coloured parts 1 and 2 are the nerve bundles, some cut obliquely, some transversely ; 3 points to the interstitial connective tissue, which is here not in excess.

In other forms of nerve tumours, such as in the *multiple neuromata* of peripheral nerves, the various components of the nerve are developed in different degrees, and give rise to distinct types of tumour. For example, in a patient affected with multiple neuromata,

a section of a tumour at one spot may show after having been treated with osmic acid, the structure of a medullated neuroma, and therefore precisely resemble the one here figured. A section of another reveals no medullated fibres, and the tumour has the appearance of a true fibroma, until by staining by Weigert's or some equally serviceable method, it is found to be composed of non-medullated fibres, to be in fact an *amyelinic-neuroma*. Finally a section of one of the tumours which are more especially seated in the skin, may be found to consist almost entirely of the proper fibrous tissue of the nerve, it is therefore a *fibroneuroma*. Multiple neuromata of the peripheral system are frequent, and their structure may vary as above in the same case or in different cases.

In the central nervous system *ganglionic neuromata* are found forming circumscribed or more or less diffuse tumours made up of ganglionic cells, nerve fibres and neuroglia; examples are occasionally seen in the pineal and pituitary bodies, and in the walls of meningoceles. Circumscribed and diffuse growths of the neuroglia probably take the place in the central nervous system of the fibroneuromata of the peripheral. The former are grouped under the general term *gliomata*, and like the fibroneuromata, which will be more fully described under the fibromata proper, they show a tendency to become sarcomatous.

MYOMATA { unstriped—leiomyomata.
striped—rhabdomyomata.

Leiomyomata.—The leiomyomata are most commonly clearly circumscribed tumours which arise from pre-exist-

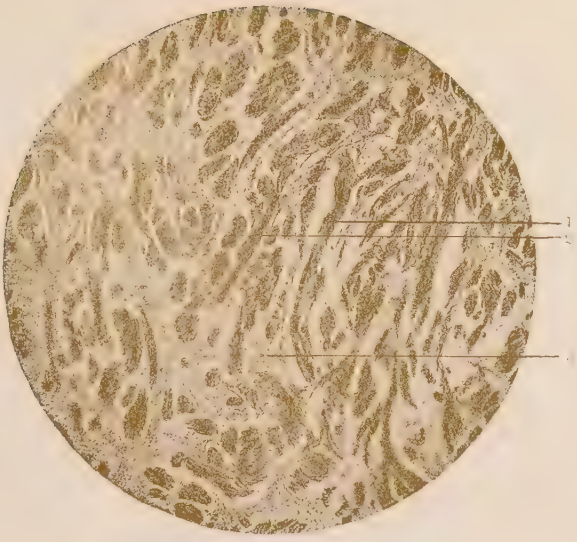

Fig. 47. SIMPLE NEUROMA (after amputation)

1 & 2. Nerve bundles
3. Connective tissue.

Obj. 1 in. (Osmic acid)



Fig. 48. "FIBROMA" OF UTERUS.

1. Uterine wall.
2. Myoma (fibroid).

Obj. 1½ in. (Hæmatoxylin)

ing muscular fibres. They consist of long tapering cells with regular oval nuclei. The fibres run in bundles which twine and interlace in all directions and give to a section on this account a characteristic grained appearance. **Fig. 48** is a section slightly magnified of a small portion of the "fibroid" or myofibroma of the uterus, one of the commonest examples of the myomata. The tumour is readily recognised in the figure on account of its loose attachment to the uterine tissue and its grained, deeply stained appearance which contrasts with the more uniform and less deeply stained uterine wall. **Fig. 49,** which is a more highly magnified section, shows the different directions which the fibres take and their characteristic oval nuclei; a considerable amount of delicate interstitial tissue is also seen. The figure should be carefully compared with that of the true fibroma fig. 50 immediately below it.

The uterine myomata are frequently multiple and vary enormously in size. They are divided into three well recognised groups: the interstitial (as in the illustration), subserous and submucous; the two latter varieties in addition form *polypi*. Pregnancy exercises a marked influence in increasing their size, but with age they tend, as does the uterus, to become more fibroid.* They are sometimes the seat of a *cystic* change and indeed the "cystic fibroid" appears to form a distinct variety. Venous dilatation also occurs.

Myomata occur in the prostate; usually all the lobes, but especially the central one, undergoes tumour-like

* In this latter respect therefore they are unlike true tumours. Klebs has described what appeared to be a curious case of metastasis of a myo-fibroma.

increase. They occur in the old at an age when there is considerable venous dilatation of the organ.

Leiomyomata are not altogether rare in the alimentary tract where they assume a polypoid form. A more interesting group are the multiple *dermato-myomata*, small tumours which to the naked eye and touch are like fibromata; they appear to originate from the small cutaneous muscular structures such as the arrectores pili, vessel walls, dartos, &c. It is probable that the nævus also may give rise to a myoma by proliferation taking place in the muscle fibres of the vessel walls.

Rhabdomyomata.—These appear for the most part to be associated with the mixed or sarcoma-like tumour formations, which occur in the ovary, kidney, testis, vagina, uterus, spinal cord, &c. The muscle fibres lie scattered about amongst the other cells or collected into bundles and exhibit all kinds of curious embryonal forms. Their probable origin from "rests" will be referred to in the chapter on congenital formations.

Angiomata { Hæmangiomata. / Lymphangiomata.

The angiomata are circumscribed tumour-like growths of blood or lymph channels. The vessels or lacunæ possess well or ill-defined walls, and the intervening supporting stroma, which may be more or less well developed, may present characters which differ from that of ordinary connective tissue.

Hæmangiomata or *Nævi*—Simple and cavernous.

The commonest examples of the simpler forms are the congenital capillary nævi of the skin, slightly raised

tumours which attract attention owing to their red colour. The blood channels of which they are composed may possess very irregular lumina and delicate walls, or be furnished with more regular, thick and muscular ones. The stroma may be well represented or be so small that the distinction between it and vessel wall is lost. They occur in the superficial and deep layers of the skin, and epithelial appendages which may be invested by them, such as sweat glands, hairs, &c., are often hypertrophied. Their growth is best studied in the sub-epithelial fat, where the tumour forms small cellular clumps of proliferating vascular elements and connective tissue corpuscles.

The *cavernous nævus* is a much more sponge-like structure and a typical example is the nævus of the liver, more common however in the lower animals than in man. Touching their origin, some may be mere dilatations of the pre-existing capillaries, akin to what is seen in the centres of the lobules of a congested liver; very many are, however, new formations, true angiomata, which consist of inter-communicating blood spaces and of cellular connective tissue in which new blood spaces are formed by proliferating endothelial cells.

Under the term angioma, just as under that of neuroma, several distinct types of tumours must be included. The vessel wall does not consist of one tissue, but is made up of an endothelium, fibrous tissue and muscular fibres, any of which layers there is strong reason to believe may give rise to tumour formation. Thus further on under *endotheliomata* will be described growths limited to the endothelium, which are frequently multiple and lead to the formation of cavernous nævi. A uniform overgrowth of the fibrous tissue peculiar to the

vessel wall has been recorded; a small subcutaneous tumour was produced, which from its appearance might have been likened to a small mass of vermicelli; it was made up of vessels $\frac{1}{16}$ in. in diameter but with only a lumen the $\frac{1}{12}$ of this.* Such a change appears to be analogous to that which occurs in the diffuse fibrous neuroma of the peripheral nerves.† Lastly allusion has been made to the probable origin of myomata from the muscular coat.

The angiomata are occasionally the seat of a striking hyaline or colloid-like change, a cylindromatous appearance being often given to the tumour. A nævus is sometimes mixed up with a large overgrowth of fat; to this condition the term *nævo-lipoma* has been applied. Finally there appears to be numerous transition stages between angiomata and the more cellular and rapidly growing *angio-sarcomata*.

Lymphangiomata.—These are congenital tumours and resemble the cavernous angiomata just described. The tendency to become cystic is, however, much more marked and there are numerous gradations up to the huge *cystic lymphangiomata* to be described under cystic tumours. As in the case of some nævi, so here many lymphangiomata are mere dilatations of the lymphatics; the majority however, and this includes the multiple forms (lymphangioma tuberosum multiplex, &c.) are probably derived from lymphatic endotheliomata; in these cases an endothelial proliferation precedes the dilatations.

In *macroglossia*, *macroheilia* (hypertrophy of the lips),

* I have observed a similar striking change in the small vessels in a case of atrophic skin disease.

† It might be named on this account a rankenangioma.

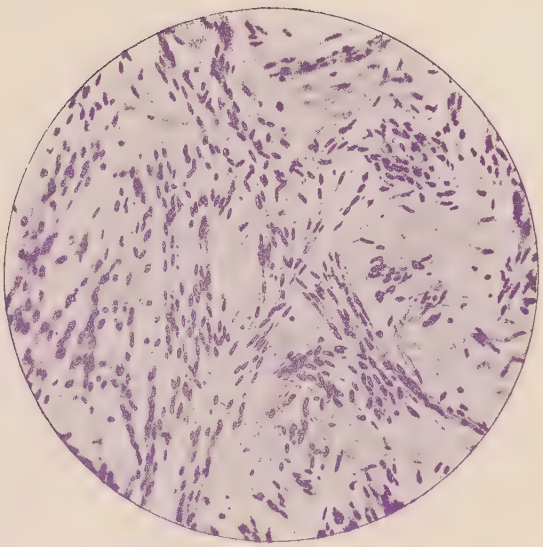

Fig. 49. The preceding Myoma under the ¼ in. Obj. Logwood.

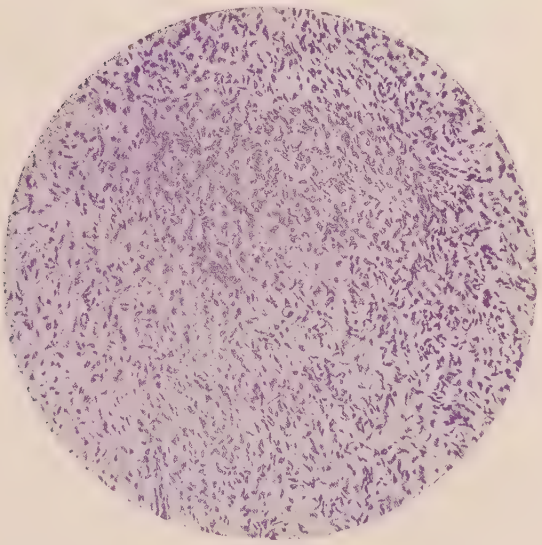

Fig. 50. FIBROMA FROM THE SKIN.

¼ in., without eyepiece. Logwood.

macromelia (hypertrophy of the cheeks) and in *congenital elephantiasis*, the most striking anatomical change is the overgrowth and dilatation of the lymphatics. The term *chylangiomata* has been given to tumour-like dilatations of the abdominal lymphatics. The *cysto-lipomata* are lymphatic nævi associated with fatty tissue overgrowth.

B. Simple tumours and tumour-like hyperplasias of the tissues of the framework (so-called interchangeable tissues).

FIBROMATA.
CHONDROMATA.
OSTEOMATA.
LIPOMATA.
MYXOMATA.

Fibromata and fibroma-like hyperplasias.—The typical fibroma is a hard circumscribed growth which consists of numerous corpuscles lying compressed amongst white connective tissue fibrillæ. The bundles of fibres are disposed very irregularly, sometimes twisting sometimes running straight, directions probably determined by the vessels. A section of part of such a tumour is that represented in **Fig. 50,** which is taken from a fibroma of the skin. Fibromata however present most striking variations both as regards structure and form, place and mode of origin, relations to other tumours and pathological processes. They occur in the skin and subcutaneous tissue, both singly and multiple; and in this situation may assume papillomatous and polypoid forms (wens, molluscum fibrosum, neurofibromata of the skin). They arise frequently from the periosteum, more especially from that of the lower jaw;

in the latter situation they often form the *fibrous epulis;* they likewise spring from dental periosteum, and around carious teeth small irritation fibrous polypi are not infrequently met with. They sometimes occur in bone and may cause its expansion by their growth. Fibromata are especially frequent in connection with *peripheral nerves.* In *glandular* organs such as the mamma, liver and kidney, they are most frequently associated with some definite glandular change (adeno-fibromata). They appear in the *ovary* and *uterus*, but the "*fibromata*" of the latter and the tumour-like formations in the prostate are as a rule myomata. They may have their seat in the *vocal cords.*

The fibrous growth may be circumscribed, as in the great majority of the above cited examples, or diffuse passing into fibrous hyperplasia. Thus some reckon amongst the fibromata, ELEPHANTIASIS ARABUM, in which there is an enormous hypertrophy of skin, areolar tissue, and oftentime of the lymphatics and even bone, limited for the most part to the genitals and legs; and ELEPHANTIASIS NEUROMATOSA, in which there is a diffuse overgrowth of fibrous tissue originating from circumscribed neuro-fibromata in the skin.

The tissue composing the fibroma may be hard or soft, with few or many cells, spindle, oval, round or branched according to the consistence and place of origin of the tumour. The fibrous element may greatly preponderate, and occasionally there are elastic fibres. The fibrillæ may undergo a *hyaline* and the ground substance a *mucinous* change.

The *nasal polypus*, **fig. 51,** is an example of a delicately fibrillated and soft fibrous growth. It consists, as seen in the figure, of a mucinous ground substance and a

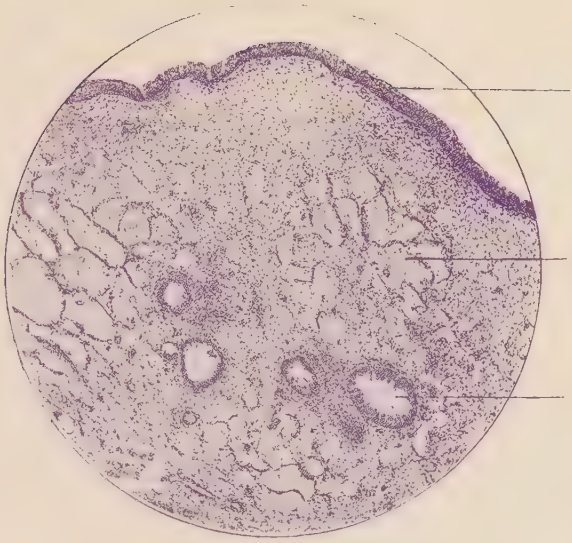

Fig. 61.—A NASAL POLYPUS.

1. Stratified epithelial surface.
2. Mucous areolar tissue.
3. A mucous crypt.

Obj. 1 in., without eyepiece. (Lockwood.)

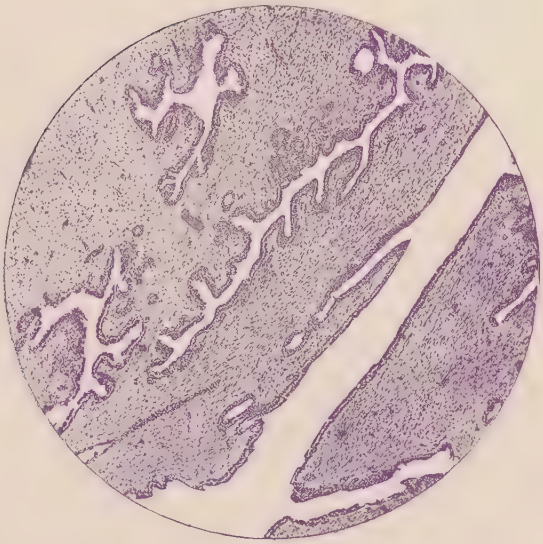

Fig. 62.—ADENO-FIBROMA OF BREAST.

Obj. 1 in., without eyepiece. (Lockwood.)

network of delicate fibrillæ with numerous round connective tissue corpuscles. Here and there, buried deeply in the polypus, are cystic cavities 3, filled with mucus and lined by stratified epithelium similar to that which covers the surface of the tumour.

Cystic and adenomatous changes are frequent in gland tissue involved in a fibroma.* For instance in the fibroma of the skin, a sweat gland at the margin of the growth frequently shows a typical adenomatous appearance, and the sebaceous glands may be somewhat similarly changed. To a still further modification of these cutaneous glands are due the presence of some of the large cystic cavities found occasionally in superficial fibromata. On the other hand *cystic fibromata* are encountered in bone, and there is every reason to believe that here, as in many other cases, they are derived from dilatation of lymphatic interstices. In the breast the typical *fibro-adenoma* occurs. It consists of a hard circumscribed fibrous nodule, in which the gland acini are completely altered both as regards appearance and function. **Fig. 52** represents a typical specimen; it shows the compact cellular connective tissue stroma and the slit-like flattened gland acini which are lined by a layer of cubical epithelium. The breast also furnishes one of the best examples of the *intracystic* or *intracanalicular-fibro-adenoma;* a modified fibro-adenoma in which polypoid rather than papillomatous masses of cellular connective tissue project into and tend to fill up the cystic or slit-like spaces; the appearance is quite different to that produced by the delicate branching papillomatous growths

* It is probable that in many cases it is the fibrous tissue which invests these structures which becomes the seat of a fibroid growth.

which occur in other cysts, notably in ovarian. The fibrous tumours of the mamma may be the seat of some important changes in the stroma. For instance the ground substance may become mucinous, the fibres delicate and reticulate, and the corpuscles branched (*fibro-myxoma* or *myxo-adenoma*). Or a rapid proliferation of the connective tissue corpuscles may occur and the tumour may closely resemble a spindle or round-celled sarcoma (*fibro-adeno-sarcoma* or *adeno-sarcoma*).

The NEURO-FIBROMATA constitute a most important group of fibromata; most of the cases of *multiple fibromata of the skin* including molluscum fibrosum, and the previously mentioned elephantiasis neuromatosa appearing to derive their origin from fibromata of peripheral nerves. They are usually multiple, and appear to arise in the majority of cases from the *endo-* and *perineurium*, much less frequently from the *epineurium*. Roughly speaking, in the first case the nerve fibres are separated, in the second the nerve bundles, and in the third the nerve itself is pushed to one side by the growth. Usually they are circumscribed, sometimes however diffuse; they may either grow along the nerve and cause much twisting and coiling of the same as in the *plexiform* or *ranken-neuroma*, or spread out into the surrounding tissue and lead to diffuse fibromatosis, the *elephantiasis neuromatosa*. They afford moreover examples of sarcomatous transformation, even proceeding to malignancy, recurring in such organs as the lung.

There sometimes develops in the seat of an old scar a small fairly circumscribed fibrous tumour—the *keloid**—composed usually of dense fibrous tissue with but few

* The keloid is in many cases more than a mere hyperplasia. In negroes large pendulous fibroids are occasionally produced as a result of piercing the ears with "ornaments."

Fig. 53. FIBRO-PAPILLOMA FROM SCALP.

Observe the delicate branching of the connective tissue framework.

Obj. 4 in., without eyepiece. Leitz.

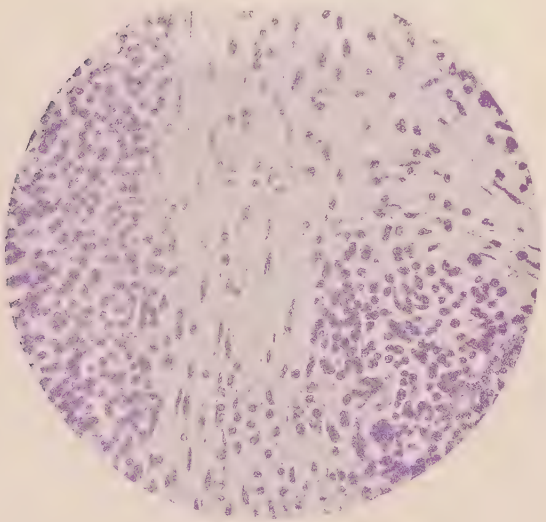

Fig. 54. SMALL ROUND CELLED SARCOMA OF SKIN.

Obj. 4 in., without eyepiece. Leitz.

cells except immediately around the vessels. It is of interest because it serves to introduce a large series of tumours or HYPERPLASIAS, chiefly composed of fibrous tissue, and either covered by one of the varieties of epithelium (*fibro-papillomata*), or in relation with some glandular structure (forms of *fibro-adenomata*).

The chief examples of the FIBRO-PAPILLOMATA are the following, all of which appear related to some form of *chronic inflammation.—Colitis polyposa* of chronic dysentery, consisting of a most remarkable formation of polypi and papillæ; similar formations around *specific* and *simple ulcers* of the alimentary tract; *tracheal*, *laryngeal*, *pharyngeal*, and *lingual papillomata*—associated with some form of local inflammation; the *synovial papillomata* of arthritic joints; the *condylomata* of the skin, excited by irritating discharges; the *papillomata of sebaceous cysts;* the *papillomata of the bladder*, which very frequently arise as the result of chronic irritation; some forms of *papillomatous* and *polypoid formations of the uterine mucous membrane*, likewise intimately related to endometritis; the *black choroidal polypi* of the eye, &c. They consist of delicate vascular fibrous tissue covered by the epithelium of the part from which they grow—columnar, serous, synovial or stratified as the case may be; so often, however, is the epithelium deeply altered, that a large majority are described under epithelial formations, indeed the great interest of these tumours centres round the epithelial changes. **Fig. 53** gives a good idea under a low power of the general appearance of a cutaneous papilloma, which arose in this case from the scalp and attained a great size. The epithelium which is hypertrophied and irregular is especially conspicuous. The stroma is very

vascular but not so vascular as that of the gonorrhœal condyloma.

The chief examples of FIBRO-ADENOMATOUS hyperplasia are found in the kidney, lung and liver, where local formations of fibrous tissue arise under similar circumstances to the last group, and being almost always associated with some change of the special cell elements of the part, renal, pulmonary, hepatic, warrant the name of fibro-adenomata. As in the papillomata so here the epithelial element may become deeply altered or predominate. In the lung for example it is not rare to meet, associated with chronic pneumonia, fairly localised formations of richly cellular and vascular fibrous tissue which obliterate the alveoli; in this proliferation the lining cells of the alveoli share and give rise to small gland-like structures. Sometimes the cell growths in the lung assume papillomatous forms.* In the kidney similar growths are encountered and are due to some chronic inflammatory process. Finally in the liver, coccidia aud other parasites, gall stones and other sources of local irritation, often produce well-marked fibro-adenomatous and papillomatous formations.

Chondromata.—The typical chondroma is circumscribed, varies much in size and is very often multiple. It originates most commonly from the phalanges and metacarpals of the young, and possesses a structure which resembles the types of normal cartilage, viz., hyaline, fibrous,† reticular and their combinations.

* These proliferative changes in the lungs are probably analogous to the lympho-sarcomatous observed by Hesse in Cobalt miner's lungs (*see* Cohnheim's *Pathology*, vol. ii., p. 743).

† It is stated that the fibres in these cartilaginous tumours do not swell up on treatment with acetic acid

Sometimes the matrix becomes very soft and the cells stellate and branched (myxochondroma); or the corpuscles multiply very rapidly forming in places typical spindle and round celled sarcoma tissue (chondro-sarcoma). In the latter case the tumour may grow rapidly and diffusely and find its way into the vessels and produce metastasis in distant organs such as in the lung and liver. Some of the most striking examples of distal recurrence are furnished by chondromata.

Much interest is attached to the chondromata on account of a mode of origin which throws light upon the etiology of tumours generally. They arise in connection with the bony and cartilaginous framework of the body, and at places where portions of this framework have become obsolete, viz., Meckel's cartilage and the branchial arches. The greater portion of the skeleton is prefigured in cartilage; in a few structures this persists throughout life as the normal tissue; in other places it persists for a very long time and is only late in life replaced by bone, *i.e.*, rib cartilages; by 25 years of age the cartilage of the majority of the epiphyseal lines has ossified, and already in the new born most of the skeleton is bony. There is much evidence to support the view that small portions of cartilage may here and there still persist in the skeleton and not disappear; thus Virchow pointed out small remnants or "rests" of cartilage in the medulla of long bones, where it is well known that cartilage tumours arise and cause great expansion of the bone outside them; further the other situations in which chondromata occur, viz., in the periosteum (*perichondromata*) and close to the ends of bone also favour this view.* The

* The term *chordal chondromata* has been applied to the cartilage

chondromata are frequently multiple and are limited in these cases almost without exception to the portions of the skeleton which are prefigured in cartilage and where therefore one would expect to find cartilage or cartilaginous rests; thus the base of the skull may in these cases be one of the seats of the tumours, the membranous portion being quite free. Stalked chondromata occur in the synovial fringes where normally a few cartilage cells may very often be observed. In the region of the parotid and side of the neck two classes of cartilaginous tumours may be said to be met with, one a deep variety, the other a superficial. The superficial occur most frequently as tag-like or polypoid masses of reticulate cartilage, both in the parotid region in the neighbourhood of the ear, and in the neck along the sterno-mastoid, where they are sometimes seated at the mouth of a congenital branchial fistula; they resemble ear-like appendages. The deeper variety also occur in the parotid and lower jaw region and side of neck; in the former situation Meckel's cartilage is looked to as the source of origin; in the neck the branchial arches. To the whole group the name of *branchial enchondromata* may be applied.

Cartilage formations occur in the kidney and testis, and their presence is here explained by their close proximity to the spine (in the case of the testis in early fœtal life).

The *ecchondroses* form a group of cartilage tumours

tumours of the ventral aspect of the spine. It would be an error, however, to suppose that they are derived from remnants of the notochord which is a non-cartilaginous structure. They are probably derived from the early cartilaginous framework which surrounds it.

which take their origin from the cartilage of the ribs, larynx and trachea, intervertebral discs, lines of union of epiphyses, &c. They show a marked tendency to ossify (*ossifying enchondromata*). After these come the tumour-like hyperplasias which arise most frequently in connection with some form of chronic inflammation, the commonest examples being furnished by the joints in rheumatoid arthritis. A fracture may become the seat of a very large over production of cartilage (traumatic enchondroma).

Osteomata.—The osteomata are for the most part simple tumours which possess a structure usually resembling that of cancellous or compact bone; in some situations they are extremely hard and eburnated, and in a few cases they have had a dentine like structure. In the teeth *odontomata* are not uncommon and consist of dentine. They are either laid down by the periosteum (periosteal exostoses) as in the case of the osteomata of the flat bones of the skull and of the shafts of long bones; or they commence as chondromata and proceed most commonly from the epiphyseal lines and places of origin of ecchondroses. This latter group, which have therefore a distinct mode of origin to the preceding, are usually polypoid and capped with cartilage and possess a cancellous structure continuous with that of the bone from which they arise; a familiar example is the exostosis of the distal phalanx of the great toe. Examples of the periosteal and eburnated exostosis are frequent on the membrane bones of the skull, in the orbit and in the various sinuses.*

* With regard to the origin of some of the cranial osteomata an interesting point will be raised in the chapter on congenital formations.

A most interesting fact in relation to bone tumours is the comparative facility with which they arise from connective tissue, most frequently that of tendons aponeuroses and muscles. The simplest are the *osteophytes* which grow out into the tendinous insertions of well-developed muscles, and the sesamoid bones of tendons which are developed at points of friction. Other more striking examples are furnished by the "Rider's" bone in the adductor muscles of those who ride much, and the "Exercise bone" in the deltoid of those who have to perform much shouldering of arms. In these examples frequent use seems to call forth the condition, but occasionally without any apparent cause a most wide-spread ossification of the muscular and aponeurotic connective tissue occurs (*myositis ossificans progressiva*).* Attention might be drawn to the comparatively frequent presence of bone in the eye (choroid chiefly) in chronic inflammatory and other conditions†; to its occasional presence in vessels without preceding calcification; and to the bone formations met with in the dura mater and its prolongations, in the meninges, and in the lung.

Calcified spots appear in many cases prone to ossify, examples occur in vessels, rib cartilages and in other situations.

Bony follows on cartilaginous hyperplasia in the great majority of cases. Osteophytes are frequent in tubercular, syphilitic and rheumatoid diseases of bones;

* There is a fine example of this in the museum of the Pathological Department of Trinity College, Dublin, and which is of further interest since it was described by Giraldès in the *Gaz. des Hôpit.* of 1863.

† Bone is normal in the eyes of some animals.

also after trauma (excessive callus), a good example being furnished by the bony hyperplasia which often occurs around a fractured rib in a lower animal. In man after bone injury a similar fact is often observed, and in a few cases the bone formation has been so great that it has been found impossible to decide whether it was "hypertrophied callus" or an actual new growth, an *osteo-sarcoma*. There are other cases as in the jaw and elsewhere where it is very difficult to decide between hyperplasia or osteo-sarcoma.

Lipomata.—The lipomata are fatty tumours, and as one might imagine from the wide distribution of fat are found in many places, but they also occur where fat is not normally present. As in the preceding tumours so here it is difficult to distinguish between hypertrophy and tumour formation. There is, for example, an important and curious class of *diffuse* fatty overgrowths which affect various regions of the body, and frequently symmetrically, viz., on each side of the ligamentum nuchæ, sides of the abdomen, &c. Allied to them are the fatty tumours very often observed in the posterior triangles in the necks of sporadic cretins. On the other hand the irregularly scattered multiple tumours are for the most part remarkably well defined; they are most usually found in the subcutaneous tissue and occasionally present the phenomenon of travelling from a higher to a lower position.

There are numerous other varieties of which the following are examples:—

Amongst negroes large fatty tumours often follow sticking skewers and other ornaments in the ears; a similar fact was noted in the case of fibroids, and

both are probably related to the irritation produced. Tumour-like hyperplasia, attaining in some cases a great size, may be produced by small pieces of omentum which have been incarcerated in hernias; similarly along the linea alba and in the palmar and plantar fasciæ, tumours are formed from at first minute protrusions of the sub-aponeurotic fat. On the abdomen these tumours may attain very considerable proportions; they all tend to support the view held by some that venous stagnation favours tumour formation, provided it is agreed that venous stagnation does occur from constriction at the hernial apertures. In infants a development of fat in the cheeks, the so-called sucking pads, sometimes reaches tumour-like proportions.

The appendices epiploicæ and the synovial fringes often develop into polypoid lipomata. In some pseudo-hypertrophies of muscle the new formed fat may constitute a tumour. Fœtal inclusions and teratomata oftentimes show a most remarkable proneness to the development of fat; most probably of this nature are the retro-peritoneal lipomata, which sometimes attain enormous dimensions and reveal their malignancy by the proportionate amount of wasting and cachexia which they induce in the rest of the body. Large masses of fat are frequently observed at the seat of a spina bifida occulta, which may even penetrate inside the theca. Polypoid masses of fat are occasionally associated with protrusions of the spinal or cerebral membranes, and fatty tumours may be found in the central nervous system.* The false tails in the

* For further information about these the student is referred to congenital formations.

region of the coccyx are small tag-like or polypoid masses of fat. The *myxo-lipoma* is looked upon as the most malignant variety. The so-called lipomata of the kidney are fatty patches which appear on and in the cortex of the kidney; some of them closely resemble infarcts. They are not lipomata but are in most cases due to fatty degeneration of *supra-renal "rests."*

Fatty growths are prone to calcify, and occasionally a soda or lime soap is formed in them.

Xanthomata are related to the lipomata. They are yellowish pale patches which are most frequently met with on the eyelids; they consist of reticulate cells filled with numerous fat droplets and pigment granules.

Myxomata.—The myxoma is a loose tissue growth, and consists of much ground substance and branching stellate connective tissue corpuscles. It occurs in connection with the sheaths of nerves, in cartilage, in fibrous and other tumours (chondro-myxoma, adeno-myxoma, myxo-lipoma, myxo-sarcoma, glio-myxoma, &c.), or as a distinct tumour, *e.g.*, in the peritoneum. Ingrowth into the vessels and metastasis is recorded.

Sarcomata.

Sarcomata arise from some form of connective tissue, the leading features of which they preserve. They are very cellular, infiltrate, grow rapidly, and as a rule at an early stage find their way into the circulation and give rise to secondary foci or metastases. They are the *malignant* forms of the simpler connective tissue tumours, and between them and the latter there is no sharp line.

There are therefore sarcomata of:—

1. Fibrous tissue (*fibrosarcomata* = round, spindle, branched and giant celled sarcomata).
2. Myxomatous and probably fatty tissue (*myxosarcoma*).
3. Bone (*osteosarcoma*).
4. Cartilage (*chondrosarcoma*).

Like their predecessors they occur either singly or multiple, and have a quite similar distribution. The same facts hold good too as regards their origin, namely, that "*remains*" show a marked tendency to become sarcomatous, and that there exists in many cases a close *relationship to inflammatory growth* (induced by trauma, &c.), there is now the further fact that the simple tumours very often indeed become malignant.

Fibrosarcomata.—These are very cellular growths, and the corpuscles of which they are composed vary in in size, just as granulation tissue corpuscles do, only in a more marked manner. The tumour may consist mainly of small and large *round cells*, small or large *spindle cells*, *branched cells* and *giant cells*, or several forms may occur together. In the recurrences and metastases the original type of cell very often changes, most commonly from spindle to round cells, a circumstance which very often coincides with increased malignancy. The place of origin influences the kind of cell formed, not only of course as regards the previously mentioned main divisions of sarcomata (fibro-, osteosarcomata, &c.), but also as regards the different varieties of fibrosarcomata; for example, giant celled sarcomata are almost peculiar to bone, where multinucleated forms are normal; pigmented sarcomata

(*melanotic sarcoma*) to places where pigment already exists; whilst round celled sarcoma occurs in lymphatic tissue and spindle celled sarcoma, very often in fasciæ, tendons and periosteal tissue; but it is characteristic of sarcomata, in this respect, for exceptions to abound.

The *stroma* varies in amount, sometimes it is very scanty, at other times abundant; it may have an almost structureless, shreddy or granular appearance, or there may be more or less fibrillation, either in the form of a network enclosing the cells, or in more wavy bundles resembing normal connective tissue. The formation of cysts may take place, derived more probably from enlargement of lymph spaces, than from softening in the stroma.

As in every growth of fibrous tissue, be it granulation tissue, hyperplasia or simple tumour, so in sarcoma the endothelial cells of the vessels of the sarcomatous tissue proliferate, just as the connective tissue elements of the growth, and form capillaries and large vessels. The walls of these may either consist of a loose investment of endothelial cells and ground substance, which may be undifferentiated from the ground substance elsewhere, or be more or less perfectly fibrillated. Or the endothelial lining may be more perfect, and the sarcoma cells immediately around may form an investment of spindle shaped cells, and thus give to the vessels a more normal appearance. Lymphatic endothelium most probably proliferates in the same way, but the result is so atypical that distinct lymphatic channels are not readily recognised.

The looseness of the vessel walls greatly predisposes to vascular dilatation (often enormous), to stagnation,

to the escape of leucocytes, and to blood extravasation (compare granulation tissue). It also greatly facilitates the sweeping into the circulation of sarcoma cells and their consequent wide-spread dissemination. So many sometimes get into the blood stream that veritable sarcoma thrombi are formed in distant veins; the cell emboli further grow through the vessel walls and invade the surrounding tissue. Occasionally large pieces get detached from the primary growth, and are caught in the trabeculæ of the heart cavities, where they contract adhesion to the muscle wall.

The more highly specialised tissues involved in sarcoma growth show most striking changes, principally of a *proliferative* and *atrophic* nature. For example, in sarcomata of the skin it is common to find at the edge of the tumour, where growth is most active, extensive epithelial downgrowth, nests even being formed (compare lupus); on the other hand, over the older portion of the growth, the skin is often stretched and atrophied. In a similar manner epithelial appendages (sebaceous and sweat glands and hair follicles) proliferate and atrophy. In glandular organs the gland cells increase, and in very many adeno-sarcomata, the gland change must be associated with that of the connective tissue. But in other cases, where glandular organs are invaded by sarcoma tissue, the gland acini may atrophy. Little is known as regards the new growth of nerve fibres, but muscle fibres undoubtedly do proliferate in certain congenital sarcomata, and form both smooth and imperfectly striated fibres, which are hard to distinguish from sarcoma cells (the cross striated muscle fibres may be very conspicuous); on the other hand, fibres invaded by sarcoma tissue soon atrophy,

and become pigmented or fatty, or are absorbed by the tumour cells.* Fat disappears. The connective tissue corpuscles in the neighbourhood undoubtedly proliferate, as they do in the vicinity of cancer, and may form at the margin of the sarcoma, a distinct *small round celled growth*, often to be distinguished by its staining more deeply with logwood. The rapidly growing sarcomata usually undergo as rapid central necrosis.

ROUND CELLED SARCOMA.—**Fig. 54** represents the margin of a round celled sarcoma of the skin. The sarcoma cells are for the most part grouped together, but there is no line of demarcation between them and the less cellular fibrous tissue in between and around. The appearance of the section is that presented by almost any connective tissue proliferation, and it would be impossible to say that it was sarcomatous without a knowledge of the naked eye appearances and history of the tumour.

Fig. 55 is a minute portion, more highly magnified, of the optic *nerve*, infiltrated by a round celled growth, which surrounds and isolates almost every fibre. The infiltrating property is very characteristic of this very malignant form of tumour. In the central nervous system, round and sometimes spindle celled sarcoma may form an almost gelatinous investment to the cord and base of brain, and the growth may penetrate in

* It must be recognised that there are cases in which glands, muscles, or other specialised tissues, become invaded by sarcoma, to the detriment of the former; and cases in which tumours, which are probably derived from rests containing both connective tissue and special tissue rudiments, are composed equally of proliferating special tissue cells and sarcoma cells. To these latter tumours the term mixed sarcomata might be applied, and they would include the adeno-sarcomata, carcino-sarcomata, myo-sarcomata, &c.

between the nerve fibres as above, or may seek out the vessels and run along their lymphatic sheaths and give rise to an appearance closely resembling a leucocytic collection (*see* figure of hydrophobic cord). Sarcomata which arise in nerve matter or in the retina are usually called *gliomata*.* In muscle the same infiltrating character is beautifully seen, and perhaps nowhere so strikingly as in the *Heart*. In this organ a round celled growth may spread down from the root of the great vessels—starting perhaps in the remains of the thymus—and may follow the coronaries and their ramifications, and then penetrate in between each fibre, isolating it and causing its atrophy. Such a heart may suddenly rupture, and at the autopsy so inconspicuous may the macroscopic signs of disease appear, that not till after microscopic examination is the cause of rupture discovered; albeit this same infiltration is often described as syphilitic. In like manner sarcomata force their way through bone and dense tissue like the sclerotic.

In the *lymphatic tissue* of the alimentary canal, a multiple form of tumour may occur, which may give rise to enlargement of the tonsils, diffuse and nodular growth in the stomach, and great enlargement of Peyer's patches and the solitary glands, together with enlargement of the mesenteric glands. Similar malignant round celled growths may arise in the lymphatic gland tissue elsewhere. It constitutes the so-called *lympho-sarcoma*.†

* The term should be reserved for those tumours which arise from the special supporting tissue of the central nervous system and retina.

† Lympho-sarcoma is more than a special variety of sarcoma, since it is derived from a special tissue; it will be discussed separately. The round celled growth described above in the heart and the perilymphatic growths in the central nervous system are probably lymphosarcomata.

FIG. 45. INFILTRATING SARCOMA OF OPTIC NERVE.

1. Nerve fibres.
2. Sarcomatous infiltration.

Obj. $\frac{1}{2}$ in., with eyepiece. (Carmine).

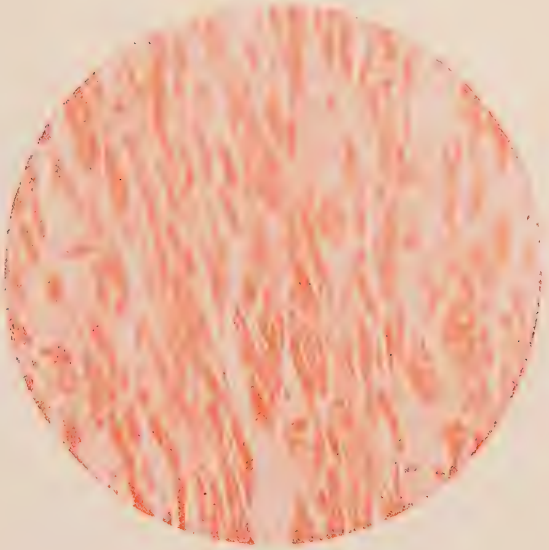

FIG. 46. SPINDLE-CELLED SARCOMA.

Obj. $\frac{1}{2}$ in., without eyepiece. (Carmine).

with which they form together one large characteristic group.*

Giant celled or myeloid sarcoma.—This growth consists of various forms of cells, giant cells, as in **Fig. 57,** being diagnostic. It arises pre-eminently from bone, either in the medulla, causing great local expansion of the bony wall, and where it is very rich in giant cells, or from the periosteum containing fewer giant cells. They are exceedingly vascular and may pulsate. They are the least malignant of the sarcomata, and in the mouth when arising from the periosteum of the jaws they give rise to one form of *epulis*. Occasionally they have no connection with bone, exceptions which are not surprising, seeing that ordinary granulation tissue and simple tumours are often rich in multinucleated connective tissue corpuscles.

Chondro-sarcoma.—The chondro-sarcoma usually consists of an imperfect and cellular cartilage, whose cells may be encapsuled, **Fig. 58,** or non-encapsuled, round or stellate. Transition to a round and spindle celled sarcoma may sometimes be seen, both the cells and matrix changing, the latter becoming coarsely or finely fibrillated or softening.

Osteo-sarcoma.—The bone skeleton of the osteo-sarcoma left after maceration consists of beautiful spicules of bone which radiate and branch from the parent bone. Decalcified preparations show delicate trabeculæ usually perpendicular to the old bone, and between them a very cellular tissue containing spindle and round cells, osteoblasts and osteoclasts, the two

* The "recurrent fibroid" of Paget is a half-way tumour between the simple and malignant varieties. It recurs locally to a remarkable extent, but does not, till very late, form metastases.

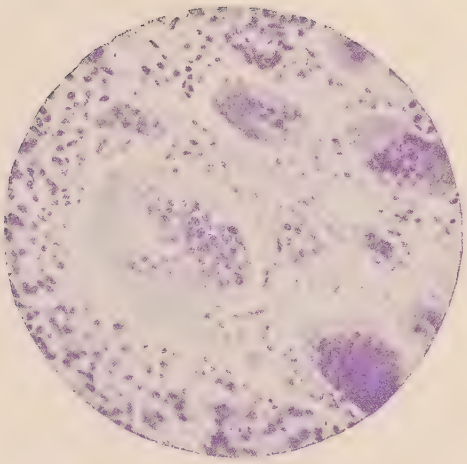

Fig. 57. GIANT CELLED SARCOMA

Obj. $\frac{1}{8}$ in., without eyepiece. (Logwood.)

Fig. 58. CHONDRO SARCOMA

Obj. $\frac{1}{8}$, without eyepiece

latter elements often being at work on the same trabecula, one forming the bone the other absorbing it. In their growth they replace the old compact bone; and they form metastases.

Allied to this tumour is one in which *calcification* of the matrix occurs, the same tendency being repeated in the secondary growths (*calcifying sarcoma*).

NOTE.—ALVEOLAR SARCOMATA and ENDOTHELIOMATA are described later on under carcinomata for reasons there stated.

SIMPLE AND MALIGNANT EPITHELIAL TUMOURS:—

1, of *epithelial surfaces* { stratified. / columnar. / serous or endothelial.

2, of *glands*.

I. SIMPLE TUMOURS OF THE EPITHELIAL SURFACES.—There are three great varieties of lining or covering epithelium, viz.:—

1. The *stratified*, including stratified *horny* and stratified *mucous*. Examples:—Skin, mucous membrane of mouth; part of the nose and larynx; pharynx and œsophagus; vagina and vaginal portion of cervix; bladder, ureters and glandular portion of urethra.

2. The *columnar*. Examples:—Stomach and intestines; respiratory tract, including upper part of nose, lower part of larynx and the trachea and bronchial ramifications (the alveoli and vocal cords are covered by flattened epithelium); genito-urinary tract, including uterus and tubes, seminiferous ducts, major portion of the urethra; spinal canal.

3. The *serous* and *endothelial*. Examples:—Peritoneum, pleura and pericardium; synovial cavities;

meninges; lining of ventricles; endothelial lining of the larger vessels.

Where these epithelial surfaces are subjected to chronic "irritation" or "inflammation" they are wont to undergo certain interesting and important structural alterations, the most marked examples of which have been termed precancerous changes, because they are often followed by cancer. They correspond to the hyperplastic changes which have already been studied in the preceding groups, and they are usually at the same time associated with fibrous and vascular hyperplasia.

Although, with a few exceptions, the above three types of epithelium are normally distinct from one another; yet under certain pathological conditions the differences tend to disappear; this deviation from the parent type of epithelium is often as strongly marked in simple hyperplasia as it is in the malignant growths. Numerous examples will make these points clear.

A. *Warts, papillomata and hyperplastic changes due to chronic irritation or inflammation.*

1. In *skin* { Horns. Papillomata. Warts, &c.
2. In *mucous membrane* { Dermoid changes. Papillomata, &c.
3. In *endothelium.*

1. Skin.—The *corn* is a simple example of a local and uniform epithelial hyperplasia with excessive formation of horny material. A section closely resembles that through the outer portion of a sebaceous cyst (see fig. 81); the epithelial papillæ are obliterated and on the one side the Malpighian layer is sharply defined

from the stroma, though dipping down into it somewhat, whilst on the other it passes into the horn cells and amorphous horny material.

In the *Horn*, which frequently arises from a "sebaceous" cyst or old scar, the horn formation is carried to a much further and more perfect state. It will be referred to again under hair follicle cysts in the chapter on cysts.

The *papilloma* **Fig. 59.**—Covering a characteristically branching outgrowth of vascular fibrous tissue is the stratified epidermis, which no longer possesses an uniform appearance, but is marked by extreme irregularity; thus in places the epithelial papillæ are greatly exaggerated being broad and polypoid and penetrating deeply into the stroma, whilst elsewhere there is considerable thickening of the epithelium and obliteration of the connective tissue papillæ. Under a higher power the horny, eleidin and Malpighian layers are very distinct. As previously mentioned, p. 137, this specimen is a fragment of a very large papilloma which grew from a point of irritation on the scalp. But the favourite seats of these tumours are moist and dependent surfaces, such as the *labia*, *corona glandis* and margin of *anus;* irritating secretions, the chief of which, the gonorrhœal, inducing them. In these situations there are all transitions between the loose branching papilloma, the close set wart and the spreading warty growth or *condyloma.* All are exceedingly vascular and numerous delicate and dilated capillaries run up between the epithelial papillæ to close under the surface, consequently they readily bleed; and hæmatoidin crystals are often to be found in them. The epithelial cells are loose, the prickles are greatly

developed and there is little horny transformation, so that the tumour is always moist. There is usually considerable leucocytic infiltration and small round celled proliferation.

The *wart* **Fig. 60,** also see fig. 63. There is not the same outgrowth of fibrous tissue as in the papilloma, but instead the epithelium is in great excess and grows more irregularly and forms papillomatous, polypoid and even isolated masses in the sub-epithelial stroma. The whole forms a circumscribed growth, projecting above the surface of the skin. Peculiar concentric bodies, *nests* or *pearl bodies* (fig. 64) are very common; they are formed in the epithelial masses by epithelial cells which elongate and imbricate, and then with their nuclei loose their structure and staining reaction and pass into a material similar to that of the horny layer of the cutis or of the wall of a sebaceous cyst. Sometimes however this product is not horny but soft, so soft in fact as to give rise to an actual *cyst*, or it may when soft be formed in such abundance as to constitute the characteristic feature of the wart—for example perhaps in *Molluscum contagiosum*. The forms of the epithelial cells vary just as they do in cancer. Like congenital pigmented warts, inflammatory warts may be deeply pigmented especially when they arise in the neighbourhood of pigment, as on the cornea in the eye. Warts are common on the hands and scrotum, but tend to become more papillomatous or condylomatous on the moister parts; sometimes on the penis there may be a more uniform local hypertrophy of the epidermis (psoriasis preputialis). A very common cause of their production is working in tar, paraffin and soot, it is also worthy of note that the internal administration of

Fig. 59. PAPILLOMA OF SCALP.

The branching fibrous stroma is covered by an abnormally thickened irregular epithelium.

Obj. 4 in., without eyepiece. Logwood.

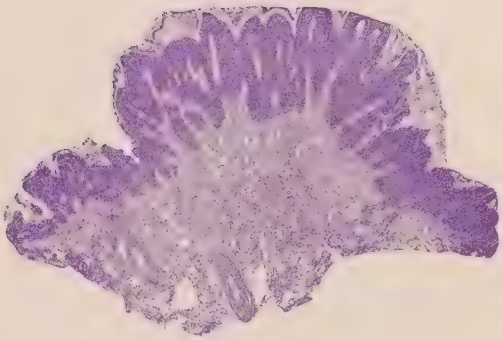

Fig. 60. SIMPLE WART OF SKIN.

This figure shows a much greater preponderance of the epithelial change than does the preceding figure.

Obj. 4 in., without eyepiece. Logwood.

arsenic is said to produce a warty keratosis, and further that in molluscum contagiosum a parasite is probably the irritant.

The marginal epithelium of *simple chronic ulcers* or of *syphilitic*, *lupoid* or *perforating ulcers* and of *fistulæ* may show very considerable proliferative changes, the papillæ growing down into the granulation tissue, loosing themselves in the general cell hyperplasia or forming nests.

2. Mucous Membranes.—In mucous membranes dermoid changes are much more apt to manifest themselves over a wider area in the form of uniform hypertrophies, than is the case in the skin where localised papillomatous and warty types are commonest. These flattened warty conditions have received the name of *psoriases*, and it is to them more especially that the term *precancerous* was applied. The following are instructive examples :—

As the result of irritation, smoking or syphilis, a patch of the epithelium of the tongue may become horny, a section completely resembling that through a thick portion of skin, with its eleidin and horny layers. The papillæ tend to become flattened and the epithelial patch which is thickened, whiter than normal and more smooth or cracked, has received the various names of *psoriasis lingualis*, *leucoplacia* and *ichthyosis linguæ*.

In the nose as a result of chronic ozæna the same obtains (*psoriasis nasalis*). In the larynx, resulting from chronic irritation and inflammation a similar condition known as *pachydermis laryngis* (Virchow) may occur. In the *uterus* in cases of chronic endometritis a typical horny epithelium may form. The mucous membranes of the vagina and cervix when prolapsed are

wont to become horny. *Polypi* of the nose, interior of uterus and rectum (also piles) when projecting and subjected to friction and irritation become covered by a skin-like epithelium. The epithelium of the *urethra* at the seat of a stricture is often typically stratified and horny, and in tubercle of the pelvis of the kidney an associated hyperplasia and keratosis of the epithelium has been recorded. The margin of simple, syphilitic and tubercular ulcers of the larynx and pharynx show changes corresponding to those observed under similar conditions in the skin.

Papillomata.—A large proportion of the papillomata of mucous membranes fall under fibromata. But certain of them, especially those that are thick set, viz., *cauliflower* growths, show marked epithelial changes. **Fig. 61** represents two tags of a *papilloma of the bladder* (not however cauliflower-like). An extremely delicate stroma 2, which carries a looped capillary, is covered by a rich investment of cells 1, which are more numerous and otherwise differ from those of the bladder wall. In the respiratory tract papillæ of columnar surfaces are often covered by stratified epithelium, and horny papillomata have been observed in the upper nasal cavity.

3. Serous and endothelial surfaces.—As the result of chronic inflammation, the previously flattened epithelium of the pleura, pericardium or peritoneum may become cubical and proliferate. Similarly the pulmonary alveoli may be lined by cubical epithelium, and I have even observed a lining of large slightly irregular goblet-shaped cells; further proliferative changes in the lung may give rise to small *adenomata* and *papillomata*. Also under certain conditions the

Fig. 61. PAPILLOMA OF BLADDER

1. The stratified covering epithelium.
2. The central connective tissue and vascular core.

Obj. ½ in., without eyepiece. (Carmine.)

Fig. 62. SQUAMOUS CANCER OF CERVIX UTERI.

1. Normal stratified epithelium.
2. Malignant epithelial growth.

Magnified four times. (Eosine and logwood.)

endothelium of the vessels may proliferate and become stratified.

B. In order to make the introduction to the malignant growths complete, certain EPITHELIAL FORMATIONS must be considered, which are either formed early during the development of the embryo and are therefore *congenital*, or arise in later life from accident. The chief examples are *warts*, *moles* and *papillomata*, and "*remains*" or "*rests*."

Congenital warts, *moles* and *papillomata*.—In structure the congenital wart differs from that of the irritative one; the epithelial overgrowth is usually not so great; the corium is rich in corpuscles, scattered or in groups, which often resemble small sarcoma or epithelial masses; *pigmentation* in the epithelium and stroma is common, and *hair* and sebaceous glands may be very abundant, *ex.*, the mole. Sometimes a *nævoid* condition obtains and in certain localities *cartilage* remains may be found. The congenital wart is in fact a tumour nursery, from which a sarcomatous, epitheliomatous, chondromatous, or nævoid growth may at any time arise. They occur scattered, and a mole may even grow on the conjunctiva or in the mouth.* Very extensive congenital warty patches are sometimes found along the side of the neck, but they may also occur on the arm, &c.

Remains or Rests.—The prettiest examples of these are the *paradental* epithelial nests found in the bed of the teeth, they are very evident and have been probably left over during the formation of enamel. Other ex-

* For further information consult chapter on congenital formations.

amples occur as minute epithelial projections along the palate and other fissural lines, and they are also very probably present as isolated nests in congenital warts. The remains of the cranio-pharyngeal and lingual canals, &c., are further examples. In adult life "rests" are frequently encountered in the lines of old incisions and punctures* and are due to excess of repair tissue. Lastly it must not be forgotten that it may be possible for epithelial germs to find their way into distant tissues, such as into lymph glands, and there to lie unobserved till the formation of a sebaceous cyst, or of an anomalous primary epithelioma draws attention to the possibility.

Cancer.

The preceding large classes of irritative and congenital epithelial tumours may proceed to malignancy, and it is worthy of note that differences appear between the resulting growths in the two cases. Thus cancer which arises as the result of chronic irritation may be multiple ; a comparatively large area of epithelium may become malignant, superficial spreading is wont to occur, and as Rudolf Volkmann has emphasized, it is less malignant in the sense that it does not often recur either locally or distally.†

* Sutton traces certain cysts to these minute epithelial inclusions; indeed "rests" are the progenitors of a very wide class of cystic formations, amongst which "Dermoids" occupy a prominent position.

† We believe it is possible in many cases to distinguish between the congenital and irritation varieties from anatomical appearances. Irritation may of course act on congenital epithelial rests, just as it may on normal epithelium, and we think evidence of this is furnished by the enamel germ tumours.

THE MALIGNANT TRANSFORMATION.—The simple projecting wart or papilloma, whatever its origin, still furthers irritation by its greater liability to friction and by its harbouring dirt and sweat; similarly the hard psoriatic patch on the tongue, in that it is unsuited to the incessant movements of that organ, can only increase irritation. Then comes a point when the innocent formation becomes malignant. It is not marked by an increase in size of the projecting papillæ, or of the wart as such, or of the psoriatic surface; on the contrary these more highly organised states tend to vanish, all force being concentrated in a new and rapid proliferative downgrowth of epithelium, tending to the wide infiltration of the stroma and to the atrophy and destruction of whatever resists its growth. In the meantime the starting place, if an exposed surface, has become the seat of a malignant ulcer, and sooner or later epithelial germs will, in a great number of cases, have found their way into the lymphatics or into the general circulation, to form metastases in the nearest glands or in distant organs.

Figs. 62 and **63** illustrate exceedingly well some of these points. The first figure is a cancer of the cervix uteri, 1 points to a normal epidermis, 2 to a large mass of growing epithelium continuous with the former, but which has penetrated deeply into the uterine stroma and has ulcerated on the surface. The second figure is a section through a nympha at the site of commencing malignant disease. At 1 the epithelium is normal; at 2 there is a most marked wart-like condition, the epidermis no longer being uniform but broken up into irregular clumps which penetrate into the corium for some distance; at 3 the departure from the normal is

at its greatest for the stroma is infiltrated by ramifying epithelial strings and nests whilst the free surface has ulcerated.

The malignant transformation is just the same whether arising from columnar, stratified or serous epithelium, but as the resulting cancer takes over with it certain parental peculiarities so it is customary to make the following divisions :—

1. *Squamous epitheliomata.*
2. *Columnar epitheliomata* (atypical).
3. *Endotheliomata.*

1. Squamous epitheliomata.—*Regions.*—1. Tongue, jaw, lips. 2. Larynx, pharynx, œsophagus. 3. Face, extremities. 4. Cervix, vulva, penis, scrotum, bladder, &c.

For microscopic examination every endeavour must be made to get at the starting point of the growth, which in the majority of cases (irritative epitheliomata) can be clearly and directly traced to the epithelium or its appendages; when however it springs, without known cause, from a minute point in the skin, as frequently occurs on the back of the hand, this connection is not traced, for the original point has ulcerated and the skin around is in no way connected with the growth, and apart from the atrophy and destruction caused by the undermining cancer it is normal.

The epithelium grows into the stroma in the form of large ramifying cylindrical processes of epithelial cells set close together, the prickles however being often well marked. Here and there in the processes are the "*nests*" already mentioned under warts, only they are here as a rule more numerous, though they may be completely absent in certain varieties; they are composed of well-defined imbricating cells, or more

Fig. 63 CANCEROUS TRANSFORMATION OF THE EPITHELIUM OF THE LABIUM MINORIS.

1. Normal epithelium.
2. Warty condition.
3. Malignant change.

Obj. 4 in., without eyepiece. (Logwood).

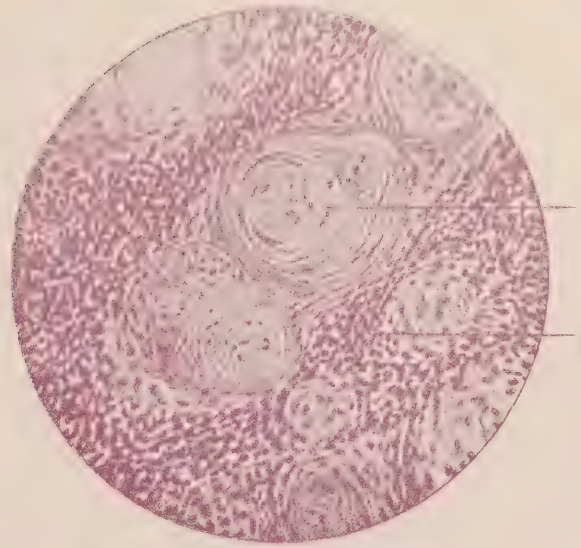

Fig. 64. SQUAMOUS EPITHELIOMA OF SKIN

1. Modified epithelial cells.
2. A nest.

Obj. ¼ in., without eyepiece. Eosinated logwood.

rarely of large undifferentiated multinucleated giant cells.* Very commonly the nests are horny as in **Fig. 64,** 2, or the contents are fatty and atheromatous; occasionally a more mucoid material is found in which case cysts are apt to arise. The connective tissue stroma between the epithelial ramifications is compressed and very often, especially in exposed places, abundantly infiltrated with small round cells—leucocytes, fibroblasts, endothelial cells and often *groups of giant cells;* if the growth of the tumour is not very rapid, the granulation tissue tends to condense into a harder limiting fibrous capsule. Muscle and gland tissue soon undergo atrophy and destruction before the malignant growth, and the first sign of this change, as is so often the case, is a proliferation of the nuclei. The adult cancer cell like the adult sarcoma cell is very prone to necrosis; this is seen on the surface of the tumour where the necrosing and infiltrated epithelium together with the infiltrated stroma break down to form the floor of the malignant spreading ulcer; it is also seen deep down in the tumour both in the nests and in the epithelial processes of which *one side* may sometimes be seen passing into a soft homogeneous material, which is liable to become actually organised; whilst the *other side* (Malpighian layer) is sharply defined from the stroma. The epitheliomata offer very different degrees of malignancy, they may remain local usually growing slowly (in one rare form they grow acutely); more commonly however the nearest lymphatic glands are the seat of a secondary plexiform epithelial growth and of nests as in the parent tumour. Metastases in more distant organs tend to become

* It is doubtful whether these are comparable to nests.

more atypical, though perfect nests may form for instance in the liver.

Varieties.—The variations in cell growth and form is very great.* In **Fig. 64** the epithelial cell outlines, 1, are ill-defined and the nuclei are oval. In some tumours the cells may be typically spindle-shaped and actually run in different directions in the same process simulating a sarcoma, except in the generally well-defined Malpighian layer; the cells in the interior of a cylinder may be stellate and branched (exaggerated prickles), and the structure may closely resemble that of the enamel organ and indeed such tumours are very frequently (though not exclusively) met with in the gums arising from its epithelium or from rests (paradental, &c.); they are the "*enamel organ tumours*," and have in addition a *plexiform* or net-like arrangement, whilst the stroma around is often *myxomatous*, and *cysts* may form in this as well as in the epithelial processes. In some plexiform epitheliomata the stroma around the epithelium becomes hyaline and one form of *cylindroma* results. In others occurring in the skin the tumour assumes a plexiform and stringy appearance, and where it is not proved in connection with the skin it has been regarded as an endothelioma of the lymphatics (*plexiform sarcoma*). Corresponding to the simple epithelial pigmented tumours, there are well marked *melanotic epitheliomata* which arise from moles and the sclerotic.†

Rodent Ulcer **Fig 65.**—This slow growing cancer of

* The tendency appears to be for the tumours to follow the type of epithelium from which they arise.

† The term *branchiogenous carcinoma* has been applied to certain epithelial tumours of the neck region which appear from their

irritative origin, frequently assumes a type of its own having a scirrhus- or lymphatic-like growth. It is composed of small cells and the stroma is often hard, fibrous and non-cellular, or rich in spindle cells. It originates probably from the Malpighian layer or the epithelial appendages.

Paget's Disease.—A superficially spreading growth, first described by Paget,* around the nipple. The cells are small as in the preceding case but they tend to group themselves in an alveolar fashion, they thus resemble the encephaloid rather than the scirrhoid type as above. It originates from the skin and its appendages, and it is of further interest as Darier and Wickham hold that it is produced by the irritation of *Psorosperms* (coccidia).†

Cholesteatomata or Pearl Tumours.—The term cholesteatoma is most frequently used in connection with chronic inflammation of the middle ear, where the epithelium as the result of chronic inflammation becomes stratified and horny. The products of desquamation accumulate and form the characteristic sebaceous-like debris in which are found cholesterin crystals (hence name), detached cells, and cells rolled up into balls or nests which often have a shining mother-of-pearl appearance, a fact which has given rise to the second

origin to be related to the branchial sinuses. There are thus branchiogenous chondromata, branchiogenous carcinomata and branchiogenous cysts.

* And later in the scrotum by Dr. Crocker, to whose kindness I am indebted for sections.

N.B.—It must not be confounded with Paget's disease of bones ("osteitis deformans").

† Smaller and larger coccidia-like bodies have now been found in almost every epithelial growth, but the observations appear of little value.

name—"pearl tumour." The same process is very prone to occur anywhere where the debris of an irritated and stratified surface can accumulate, as for instance the smegma præputii under a long foreskin, smegma umbilici, &c. I have observed the same in a very old epithelial lined sinus of the leg, from the bottom of which typical nest-like pearls could be scraped out. They are further found in the contents of dermoid cysts and have been recorded in the frontal sinus, pelvis of the kidney, &c.

Both the above names were however long ago originally given to epithelial and pearl-like accumulations of cells both in the *membranes and substance of the brain*, where some appear to be the nests of true epitheliomata, but the majority mere isolated collections of cells. Touching their origin in the brain, all that can be said is that considering the great number of dermoid formations of one sort or another which may be found in similar situations, it is likely that they originate from epithelial rests; but as there is evidence of the stratification of the dural and arachnoidal endothelium, an endothelial origin can also probably occur.*

Columnar Epitheliomata (atypical).

The great majority of tumours which arise from a columnar surface assume a branching cylindrical or alveolar form and are composed of closely set masses of cells. Nests are not formed—at least bearing the epidermal forms found in the squamous epitheliomata—but concentric arrangement of cells may occur. Glands also furnish epitheliomata of this atypical type, and

* Some consider that they are derived from the vascular endothelium.

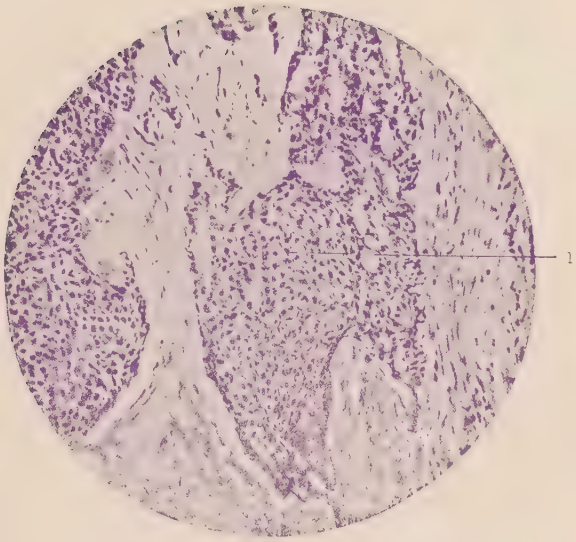

Fig. 65 RODENT ULCER OF CHEEK

1 An epithelial process

Obj. ⅓ in., without eyepiece. (Logwood)

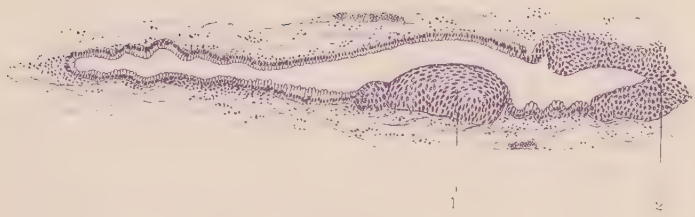

Fig. 66 UTERINE GLAND.

Showing very early malignant overgrowth of the columnar epithelium at 1 and 2

Obj. ½ in. with eyepiece. (Logwood)

more especially the glands of the *skin*, *uterus* and *mamma;* these will however be treated more fully under the gland tumours as they naturally follow after the *typical columnar epitheliomata* or *malignant adenomata.*

The atypical columnar epitheliomata stand in the closest relation to chronic inflammation, and this is nowhere so well seen as in the Uterus, where for instance on the surface of an irritated polyp, the columnar epithelium *stratifies* and then grows deeply into the stroma. In **Fig. 66** this change is remarkably clear.* The figure represents a complete uterine gland the mouth of which, 1, is stopped by an epithelial overgrowth of the columnar lining, and on whose wall at 2 a plaque of proliferated epithelium has formed in the midst of typically columnar cells. It is the commencement of a cancerous change, which elsewhere in the uterus has advanced to completeness. Where the change is complete the glands have been converted into solid epithelial cylinders; these together with the proliferating epithelium on the surface, have branched deeply into the stroma, and have formed a carcinoma like that represented in **Fig. 67,** taken from another case.

Endotheliomata (Sarco-carcinomata, &c.).†

1. Of the *peritoneum*, *pleura* and *pericardium.*—A condition of the peritoneum or pleura closely resembling a miliary tuberculosis, occurring in a person of advanced

* For this beautiful specimen, and for the kind permission to examine his very large collection of sections of uterine diseases, I am indebted to my teacher, Dr. John Williams, to whose work, "Cancer of the Uterus," the student is referred for further information.

† It will be seen from the text that these tumours are better grouped amongst the epithelial formations than amongst connective tissue tumours.

age and associated with old standing *chronic inflammation*, should be most carefully examined, since it is quite possible that *endotheliomata* may occur in this multiple form.* The tumours in these cases consist of overgrowths of cubical cells derived from the serous epithelium, and they form small cylindrical processes which penetrate into the stroma. A somewhat similar condition—perhaps only a hyperplasia—may be confined to the ovary. It may also occur as a superficially wide-spreading growth.

2. Of the *Brain and its membranes.*—A probable miliary endothelioma of the pia mater has been described, but much further information is wanting. Usually the endotheliomata of the brain, *and of the dura mater* more especially, are large solid epithelial and branched growths, in which nests sometimes appear, indeed some bear a very close resemblance to epitheliomata (squamous), and may originate from epidermal rests; the latter origin is most probable in connection with the endotheliomata of the petiosteum of the skull and face bones.

3. Of *vessels and lymphatics.*—

Endotheliomata { intravascular.
extravascular = angio-sarcomata.

Intravascular endotheliomata.—These are the most interesting of the whole group. They commence as endothelial proliferations, which grow out from the walls of the *veins*, and form branching plugs of cubical

* As one would expect, the large serous cavities, including the arachnoidal, are prone to miliary lesions. The commonest cause is tubercle, but an *animal parasite*, as seen in a former chapter, is a possible source; secondary simple and malignant growths of all kinds are very common in this form.

and other cell forms (giant cells), which nearly or completely fill the lumina of the vessels. Usually however the growth is not so abundant, and it may at the same time be associated with a remarkable dilatation of the lumina or with a true *cavernous formation*. Cells naturally get readily swept away, and lodging in the minute vessels, they probably form other cellular or cavernous structures like the parent growth. Sections of young cavernous tumours have been described in which the similarity to gland acini was very marked, especially as the lumina in some cases were filled in addition with a gelatinous material.* Cavernous tumours have been described in the penis; similar formations have also been well described in the ovary, arising both from the vascular endothelium, and leading to a cavernous structure; and from what the authors call lymphatic epithelium leading to cavernous lymphomata.

Lastly, Langhans many years ago described a rapidly growing *cavernous angioma* of the spleen, in which the growth seemed to be centred in the proliferating endothelium; what appeared to be secondary growths were found in the liver, they were very cellular, and could be traced to start from the walls of the portal and hepatic veins; in all cases cavernous dilatation and atrophy of the intervening trabeculæ followed rapidly upon the peripheral cell growth. Unaware of the preceding case, I had come to the conclusion, from sections of hepatic *nævi*, that at least some cavernous nævi of the liver, and probably of other organs, were in reality *endothelial new formations*, occurring in a multiple

* This peculiarity, if genuine, naturally reminds one of the fact previously observed of the hyaline and colloid-like changes in angiomata.

form or capable of metastasis.* To some of the above points reference will be made in the chapter on *cystic* formations.

EXTRAVASCULAR ENDOTHELIOMATA—angio-sarcomata. Two forms of tumours have been described. 1. Epithelial-like tumours which grow into the stroma and are supposed to originate from vascular or lymphatic endothelium. 2. Tumours which take the form of a cylindrical epithelial investment to a minute vessel and its branches. Reference has already been made to this form.

GLAND TUMOURS
- Simple adenomata.
- Malignant adenoma, columnar epithelioma, scirrhus and encephaloid.
- Cystic.†

Examples of the GLAND TISSUES are the Sebaceous, Sweat, and Mammary glands. Glands of the Alimentary and Respiratory tracts. The Liver, Kidney, Suprarenals, Thyroid and Parotid. Glands of the Uterus, Tubes, Prostate and Urethra (Cowper's gland, &c.). Glands of the Ovarian and Testicular regions. In addition to these, it is very important to bear in mind, just as in the case of the tumours of epithelial surfaces, that there are numerous *gland* and *duct rests* which may become the seat of simple, cystic or carcinomatous growths.‡ Examples of these are the *Pituitary body* and *Pharyngeal diverticulum* (cystic,

* M'Kee in the "Trans. Roy. Acad. of Med." in Ireland, 1889, describes multiple endotheliomata of probably the portal veins.

† Cystic formations will be described in a separate chapter.

‡ Further information will be given in the chapter on congenital formations.

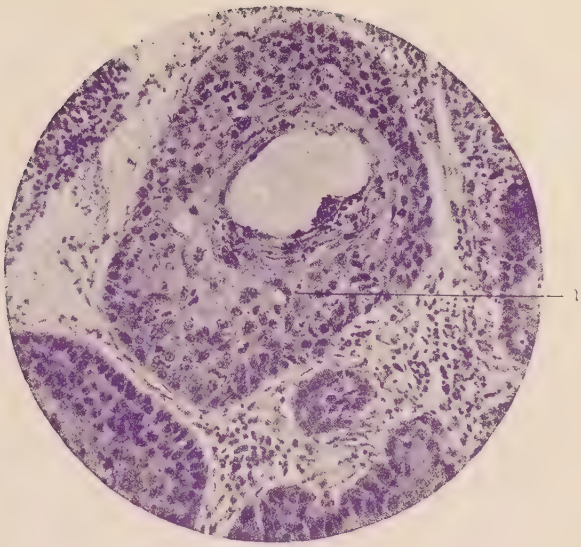

Fig. 67. ATYPICAL COLUMNAR EPITHELIOMA DERIVED FROM UTERINE GLANDS.

1. The cancer cylinder.

Obj. $\frac{1}{4}$ in., without eyepiece. (Logwood.)

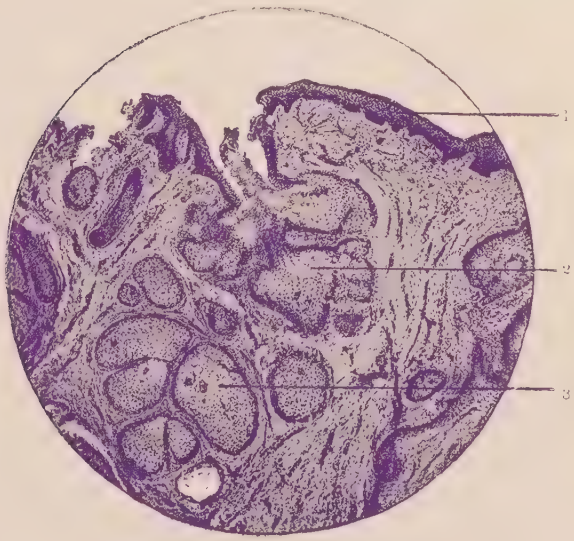

Fig. 68. SEBACEOUS ADENOMA (Lipoma nasi) OF NOSE.

1. Epithelium.
2. Gland acini.
3. Points close to the position of some demodices folliculorum.

Obj. 1 in., without eyepiece. (Logwood.)

adenomatous and hyperplastic, dermoid and carcinomatous tumours). *Pineal gland* (adeno-sarcoma, cysts and dermoid growths). *Thyreo-glossal duct* (dermoid and cystic tumours); *Accessory thyroids*, supra- and præ-hyoidal, &c. (hyperplasias and adenomata). All the above remains are derived from epiblast. The *Urachus* (cysts). *Vitello-intestinal duct* (adenomata, cysts and columnar teratomata). *Post anal gut* or *Luschka's gland* (adenomata and columnar teratomata). *Ovarian region*—Hydatid of Morgagni, Epoophoron, Wolffian duct and Paroophoron (adenomatous and cystic formations). *Testicular region*—Hydatid of Morgagni, Müller's duct, Paradidymis or organ of Giraldès (adenomata and cysts). *Accessory Suprarenals* which have an extensive distribution (adenomata, carcinomata, cysts ?). *Hepatic* and *Prostatic* rests. Many of these examples clearly show that in the formation of special organs and glands, parts are apt to become detached from the main mass.

Irritation and Chronic inflammation play a most important part in the production of hypertrophic, adenomatous and cystic changes, and examples are to be seen in almost every chronically inflamed or irritated glandular surface or organ. Many of these conditions are precancerous, proceeding to carcinoma. Thus in the *Kidney*—in chronic nephritis, cystic and adenomatous growths are frequent. In the *Liver* the bile ducts may proliferate and become cystic as a result of chronic inflammation and the presence of parasites, whilst in the *gall bladder* or larger ducts as the result of the irritation of a stone, a hyperplastic condition may pass into the cancerous. In the *Uterus* and *Tubes*, as a sequence of chronic endometritis or salpingitis, hyperplasia and

adenoma are very common; in the uterus, in addition, a glandular cancer may occur, fig. 66. In chronically inflamed *Lung*, both the small glands of the bronchi and the alveoli are the seat of cystic, papillomatous and adenomatous changes. In the *Alimentary canal*, the formation of cystic, adenomatous and carcinomatous states stands in direct relationship to chronic inflammation and irritation. Lastly, papillomatous and polypoid conditions of glandular surfaces predispose to tumour formation.

Hypertrophy and Adenoma of Sebaceous Glands.—These conditions are very frequent, and occur either locally, as in "Lipoma nasi" (Acne rosacea) or multiple, scattered over the body; usually, however, they are more often limited to the head and neck. Occasionally on the scalp they attain a great size. **Fig. 68** is a section through a "lipoma nasi." Dipping down from the epithelium, 1, is a sebaceous gland, 2 and 3, very considerably enlarged and racemose or, as it is said, adenomatous. The connective tissue stroma is not infiltrated except in the immediate vicinity of the vessels; in some cases the latter are considerably engorged giving a characteristic red appearance to many of the "Lipomata." The skin is normal. Frequently the mouths of the acini become plugged and true *sebaceous cysts* in every stage of development may be readily studied. Acarus folliculorum I have invariably found present in large numbers and in all stages of development.*

Hypertrophy and Adenoma of Sweat Glands.—A group of sweat glands may hypertrophy, and their mouths may be visible as they lie grouped together on some small

* The acarus may in some of these cases be pathogenic, *see* chapter on Parasites.

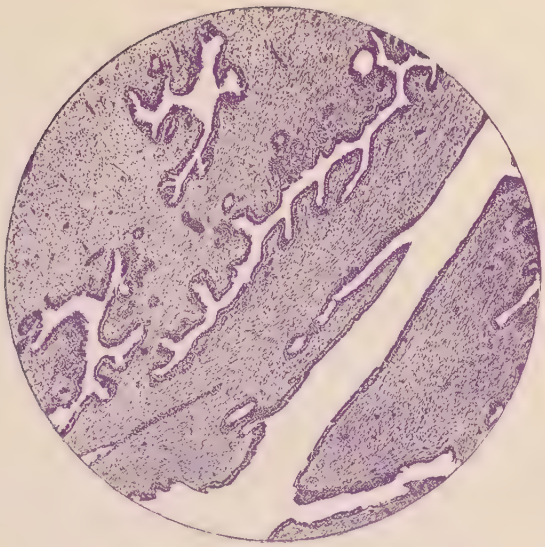

Fig. 69.—FIBRO-ADENOMA OF MAMMA.

The large slit-like acini are very conspicuous, and contrast well with the normal gland tissue represented at 1, and the malignant overgrowth represented at 2, in the fig. below.

[illegible]

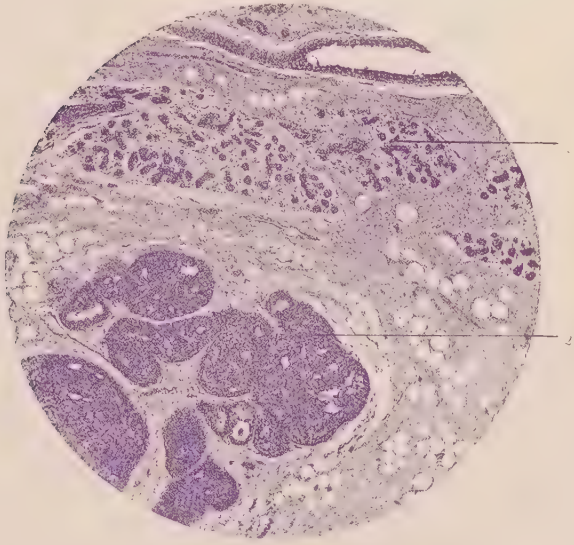

Fig. 70.—EARLY ACINOUS CANCER OF MAMMA.

1. Slightly altered mammary acini.
2. Commencing malignant overgrowth of acini.

Obj. 1 in., without eyepiece.—Logwood.

patch of skin, which is often more hairy and elevated than that which surrounds it. Sometimes a genuine adenomatous, or adeno-cystic change occurs and a large tumour results. Both sebaceous and sweat gland tumours give rise to carcinomata.

Adenoma and Carcinoma of the Mamma.—*Adenoma.* The adenomata are circumscribed tumours, which in the majority of cases appear to have been early cut off from all outgoing ducts. They vary greatly in structure both as regards the amount and nature of the glandular and fibrous tissues respectively. The following serve as examples of the leading types.*

1. *Acinous type.*—The tumour is largely composed of groups of branching gland acini which differ but slightly from the normal, being if anything more cellular. The connective tissue around is not much altered and in general the appearance is such as would be presented by an increase of the condition represented at 1 in **Fig. 70.**

2. *Duct or Tubular type.*—Scattered or more or less grouped are numerous dilated gland channels or small cystic spaces, which are for the most part lined by a single layer of columnar or cubical secreting epithelium. The stroma may consist of a fibrous spindle celled growth.

3. The *fibro-adenoma* is the common adenoma which is represented in **Fig. 69.** The gland acini are drawn out and slit-like, or they are irregularly branched and compressed. The stroma is very abundant and composed of a fine spindle celled connective tissue.

* The adenoma of the breast may be considered as probably derived either from, 1, adenomatous change in normal mammary tissue; 2, from accessory mammæ; or 3, from portions of gland tissue accidentally cut off from the rest.

From the above other varieties proceed. Thus the cystic condition may become most marked as in *cystic adenoma;* the cysts may be further the seat of *intra-cystic growths* of various kinds, either delicate and papilliform, or large and polypoid, fibrous or glandular structures. The stroma may constitute the chief portion of the tumour and may be either hard (fibroma) or soft and very cellular (fibro-sarcoma). Lastly the gland epithelium may tend to spread irregularly into the surrounding stroma and to pass into the condition of CARCINOMA as in **Fig. 70,** where it will at once be seen that there is a great difference between the gland tissue at 1, and that at 2; in the former situation the acini are grouped into almost normal lobules, in the latter (2) the acini form large lobed masses of proliferating cells, which push into the surrounding stroma. At some parts of the tumour, as in **Fig. 71,** the early stages of the gland cell proliferation may be seen; at 2 for instance the lumina are still preserved, whilst in the neighbourhood of 1 the acini are masses of proliferating cells. These changes are cancerous and the resulting growth is *atypical*, that is to say it does not follow closely the parent form, yet it is much more typical than some forms to be presently considered, since it retains a more or less acinous outline; from this circumstance it has received the name *acinous cancer* of the mamma. More rarely a typical form does occur, a *malignant adenoma* or *typical columnar epithelioma*, which resembles in structure the duct adenoma and has received the name of *duct* or *villous cancer* of the mamma.

Of all the forms the most atypical are the *scirrhus* and *encephaloid* cancers.

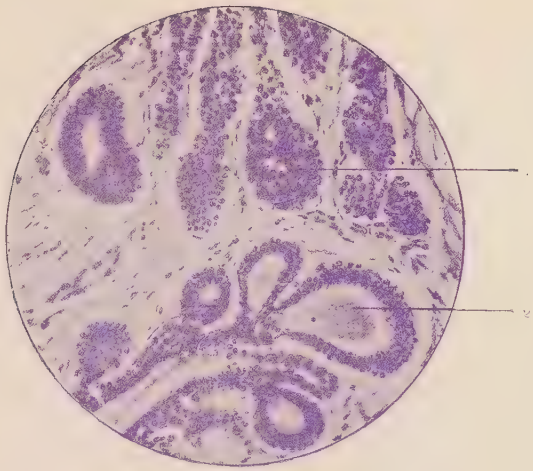

Fig. 71. ACINOUS CANCER OF MAMMA

1. Proliferating gland cells.
2. Duct lumen

Obj. ¼ in., without eyepiece. (Logwood.)

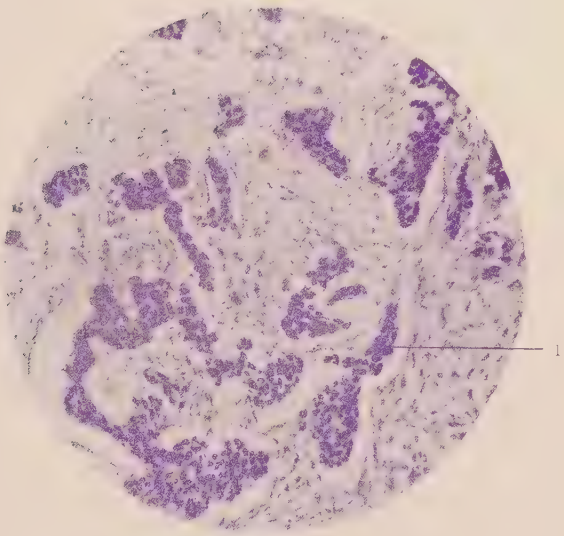

Fig. 72. SCIRRHUS CANCER OF BREAST.

1. Cancer cell groups

Obj. ¼ in., without eyepiece. (Logwood.)

Scirrhus cancer **Fig. 72.**—This is the harder variety of the two and is characterised by an ever extending and exceedingly irregular branched or alveolar growth, which travels along the lymphatic slits and channels. The amount of actual gland tissue is often very small (atrophic scirrhus), yet the changes wrought in the surroundings may be very great. At the margin of the tumour there is a slight cell proliferation in the stroma, but further in this gives place to a dense and often structureless scar-tissue which contracts; in doing this it drags upon and puckers the skin; it drags upon the surrounding muscle fibres, glands, fat and other structures and speedily causes their atrophy and disappearance, and owing to the same causes the centre of the tumour itself atrophies.

Encephaloid cancer **Fig. 73.**—In this variety the alveoli are much larger and the inter-alveolar partitions (1) very thin; comparison between both varieties is therefore striking, though of course there are all transitions. It grows rapidly and as rapidly tends to necrose in the older parts.

In both forms of cancer the cells vary; they may be large or small, or numerous multi-nucleated corpuscles may be present. Metastasis first occurs in the nearest lymphatic glands (the axillary), and these form the centres of fresh growths which infiltrate the surrounding vessels and nerves and often cause their complete matting; metastases in the liver, bones, &c., are more cellular and softer than in the glands.

Uterus, *glandular hyperplasia*, *adenoma* and *cancer*.

Hyperplasia.—In chronic endometritis there is general connective tissue and vascular hyperplasia, and hyperplasia of the muscle fibres, of the glands and covering

epithelium; this overgrowth may lead to the formation of a villous or polypoid condition, the processes being covered by a single layer of proliferating cells, or as previously remarked by a stratified epithelium. The gland proliferation leads to an adenomatous condition in which new crypts and small cysts are formed. From this glandular hyperplasia two principal cancer forms may proceed, the one a *malignant adenoma* and therefore typical,* the other atypical.

Malignant adenoma, typical columnar epithelioma **Fig. 74.**—In the figure the crypts are uniformly cystic, at other places, however, they had assumed papillomatous forms exactly as in fig. 75 a section taken from an intestinal tumour. The growth which arose from the os had deeply penetrated into the uterine tissues, and the section shows that this tissue is very cellular.

Atypical epithelioma.—**Fig. 66** shows what has already been pointed out, the commencement from the gland crypts of a glandular cancer composed of large branching epithelial cylinders. It is quite a distinct type to the preceding.

Alimentary Tract.†—*Hyperplasia, adenoma and cancer.*—A diffuse, villous or polypoid hyperplasia of the mucous membrane of the stomach and intestines is very commonly met with in chronic inflammations, such as ulceration, simple or specific, dysentery, &c.; in these conditions the adenomatous and cystic changes may also be extremely marked.

* There is always the strong possibility that here and elsewhere these *typical* repetitions of the parent structure are derived from congenital rests.

† See Hauser, "Das Cylinderepithel-carcinom des Magens u. des Dickdarms," 1890, for very comprehensive illustrations and text.

Fig. 73. ENCEPHALOID CANCER OF BREAST.

1. Connective tissue stroma.
2. Epithelial mass.

Obj. ½ in. (Carnoy.)

Fig. 74. MALIGNANT ŒDEMA OF UTERUS.

Obj. ½ in., with ⅛ eyepiece. (Carnoy.)

Malignant adenoma or typical columnar epithelioma is well represented in **Fig. 75,** taken from a rectal tumour close to the anus, a spur of the anal epidermis being seen at 1. The malignant gland crypts are both simple and papillomatous and are lined by a mucous secreting epithelium. The stroma is infiltrated. Tumours similar to this one are frequent in the upper portion of the rectum, at the ileo-cæcal valve and at the pylorus.* In the *atypical epitheliomata* the crypts form solid epithelial masses which spread into the surrounding tissues. *Metastasis* occurs with extreme frequency in the liver, and the secondary growths may far outgrow the primary in size; those of the malignant adenomata are more typical, but the others are like that represented in **Fig. 76** where the cancer alveoli are very large and solid. This figure further shows the effect of the growth upon the liver substance; thus in the large trabecula 1, the majority of the liver cells have disappeared and their place has been occupied by fibrous tissue; if the growth is very rapid the cells are merely pressed together and atrophied. The liver is the easiest place in which to study metastasis; cancer emboli may often be observed in the portal vessels, some adherent to their walls, others penetrating into the liver substance; or conversely, growths in the liver may penetrate into the portal and hepatic veins and form polypoid projections from their walls.

ON THE NATURE AND CHANGES IN THE STROMA WHICH SURROUNDS THE TUMOUR.—These correspond in general with those met with in the other tumour classes and they may be thus briefly outlined and arranged.

1. In a certain class the stroma resembles that of a

* See note on preceding page.

simple fibroma or spindle celled sarcoma, *and gland and stroma develop hand in hand*, as for example, in adeno-fibroma (fig. 69), adeno-sarcoma, cysto-sarcoma, typical malignant adenomata, &c. Rests (*comp.* enamel germ tumours) are prone to this change and numerous examples are found in the ovarian and mammary regions, &c.

An interesting variety occurs when the fibrous change is restricted to the immediate vicinity of the acinus, as it throws light upon the formation of certain fibromata (*comp.* neuro- and angio-fibromata).

2. In another class associated with chronic irritation there is general hyperplasia of connective, vascular, muscular and glandular tissue, but that of the glandular element is the most striking. If the glandular change becomes malignant, then *atrophy* soon follows the hyperplasia in the other tissues.

At the periphery of the slow growing scirrhus there is but a slight proliferation of the connective tissue elements; there is nevertheless a marked condensation and contraction, which, as previously remarked, produces widespread atrophy (*comp.* forms of chronic inflammation in the liver, notably the syphilitic).

3. The gland cells may give rise to a hyaline or mucous change in their immediate vicinity; if the hyaline material uniformly surrounds the epithelial cylinders, the tumour is called *cylindromatous*, a form already noted under skin cancers and angiomata. The best examples of cylindromata are afforded by the gland cancers of the alimentary tract, where the structureless material either surrounds an alveolus or is distributed as balls and cylinders in the alveolus. The cells may secrete a *colloid* material into the crypt lumina.

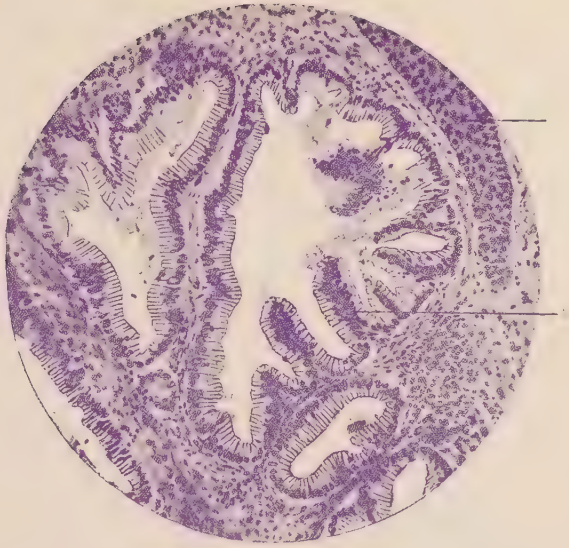

Fig. 75. COLUMNAR EPITHELIOMA OF RECTUM.

1. An epithelial process from skin of anus
2. A papillomatous gland crypt.

Obj. $\frac{1}{4}$ in., without eyepiece. Logwood

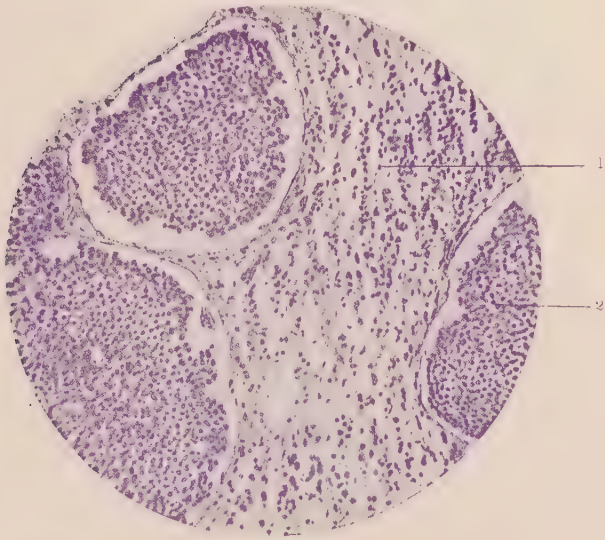

Fig. 76. RECURRENT COLUMNAR CANCER IN LIVER

1. Fibrous liver substance.
2. Cancer mass

Obj. $\frac{1}{4}$ in., without eyepiece. (Logwood)

Chapter IX.

CYSTS.

In the following list little attempt at a classification is made; cysts showing, or tending to show certain points in common, being simply grouped together.

1. Cysts in Tumours.
2. Cysts derived from epithelial inclusions, sinus, duct and gland rests.
3. Cysts of the ovary and testis.
4. Cysts of the urinary system.
5. Cysts of the breast, liver, pancreas, salivary glands and thyroid.
6. "General cystic degeneration."
7. Bursal, synovial and serous cysts.
8. Lymphatic and vascular cysts. Cystic hygroma.
9. Cysts of mucous membranes.
10. Cysts of the skin and epithelial appendages.

1. Cysts in Tumours.—As the occurrence of cysts in tumours was referred to several times in the preceding chapter only a few additional remarks are necessary. Cysts are often found in fibrous and cartilaginous tumours (cystic fibromata of uterus and of bone) and there appears some evidence to support the view that in some cases at least of *general cystic disease of bones*,* the cysts are derived from cartilage rests. In these cases the cysts appear to commence as clefts in the fibrous or cartilaginous tissue which widen and at the same time acquire a more or less complete epithe-

* Information is needed to know whether in all these cases the membrane bones of the skull are exempt.

lial lining. This remarkable tendency of "rests" to give rise to cystic growths is further illustrated in the next and some of the subsequent groups.

2. Cysts derived from epithelial inclusions, sinus, duct and gland rests.—These tumours constitute a most important group of cysts which throw much light upon the ætiology of tumours generally as the following examples show.

Both the *pineal gland* and the posterior lobe of the *pituitary body* are formed as tubular outgrowths of the second cerebral vesicle. In the former the follicular spaces which are lined by ciliated epithelium tend to become obliterated. In the latter a small persistent ciliated space is occasionally encountered. It is probable that early in embryonic life the fœtal scalp may contract an adhesion to the pineal body and that thus epithelial rests may remain adherent to this rudimentary structure when the cranium forms. On the other hand a buccal diverticulum—Rathke's pouch does actually grow up to the infundibulum, and gives rise to an acinous gland-like structure which forms the anterior lobe of the pituitary body. The gland-like portion persists resembling the thyroid in its colloid secretion, but the pouch disappears; traces however may no doubt persist, not only in the posterior wall of the pharynx where they may give rise to a stratified or perhaps ciliated epithelial cyst, but also attached to the pituitary body in the interior of the skull. Agreeing with the above statements, simple columnar lined cysts have been found in the pineal and pituitary bodies, whilst in the latter ciliated cysts have been recorded. In both stratified epithelial cysts have been found, having in the case of the pineal body all the

constituents of the skin of the scalp—hair, sebaceous glands, smooth muscular fibres and fat. Lastly, the anterior lobes of the pituitary body are often the seat of an adenomatous hypertrophy, less frequently colloid cysts are found.*

The *lingual sinus* may, though obliterated superficially, fail to be so deeper down, and persisting, be the cause of a stratified epithelial cyst, or as it is also stated of a ciliated one, at the root of the tongue.

The *branchial sinuses* are a frequent source of dermoid cysts; cysts moreover which may contain innumerable teeth (horse and sheep especially). This circumstance is rendered interesting owing to the fact that teeth are normal to the branchial arches of some fish.†

Persistent remains of the *vitello-intestinal duct* are most probably the cause of some of the cysts found occasionally in the region of the umbilicus, in the mesentery and close up to the ileum. They may be lined by columnar ciliated epithelium, or with crypts of Lieberkühn and possess a smooth muscular coat and nerve fibres; the contents may be mucous.

Remains of the *post-anal gut* very probably furnish many of the glandular cystic tumours of the coccyx. It is quite possible also that the vascular *coccygeal gland* may be the source of a few. On the other hand remnants of the neural canal and meninges may be the source of other coccygeal cysts whether ciliated or not.

In the following groups it will be seen how remains

* In the succeeding chapter further information is given as regards other tumours of these bodies.

† A fact pointed out by Dr. Ord.

of the *Urachus*, *Wolffian* and *Müller's ducts* give rise to cystic growths.

3. Cysts of the Ovary and Testis.—Cysts of the ovary and ovarian region are very frequent and reach enormous proportions.

Fig. 77 depicts a small portion of a huge cystic adenomatous ovarian tumour. The stroma (2) is chiefly composed of spindle cells and the lining (1) of secreting columnar cells; owing to the hardening, however, the lining and stroma have separated from one another.

The epithelial wall of ovarian cysts varies, it may be columnar as above, cubical, flattened, ciliated or stratified. The contents are very frequently colloid, at other times thin, being composed of little else but water; in the case of the dermoid cysts the contents are characteristic. The cysts may be simple or multilocular. Intracystic papillomatous formations are frequent. Rupture occasionally occurs with dissemination of the lining epithelial cells and papillæ, and the consequent growth on the peritoneum of innumerable papillomatous, cauliflower, colloid and other epithelial formations.

With regard to the starting point of ovarian cysts:—Undoubtedly the *Graafian follicles* may become cystic, and cases are recorded, the so-called "ovary in excessive growth" and others, in which ova were found in the dilated follicles. To the Graafian follicles and ova must be attributed both the uni- and multilocular *dermoid cysts* with their simple stratified lining or complex teratoid formations.

Indirectly related to the Graafian follicles are the cases of cystic corpora lutea. On the other hand, the remains of the *Wolffian body and duct*, including both

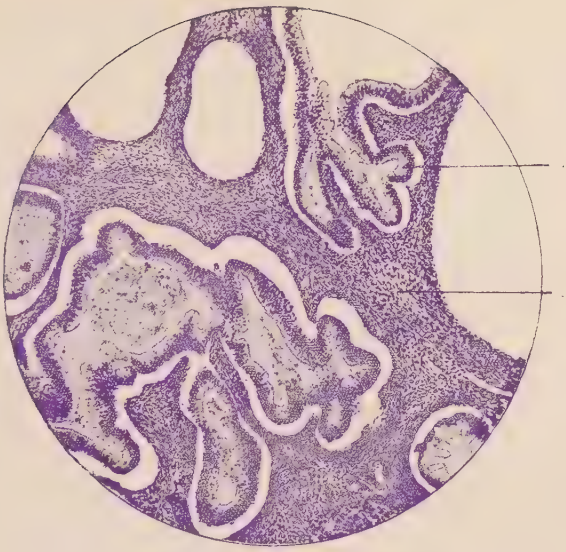

Fig. 77. PAPILLOMATOUS OVARIAN CYST.

Glandular lining of cyst, which has contracted away from the very cellular stroma, 2

Obj. ½ in., without eyepiece. (Logwood.)

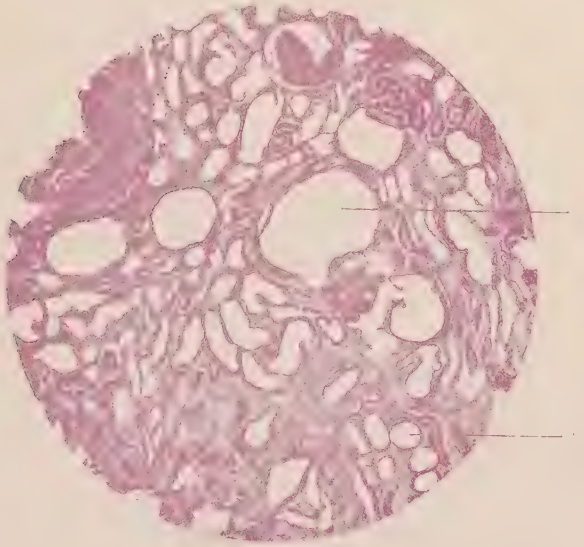

Fig. 78. ACUTE CYSTIC CHANGE IN KIDNEY.

1. Cystic Bowman's capsule.
2. Cystic tube.

Obj. 1 in. without eyepiece. (Eosine and Logwood.)

the tubular portion and duct (epoophoron or parovarium), and the more gland-like portion (paroophoron) are the source of a great many ovarian cysts. This origin may be attributed with considerable certainty to some ciliated, hilum and broad ligament cysts. But in our present state of knowledge it would be unwise to say what are Graafian and what are Wolffian cysts.

In the case of certain cysts, often dermoid, found either on the broad ligaments, on the omentum or elsewhere on the peritoneum; the possibility of stray *oophoritic rests* as a cause of these must not be overlooked.

In the vagina Gärtner's duct, the remnant of the Wolffian duct, is not uncommonly the cause of cysts.

Cysts of the Testis.—Excluding the common hydroceles of the sheaths of the testis, there are several varieties of cysts worthy of note. Thus they may be simple or multilocular and be imbedded in a fibrous or very cellular (sarcomatous) stroma; cartilage and striated muscular fibres are occasionally present. They may be lined by columnar, ciliated or rarely by stratified epithelium and examples of dermoid cysts have been recorded.

Spermatozoa form the most important elements in the contents of some of the cysts. Lastly, amongst the interesting tumours of the retained testicle, cystic growths occupy a place.

In considering the origin of the above cysts, the *spermatic tubes*, *Wolffian body and duct*, *Müller's duct* and lastly remains of *ovarian* tissue must be considered, as the following examples tend to show:—

In a case of Androgynia with well developed testicles, one of the ovaries was replaced by a large cystic *dermoid*

growth. The possibility therefore of a portion of *ovarian parenchyma* remaining and travelling down into the scrotum with the testis, and of afterwards giving rise to a dermoid cyst, is obvious. How far the simple stratified cysts are derived from adult *spermatic tubes*, how far from spermatic tube rests which have failed to unite with Wolffian duct tubes, it would be difficult to say. But that the common sperm-containing cysts owe their origin to these rests seems to us very probable; indeed Paget long ago suggested that in these cysts the spermatozoa were secreted by the lining membrane. The *Wolffian body* enters largely into the composition of the testicle and is without doubt the cause of many cystic formations; simple examples are the cysts of the organ of Giraldès. The *hydatid of Morgagni* and other rests of Müller's duct are possible sources of cysts.

The *stroma* of ovarian and testicular cystomata is commonly composed of an abundant new growth of cellular tissue, myxomatous, fibrous, spindle or round-celled; for this reason the tumours are often called cystic sarcomata, but though local recurrence of the tissue may occur, metastasis of the *stroma* is very rare. The comparatively frequent presence of cartilage, especially in testicular tumours and of sometimes even striped muscular fibres, tends strongly to show that the stroma is, equally with the Wolffian or other vestigeal glandular organs, a remnant derived from the tissues in the neighbourhood of the early vertebral column.

4. Cysts of the Urinary System.—This system affords numerous examples of the many ways of cystic formation. Thus, in many cases of obstruction the bladder becomes greatly dilated, and the walls instead of being thinned often show considerable fibrous hyper-

plasia. Sometimes secondary vesical *diverticula* or *sacculi* are formed, and, as has been pointed out (Marcus Beck), their walls may contain a considerable amount of new fibrous and muscular tissue. As a sequence to vesical dilatation or from other cause a *ureter* dilates and with it the pelvis of the kidney. This latter condition is known as *hydronephrosis*, and in extreme cases the kidney becomes so atrophied and altered that it forms a mere fibrous appendage or thickening on the cyst wall. Examples of pressure atrophy entailing destruction of the proper parenchyma and its substitution by fibrous tissue are common in glandular organs. As a result of hydronephrosis, especially in the fœtus, the *collecting tubules* may dilate and form a cystic spongework in the pyramids. The obsolete *urachus* furnishes numbers of interesting cases where cysts are found in the anterior abdominal wall between the umbilicus and bladder. Thus the cysts of the umbilicus may be enteric or allantoic.

Fig. 78 represents a most marked example of general cystic degeneration of the kidney of an adult. The cysts are lined in places by a flattened (atrophied) cubical epithelium, and they appear to have originated both in the tubules and in Bowman's capsules, 1 and 2. There is no noticeable fibrous tissue overgrowth, and appearances favour the view that they are *retention cysts* formed rapidly by the blocking of the tubes by epithelial débris, the result of an acute nephritis.

In **Fig. 79,** on the other hand, *chronic interstitial* changes are to the fore, and it is in these cases of fibroid overgrowth, not only in the kidney but in all glandular organs, that cysts are so commonly found.

The tubes in some part of their course become partially or completely choked by the fibrous overgrowth and contraction; as a result they dilate as represented in an early stage at 2. The lining cells become first cubical then flattened as the cyst increases. Occasionally small cystic adenomata or cysts with intracystic papillomatous formations are found, some of which are undoubtedly derived from these retention cysts, but it is also probable that Wolffian body rests may be a cause.*

Lastly, the CONGENITAL CYSTIC KIDNEY is one of many examples of intra-uterine cystic formation. The kidney is in some cases a huge collection of cysts with no recognisable renal tissue and with very little intervening fibrous stroma; at other times it is small and contracted and there is a very considerable overgrowth of cellular connective tissue. The cysts are lined with cubical or flattened epithelium and appear to be smooth walled. The condition is often associated with some renal or other malformation. Possible causes of their origin would include those given above but operating in intra-uterine life, viz., general nephritis causing blocking of the tubes either by casts or epithelial débris or more slowly by connective tissue overgrowth; local nephritis or overgrowth of connective tissue spreading up from the pelvis of the kidney and resulting from hydronephrosis or perhaps some other cause ("Nephro-pyelitis fibrosa," "Pyelo-papillitis fibrosa ascendens"); failure of union between the renal and collecting tubules, or from rests of the Wolffian or supra-renal bodies.

* Whether a supra-renal rest can give rise to a papillomatous formation seems to us doubtful. Cystic supra-renals are not common.

Fig. 79. CHRONIC INTERSTITIAL NEPHRITIS

myocardium

3 Fibroid t

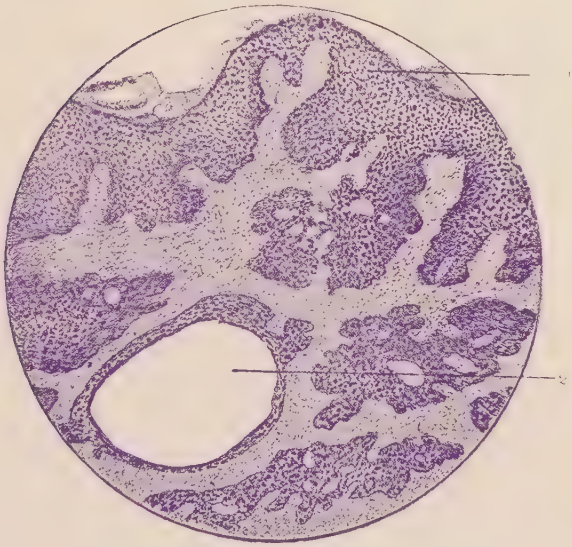

Fig 80. SMALL EPITHELIAL CYST FROM AN EPITHELIAL TUMOUR OF THE SKIN.

1. The epithelium of surface
2 The cyst.

Obj. 1 in., without eyepiece. (Logwood

5. Cysts of the Breast, Liver, Pancreas, Salivary glands and Thyroid.

Breast.—During lactation attention is occasionally drawn to a cyst, the *galactocele;* it is due to retention of milk in a duct, owing probably to a previous blocking, the result of chronic inflammation. In later life "*involution cysts*" containing clear fluid are similarly due to fibrous tissue overgrowth. There are many other examples of cysts of the ducts which are lined by cubical or flattened epithelium and the contents of which vary. Circumscribed cystic tumours are frequent. The cysts may be smooth or papillomatous (proliferous cysts) and are embedded in a cellular stroma which is either fibrous or "sarcomatous." Appearances favour the view that they arise from lobules of the mammary gland cut off from the main mass at an early period, or that they are derived from rests of accessory mammæ.

Liver.—Cirrhosis owing to the blocking of the bile ducts is a frequent cause of cysts, the liver in extreme cases resembling a sponge. Foreign bodies, such as gall stones and parasites, are also a fertile source; the latter are often associated with adenomatous and papillomatous cysts. Stress is laid by some on the formation of cysts from the vacuolation of the liver cells. A ciliated cyst is occasionally found at the root of the suspensory ligament; this suggests a congenital origin from an outlying isolated liver rest.

Pancreas.—Cysts arise from similar causes to the preceding. Concretions and parasites must not be overlooked. The occurrence of pancreas rests in the adjacent intestinal wall may be the cause of cysts in this region.

Salivary glands.—The common retention cysts are the *ranulæ* formed by the blocking of the ducts from within or without.

Thyroid.—The thyroid is a frequent seat of cystic change. All stages from a slight hypertrophy of the follicles to huge cysts being encountered. Papillomatous cysts occur which some regard as derived from accessory thyroids. The origin of some of the cystic hygromata of the neck from accessory thyroids is also suggested.

6. General cystic degeneration.—Cysts are often found simultaneously in the liver and kidneys, or in the kidneys, lungs, liver, muscular fibres of heart and brain, or in other combinations. Occasionally they bear a close resemblance to one another, and this has suggested a parasitic or metastatic origin. There seems some evidence in favour of both views; but they are not common causes and most frequently the association is purely accidental.

7. Bursal, Synovial and Serous cysts.—These form a natural group of cysts, often spoken of as exudation cysts. Many of them are closely related to the lymphatic system and to the large group of cysts derived from it, viz., the cystic hygromata. They may arise from dilatation of pre-existing cavities, or from distension and outgrowth of diverticula which may either retain their connection with the mother cavity or become shut off, or they may arise from remains of former cavities.

Bursal cysts.—A bursa may enlarge and become cystic from long continued "intermittent pressure," and in addition its wall may greatly thicken. A new bursa may readily form over a pressure spot, a simple

example being that which sometimes appears beneath a corn. In these cases it is probable that a lymph space dilates, and that its endothelial cells proliferate and form a complete lining, shutting it off from direct communication with the rest of the lymphatic system.

Synovial cysts.—A joint cavity or a synovial diverticulum leading away from it often becomes distended, and the same may be said in the case of tendon sheaths. The special cysts which frequently arise in connection with the latter are termed *ganglia*, they may or may not retain their connection with the sheath. In the neighbourhood of the knee and other joints, isolated synovial cysts are frequently encountered. They are derived, at some time or another, from outgrowths of the synovial cavity or synovial sheaths of the adjacent tendons; and the admirable dissections of the knee joint by Prof. Poirier show how readily the necks of the very minute saccular diverticula which are normally connected with the joint and adjacent tendon sheaths might become occluded.

Serous cysts.—This group includes both the cysts of the pleura, pericardium and peritoneum, and those of the cerebro-spinal membranes, ventricles and spinal canal.

Cysts probably very often arise from cutting off of diverticula of the peritoneum, pleura and pericardium. An interesting example is the femoral cyst which probably originates from a peritoneal pouch. Persistent remains of the peritoneum furnish two interesting examples in the case of the cystic dilatation of the canal of Nuck and the hydroceles of the cord.

Cystic protrusion of the membranes of the brain and spinal cord are not infrequent. In the head where they

are called *meningoceles*, the common seats are occiput, root of the nose and sella turcica. Along the spinal cord they constitute the simple varieties of *spina bifida*. In the sacro-coccygeal region as well as in that of the sella turcica, the protrusions are frequently markedly polypoid and constitute one of the numerous forms of congenital tumour which are common to both these spots. Dilatation of the ventricles of the brain (*hydrocephalus, anencephalia*) may be so great as to cause arrest of development or atrophy of the cortex and surrounding nerve matter. The dilated ventricles may moreover, as represented by the ependyma, form the lining to a meningocele which is then termed a *meningo-encephalocele*.

Similarly dilatation of the neural canal occurs and is called *syringo-myelus;* further the dilated canal may form the cavity of a spina bifida (*syringo-myelocele*), a thin layer of nerve matter forming one of the coats of the wall.

Besides the above cystic dilatations, numerous small cysts are frequent in the meninges as well as in the brain substance itself; they are perhaps caused by blocking of lymph spaces.

A larger ciliated cyst has been described in the brain, and is probably due to an early cutting off from the cerebral vesicles.

Along the spine small isolated cysts are occasionally found and some may be lined by ciliated epithelium; they may originate from early cuttings off of the membranes or neural canal.

8. Vascular and lymphatic cysts.—The vascular cysts are unimportant. Cysts may occur in nævi, but as a rule nævi do not give rise to large cavernous cystic

growths. On the other hand rupture of a blood-vessel into a lymphatic or other cyst may lead to errors in diagnosis.

The several varieties of lymphatic cysts taken together form one of the largest groups of cysts. Indeed there appears to be a marked proneness to cystic formation throughout the lymphatic system, and not only in the adult lymph spaces, but to a marked degree also in the early fœtal tissue and in the lower animals.

As the result of inflammation and inflammatory new growth, lymphatic cysts occur frequently in the connective tissue, and very pretty examples of this are furnished by the choroid cysts in the eye. The occurrence of a general cystic change in the lymphatic system of various organs, through inflammation or other cause, would account for many of the cases of "general cystic degeneration" referred to in the preceding pages. Occasionally cystic dilatations of the abdominal lymphatics occur which have been named *chylangiomata.*

The congenital lymphatic cystomata form one of the most remarkable groups of congenital tumours. Already under lymphangiomata reference has been made to the lymphatic nævi from which there are all transition stages up to the huge cystic tumours—the cystic hygromata. These are true neoplasms, and may occur very early in fœtal life. Their seat of election is the neck, which is remarkable, but they also occur on the trunk and limbs. They may be composed of a few large cysts or possess a sponge-like structure on section. They are not circumscribed, a noticeable feature being the numerous deep prolongations of small cysts which proceed out from them and ramify deeply, ex-

tending in the case of some of the neck cysts into the pericardium. These ramifications may also be frequently observed in muscle and in the parotid and submaxillary glands, causing the extensive atrophy of these tissues. The cysts may be simple, multilocular or trabeculate, and they may be lined by a flattened endothelium. The contents may be clear, yellowish or bloody. The stroma is usually very cellular, hence the name *lympho-cysto-sarcomata* which is applied to many of them.

Smooth muscular fibres may form part of the cyst wall. In the growth of the tumour connective tissue and endothelial cell proliferation occurs; the latter is sometimes very marked, ramifying cylindrical masses of cells being formed which later become cystic. The origin of the cystic hygromata has been attributed to various sources besides the above, viz., to cystic degeneration (softening) of connective tissue, to pharyngeal diverticula, to hyoid glands, and to the vascular system.

9. Cysts of mucous membranes.—As the great majority of mucous membranes are plentifully supplied with minute glands, it is not remarkable that they should afford examples of cystic "degeneration"; and moreover of widespread cystic change, seeing that the conditions, which like chronic inflammation favour the formation of cysts, are wont to affect a large area of mucous membrane. Thus in dysentery or chronic gastritis, the well marked connective tissue hyperplasia which usually occurs may cause blocking of the mouths of Lieberkühn's crypts and the gastric glands respectively and, in consequence, cystic dilatation. Chronic inflammation does not, however, ex-

plain the cases of acute cystic change which sometimes occur in the stomach; perhaps under these circumstances the mouths of the ducts get blocked by mucous or epithelial débris. The mucous membrane of the cervix and uterus is not an infrequent seat of cysts, indeed cystic dilatation of the cervical glands under the name of "*ovula Nabothi*" is very common; much more rare is cystic disease of the uterine lining; when present it is very often associated with chronic endometritis. The reader may here be reminded that in the cases of cysts associated with chronic inflammation, the former are not merely mechanical overstretched sacs but are rather *cystic hyperplasias*. Cystic dilatation of the buccal and lingual mucous glands is not rare, nor is that of the maxillary sinus, as was long ago pointed out by Giraldès. The epiglottis, trachea, vagina, Cowper's and Bartholin's glands are less frequent seats. Occasionally larger single cysts are found associated with the mucous membranes. Thus ciliated cysts have been found in the thorax in close proximity to the œsophagus and trachea, from both of which they might have been derived early in fœtal life. Ciliated cysts have been described in the tongue and in the vicinity of the hyoid, which are believed to originate in the lingual canal.* The vermiform appendix is not infrequently converted into a mucous cyst, and a similar change has been stated to occur in the glands in it.

* The cysts of both these regions are sometimes ciliated, sometimes stratified; this may depend upon their date of origin from the lingual canal; very early the duct is probably ciliated, later stratified. According to Bochdalek the canal of the foramen cæcum may be lined by ciliated epithelium, it usually however appears stratified.

10. Cysts of skin and epithelial appendages.—These include cysts arising in the rete and its processes, in the sebaceous and sweat glands, in the hair follicles and teeth sacs, and cysts arising from epithelial inclusions (simple dermoids).

Fig. 80 represents a small cyst in the interior of an epithelial process of an epithelioma. It is lined by a stratified epithelium and may be taken as the model of one of the simplest forms of epithelial cysts. Cysts like this one sometimes occur in the rete, and are probably formed either by dilatation of the intracellular spaces or softening of the cells.

Cysts of the sebaceous glands are common, especially so in the condition described under lipoma nasi. They are formed by blocking of the mouth of a main duct or of an acinous, and they may either remain very small or enlarge considerably. They are lined by a stratified epithelium, similar to that figured above.

Cysts of the sweat glands are naturally of a very glandular type resembling the cystic adenomata in general.

Cysts of hair follicles are a much more important group. Sometimes several small cysts occur together in atrophic and chronic inflammatory conditions of the skin. In these cases the mouth of the follicle is blocked and the latter dilates into a cyst; very often the hair root in its wall continues to form hairs which project into or are shed into its cavity. Hair follicle cysts are we believe the cause of the majority of the well known *atheromatous cysts*, of which **Fig. 81** represents the wall in section. They are frequent in the scalp where they are known as "wens," but they are also common elsewhere. They are characterised by a

thick often horny wall and "atheromatous" contents, which latter consist of epithelial débris and products, fatty and calcareous matter and cholesterin. The wall is well represented in the figure; 2 points to the stratified epithelial lining, the Malpighian layer of which is directly applied to the external fibrous tissue 1; in the other direction the epithelial cells swell and pass directly into the structureless tough horny material 3, which forms by far the greatest thickness of the wall, and further in breaks down into the atheromatous débris. It happens occasionally that one of these cysts bursts and becomes exposed to constant irritation. Under these circumstances there is often an enormous increase of the dense horny laminæ which pile up from the bottom and finally project out beyond the cyst in the form of a *horn*. They have been well described by Erasmus Wilson and they are interesting because they are very suggestive of monstrous hair formations.

Cysts of the teeth sacs.—The cysts of the teeth sacs and enamel-germ-remains form a large proportion of the simple and multilocular jaw cysts. They may be lined by a stratified or single layered epithelium; they may contain clear or atheromatous fluid and may have one or more teeth in their wall, or they may surround themselves with a bony shell. The teeth-bearing cysts have been named *dentigerous*, and it is of interest to note that if they are incompletely removed, the part which remains may give rise to fresh teeth.

Simple dermoid cysts or *skin dermoid cysts.*—Only those dermoids are described here which are in all probability due to early skin inclusions or exceptionally to traumatic inclusions in later life. Already in the beginning

of the chapter branchial and other dermoids have been referred to, and in the following chapter a number more will be described under congenital tumours.

In the order adopted by Lannelongue the most frequent seats of the simple dermoids are the orbit and its surroundings, scalp, neck, floor of mouth and palate; but they are met with elsewhere, notably on the hand and fingers, in the umbilical, sacral and pharyngeal regions, in the iris and in the fissural lines generally. They are lined by stratified epithelium similar to that of the skin and usually possess some of the skin appendages as *sebaceous* or *sweat glands*, *hair* or *teeth*. The distribution of these appendages is not indiscriminate throughout the cysts, but certain of them as teeth occur only in the simple dermoids of the branchial and jaw regions (*see* p. 181). The wall of the dermoid inclusion must not be considered as only represented by the stratified epidermis, but the derma must be taken into consideration with its fibrous, fatty and muscular tissue. The contents of the cysts consist of "atheromatous" or porridge-like material made up of epithelial débris and "pearls," hair, teeth, cholesterin, &c.; occasionally a large amount of *calcareous* matter is present, or the cyst is entirely filled with oil and is known as an *oil cyst*, the secretion being furnished by the sebaceous glands.

A few remarks are necessary about certain of the groups:—

Branchial dermoids are often associated with fistulæ and they may be in part lined by ciliated epithelium probably furnished by the pharynx. The facial and scalp dermoids are usually attached to the periosteum or through the bone to the dura mater and occa-

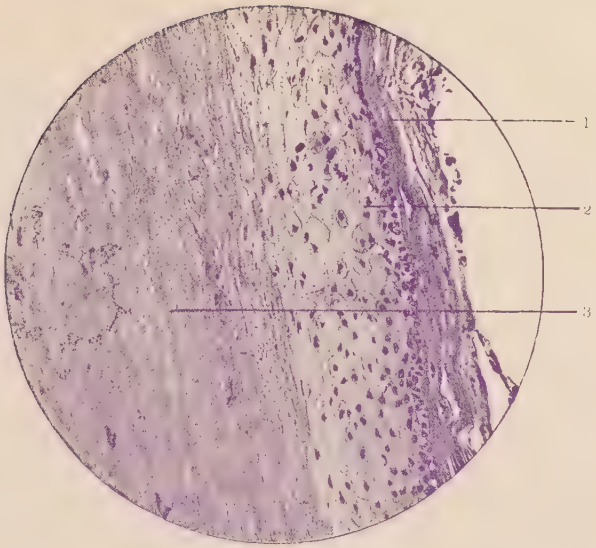

Fig 81. WALL OF ATHEROMATOUS CYST.

1. Fibrous wall.
2. Epithelial layer.
3. Horny amorphous transformation of epithelium.

Obj. $\frac{1}{4}$ in. without eyepiece. (Logwood)

Fig. 82 A THROMBUS IN PROCESS OF ABSORPTION

1. New formed capillaries at margin of thrombus.
2. Oldest and unvascularised part of thrombus.
3. Point of adhesion of thrombus to vessel wall.
4. External coat.
5. Muscular coat

Obj. $1\frac{1}{2}$ in., without eyepiece (Eosine and logwood)

sionally a dermoid within the skull remains attached to the scalp by a pedicle; they are most frequently situated at the external and internal angles of the orbit, the root of the nose, external occipital protuberance and anterior fontanelle. In these situations they might be explained by the dragging in of the surface epiblast by the dura mater, during the growth and extension of the cerebral hemispheres (compare the sacral dimple). The dermoids of the floor of the mouth are in great part furnished by the branchial dermoids, and Barker's classification into median, unilateral and bilateral is that usually adopted. True dermoids of the umbilicus do apparently occur and thus add another variety to the numerous congenital cysts which may form in this small region. (*See* urachus and vitelline cysts).

Chapter X.

CONGENITAL FORMATIONS.

In this short chapter it is proposed to briefly deal first with some of the smaller congenital misformations, many of which have been already referred to in the preceding chapters; and secondly, with some of the larger complex tumours not yet described. The reader's attention is directed to them on account of the light which they throw upon tumour morphology.

Rests.—By this term are understood both portions of tissue which get cut off from the parent mass and which often become widely separated from their original place of origin, and vestigial remains of former structures. A third group which has, however, a much more problematical existence might be furnished by early metastasis of an organ or tissue. The commonest examples of rests are the accessory suprarenal bodies. These may be encountered in the neighbourhood of the suprarenal capsules, on or in the cortex of the kidney, on the spermatic artery and in the broad ligament, and even attached to the surface of the liver. In the kidney they have been long suspected to be the source of some of the adenomatous and cystic formations so frequently met with in that organ, and reference has already been made to the so-called lipoma of the kidney which represents a degenerate rest. If in the kidney, so elsewhere in the peritoneal cavity they may possibly give rise to neoplasms. They are readily recognised in the kidney or liver by the fact that they

are separated by a wall of connective tissue from the proper parenchyma of these organs.

In the falciform ligament detached pieces of liver substance are occasionally met with and as previously hinted it is very probable that they are the cause of the cysts found in this situation. Their presence in a peritoneal fold at some distance from the liver shows that they probably get detached by stretching. This mode of separation is especially argued in the case of some omental tumours; the omentum, for example, is supposed to contract adhesions to an ovarian tumour and to subsequently break off with a portion of the growth adhering to it.

Small accessory spleens are not uncommonly found, they undergo the degenerations, such as lardaceous, which the main mass may be subjected to.

Accessory thyroids are well known; they may either be small portions of gland tissue which have been detached from the main mass; or they may be thyroids which have failed to coalesce with the main mass. They are believed to be the cause of the gland-like tumours which are found in the neck in close vicinity to but not attached to the thyroid gland, and of some of the gland tumours of the root of the tongue. In those cases where the structure of thyroid tissue is adhered to there can be no doubt that this is the case, but whether accessory thyroids are the cause of the intracystic and papillomatous gland formations occasionally met with in the neck, it is more difficult to decide. There is evidence to show that accessory thyroids hypertrophy when the main mass is removed; it is also worthy of note that removal of the thyroid may be followed by hypertrophy of the hypophysis cere-

bri at least in dogs, and it is also a fact that the anterior lobe of this body possesses a structure very closely resembling thyroid tissue; hypertrophy of the hypophysis is observed in Acromegaly, a disease in which the thyroid is frequently atrophied or the seat of a goitre, and also in some cases of sporadic cretinism where the thyroid is absent. Thyroid gland tissue does not appear to be confined to the vicinity of the thyroid gland, it has been found in the bronchial glands, lungs and in the bones in cases where the thyroid was enlarged, and its presence in these situations has been regarded as examples of metastasis.* With reference to this point it may be borne in mind that certain angiomata, which are occasionally cystic, possess the property of forming a colloid-like substance (as seen under the microscope) to a remarkable degree.

The peritoneum is frequently the seat of multiple papillomatous, cystic or colloid growths. In many cases this is clearly due to the dissemination of germs from an ovarian tumour; there are cases however in which a primary seat cannot be detected, and for such it is not impossible to assume that some of them at least start in stray Wolffian or ovarian rests. It would be difficult otherwise to account for the so-called primary scirrhus and colloid cancers of the omentum and the multiple, cystic and dermoid tumours of the omentum and peritoneum.

* According to Piana thyroid tissue occurs close to the aortic arch in the dog. The *hyoid glands* of Zuckerkandal and Kadyi which are well described by Streckeisen, consist of remains of thyroid *duct* and *gland* tissue. They are described as supra-, præ-, infra-, and intra-hyoid, and they may be the seat of mucous, ciliated or stratified cysts.

The tumours of the testis afford examples of how far "rests" may be removed from their original seat; for on the assumption that the testis in its descent carries with it traces of muscle and cartilage tissue from the region of the spinal column, the presence of myomatous and cartilaginous tumours in the testis is explained.

The lipomata, myomata and fibromata found within the theca of the spinal cord and occasionally within the dura mater of the brain, are probably derived from rests which were nipped off the surrounding fatty, fibrous and muscular tissues. This is rendered all the more probable by the occurrence in places where the bony and membranous coverings of the central nervous system are defective of lipomatous and myomatous growths in close contact with the nerve matter. In the walls of cerebral and spinal meningoceles remnants of nerve matter get carried out with the protruding membranes and there is evidence to show that they may give rise to nerve tumours of considerable size.

As mentioned at the outset another class of rests represents vestigial structures. They are numerous and widespread, and are undoubtedly the cause of many tumours. Many examples have already been cited (p. 171, &c.). Other examples are the accessory mammæ and nipples which are occasionally found in the axilla and on the ventral aspect of the thorax and abdomen. They occur as glandular lumps, with or without external orifices, and they may or may not secrete milk; a rudimentary or well formed nipple is sometimes present and occasionally there is a well developed areola with hairs and sebaceous glands. They may be very closely connected to the normal breasts, and it is most probable that the sarcoma-like

adenomata of these organs are due to inconspicuous mammary rests. It is rare for nipple-like bodies to occur on the back.*

Congenital diverticula and sinuses.—Diverticula may represent rudimentary structures or they may be acquired like vesical, intestinal and many other diverticula; the former only will be alluded to here. Pharyngeal diverticula probably represent the pharyngeal portions of the branchial sinuses; they may be the source of some of the cysts, occasionally ciliated, of the floor of the mouth or of the neck.

Meckel's diverticulum, the vermiform appendix and the post-anal gut are the most important of the intestinal diverticula, they may all be the seat of cystic and glandular formations. A diverticulum at the end of the trachea is said to be frequently present and to represent a rudimentary bronchus; it is a possible source of a bronchial cyst. Reference has already been made to Rathke's pouch and the foramen cæcum (pp. 180 and 193).

The commonest examples of congenital sinuses are the cervical fistulæ; they may be complete and pass into the pharynx, or end in a dermoid cyst, or be merely blind sinuses; at their orifices auricular-like cartilaginous tags are occasionally present. In the auricle fistulæ are sometimes met with; they are formed in the course of the growth and union of the various auricular papillæ. A favourite seat for fistulæ and

* These most probably are similar to the teeth, horn and hoof formations occasionally found on the back and elsewhere in animals and are probably due to the rudiment of a second embryo. For further information see Roger Williams, "Journal of Anatomy and Physiology," vol. xxv., 1891.

sinuses (often mere dimples) is the sacro-coccygeal region; most commonly over the coccyx at the lower end of the glabella coccygea.* Lannelongue figures them also over the sacrum and opposite the sacro-coccygeal articulation. They may be associated with a dermoid cyst at their deep extremity or they may be attached to the bony skeleton; this last fact explains their formation. The skin has early contracted an adhesion to the bony skeleton and the subsequent growth of the surrounding fat and muscle tissue has caused the dimpling, sinus formation or epithelial inclusion as the case may be. A similar explanation may be given to many of the facial and cranial dermoids with deep attachment to the dura mater or periosteum (*see* p. 197), the cause of expansion of the surrounding tissue in their case being the development of the cerebral vesicles.†

Congenital tag-like and polypoid processes.—The typical examples of the tag-like processes are the so-called auricular appendages or superficial branchial chondromata, which occur in the neighbourhood of the ear or along the side of the neck (*see* p. 140). Small skin tags and polypi are sometimes found indefinitely scattered about; more frequently, however, they are met with in the line of fissures, as along the raphe of the perineum and the middle line of the palate.

* The dimple or sinus has been termed the foveola coccygea. The glabella is a smooth area over the open coccygeal vertebræ and likened by Ecker to a fontanelle. Lawson Tait describes the coccygeal dimple as the hereditary *cicatrix* of the spina bifida of the coccyx in man.

† As in the case of the coccyx so in the cranium there are spots where adhesion seems more prone to occur than elsewhere.

Allied to this class of rests are the true and false tails of the coccygeal region and the "trumpet" of the cyclops. The false tail is a small fatty appendage which is occasionally seen in the coccygeal region. From this small body there are various transitions up to very large polypoid fat-masses which hang down from the region of the coccyx. Some of the larger polypi are frequently associated with a protrusion of the spinal membranes.

Dermoid plates.—The best examples of these are found on the cornea, sclerotic and palpebral conjunctiva. They consist of small islets of skin bearing hairs, and are to be accounted for by early adhesions between the eyelids and the cornea or sclerotic, which have afterwards broken down, but have left minute rests of true skin behind. Dermoid plates are also found in the buccal cavity. An interesting case has been put on record where the peritoneum was sprinkled over with miliary hair-bearing patches, one ovary being at the same time the seat of a dermoid; clearly they must have originated from the ovary or from oophoritic rests, but how it would be difficult to say.

Complex congenital tumours.—Teratomata.—Of these the dermoid tumours occupy the foremost place. In the preceding chapter much has already been learnt about the simple cystic dermoids which represent skin inclusions and the simple ovarian dermoids; and lastly reference has just been made to the dermoid plates. There yet remain the complex dermoids and congenital formations to the study of which the remainder of the chapter is devoted.

Dermoids may be thus arranged:—

Dermoid plates
Simple cystic dermoids } epiblastic formations.

Ovarian dermoids which may be simple or complex.

Dermoids and teratomata generally, derived from the rudiments of a second embryo.

Ovarian dermoids.—In the preceding chapter several examples of cystic dermoid tumours were given, and in the commencement of the present chapter an explanation of the occurrence of dermoids in the abdominal cavity of the male and female was offered. In the abdominal cavity they may be attached to the ovary (in one case to an undescended testicle); they may occur in the omentum or be attached to other viscera; they may be seated close to the spine or in the recto-vesical pouch; they may be multiple. Rupture of abdominal dermoids is not rare; it may occur into the bladder and give rise to pilimiction (passing of hair in the urine) both in the male and female; or into the vagina, uterus, rectum, &c. The fact that rupture does take place into the abdominal viscera would serve to explain the origin of sigmoid and rectal *dermoid polypi* since they could be regarded as ruptured and evaginated abdominal dermoids which were originally adherent to the gut.*

Structure.—The simplest are lined by stratified epithelium; others slightly more complex contain the various epithelial and associated structures, viz., hair, arrectores pili and sebaceous follicles; enamel germ organs, enamel, well formed teeth, and teeth set in bony plates, the latter combination often assuming a jaw type; sebaceous and sweat glands; nipples with or without mammary tissue. The next category are more complex and in them may be found thyroid-like tissue,

* Thoracic dermoids may rupture into the bronchi and be the source of hair spitting.

nail substance, eye-like bodies, the projection of finger and limb-like processes, brain matter, lung tissue and alimentary tract. Finally the rudiments of a fœtus can be traced both in outline and in structure.

Dermoids derived from rudimentary embryos.—An explanation of these is afforded by the fact that in the ova of certain animals as Rauber has pointed out, two embryos may spring up in union in the same blastoderm or close to one another, in which case they may afterwards fuse (Dareste). Union is much more frequent at the caudal extremity, but occasionally it occurs at the cephalic end or elsewhere along the vertebral axis. In their subsequent growth the embryos usually develop disproportionally until finally one exists as a mere appendage to the other. Agreeing with these statements is the fact that dermoid teratoid formations in the region of the coccyx are proportionately common. A large majority of them are polypoid being in fact fœtal polypi; in many there is a considerable development of alimentary tract; in others it is probable that the structure is very simple. At the cephalic end, in the region of the hypophysis, teratomata are occasionally met with which are most readily explained on the theory of a second rudiment. A similar explanation may be put forward in those cases where complex epithelial appendages, such as horns*, hoofs, nipples, teeth, &c., are found on the back and often connected to the spine.

From the foregoing remarks as well as from those in the last two chapters it will be noted that the tumours of the coccygeal and hypophysial regions are of the

* For interesting case in the cow see picture by Sir E. Landseer in collection of his sketches.

most varied kind both as regards structure and mode of origin. To recapitulate, the coccygeal tumours may be—Lipomata (false tails, &c.), lipomata associated with spina bifida, meningoceles, dermoid cysts, cartilaginous and bony tumours, glandular and glandular cystic (probably derived from the post-anal gut), fœtal teratomata. The tumours in the neighbourhood of the hypophysis are:—Meningoceles, fatty and nerve tumours, adenomata, chondromata and osteomata, cystic and dermoid tumours, and fœtal teratomata.

Note.—There seems evidence for supposing that stray tooth germs may lead, both in the jaws and in the cranium, to odontomata of considerable size. Further reference will be made to this point in the chapter on the Osseous System.

Chapter XI.

THE VASCULAR SYSTEM.

Blood.*—*The changes in the red corpuscles.*—In the severer types of anæmia such as the essential or progressive (*ex.*, pernicious anæmia), the red corpuscles are frequently much smaller than normal as well as very often extremely irregular and distorted; they have been termed in consequence microcytes and poikilocytes respectively. In malaria and in other pathological conditions the red corpuscles are frequently vacuolated; in the frog an extreme degree of

* In making cover slip preparations of the blood, thoroughly clean two cover slips. Hold one slip in the left hand between the finger and thumb and place on it a minute drop of blood. As rapidly as possible place over it a second cover slip held by the corners between the finger and thumb of the right hand. By this action the blood is spread out uniformly in an excessively fine layer and then by a dexterous sliding movement the cover slips are separated. Some, however, recommend as being attended with less danger to the corpuscles, spreading the blood on to a series of cover slips by means of a sweeping movement with a glass rod or microscopic slide. Carefully dry and fix with heat or with alcohol and ether; much depends upon the fixing of the red corpuscles as to whether they will give the proper staining reactions or not. Sometimes the blood is received directly into a drop of osmic acid, or methyl violet in normal saline solution; in this way blood plates may be found. For further information the student is referred to Jaksch's "Clinical diagnosis," Hyem's "Du Sang," Eberth and Schimmelbusch, and Ehrlich.

vacuolation has been produced by the administration of certain poisons*. In leucocythæmia according to Hyem nucleated red corpuscles are almost always to be found and are characteristic of this condition.

The changes in the white corpuscles.—Carefully prepared and stained specimens of blood reveal the fact that there are several forms of white corpuscles which are normal and must not therefore be taken as indicating diseased conditions, nor yet be mistaken for parasites such as the Hæmatomonas. The usual forms have either a multilobular nucleus, the lobes being often connected to one another by very delicate threads indeed: or they may have only one nucleus which may be large and stain but faintly with the usual reagents, or the uninucleated cells may be smaller and stain much more intensively. The nuclei may be fragmented, or as in malaria and in other conditions the protoplasm may be pigmented. As a variety of white corpuscles often associated with the abnormal state of the blood, may be mentioned the eosinophilous cells, mostly large corpuscles which have a great affinity for eosin. The most marked changes in the varieties and number of leucocytes is however seen in Leucocythæmia, a condition which will be described further on. In suppurative inflammatory conditions the number of white corpuscles may be considerably increased.

Thrombosis.—If a small vessel in the frog's mesentery be just touched with nitric acid, a white transparent clot is formed immediately at the seat of injury which may even block the lumen. It however readily breaks down, especially if the blood stream is

* A. Gürber. "Ueber die physiologische wirkung der Lupetidien," &c. Du Bois Reymond's "Archives, Physiology," 1890.

still flowing past, and the fragments or emboli may be watched as they are swept along and lodge in the smaller vessels or at bifurcations. They disappear altogether in a short time. If some of Wooldridge's thymus extract is injected into the jugular vein of a rabbit or cat, an immediate clotting of the portal blood occurs. Microscopic examination of the clots *in situ* in the liver, show that they are composed of masses of red corpuscles and in places of much thready fibrinous or sometimes granular material. Lastly if as in the experiments of Eberth and Schimmelbusch a small vessel of the mesentery of the frog be injured by pricking, a transparent clot gradually (within a few minutes) forms over the seat of injury and blocks the aperture. Comparatively few white corpuscles adhere to this clot and it is described as being formed by the accumulation and fusion (viscous metamorphosis) of the blood plates. To watch the process a good water immersion is required. Eberth and Schimmelbusch have given to this form of thrombosis the name of *conglutination* in distinction to *coagulation* in which the fibrin element is abundant.

The appearance of thrombi encountered in tissues varies. The coagulated mass seated on the aortic valve, figure 86, is quite hyaline in section and is very probably a blood plate thrombus; Klebs describes similar hyaline thrombi as of comparatively frequent occurrence. The thrombus may consist of blood corpuscles entangled in fibrin, and the red corpuscles may in addition have discharged their colouring matter. The fibrin-like material may be present in large amount and be deposited in a lamellated form; amongst the lamellæ there may be groups of red cor-

puscles and occasionally of a considerable number of white. Very often the thrombus consists of finely granular masses and trabeculæ alternating with groups of blood corpuscles.

Changes in and fate of thrombi.—If the thrombi are infective (p. 106) puriform softening and disintegration usually occur. In other circumstances the red corpuscles may rapidly lose their colouring matter and give place to compact finely granular masses; but the most interesting changes are seen when "organisation" or vascularisation takes place. **Fig. 18** represents a thrombosed artery of about the tenth day. The thrombus (3) consists of granular masses and of red corpuscles, whilst at 2 vascularisation is active. **Fig. 82** is a thrombosed artery of older date; the thrombus which has considerably contracted, is almost completely vascularised, capillaries and small vessels being abundant at the periphery 1. It is attached to the vessel wall at the spot (3) where small capillaries enter. When both these thrombosed arteries are examined carefully, it will, as pointed out by Thoma, be readily seen that the thrombi becomes vascularised in two ways. One of the earliest changes in the process of organisation is an outgrowth of endothelium which spreads over the thrombus and into the fissures formed between the hyaline and granular masses of clot. In this way channels, sometimes very large, at other times not much larger than capillaries, are formed between the thrombus and the wall, or deeper in the substance of the former. When the channels are conspicuous and serve to re-establish the circulation, the process is termed the canalisation of the thrombus. The outgrowth of the endothelium is

closely followed by that of the subendothelial connective tissue corpuscles and later of the vasa. Quite similar changes will be described taking place in fibrinous deposits on the heart and on the pleura. In the newly formed tissue very pronounced hyaline changes may occur, and foci of pigmentation are frequent; giant cells are often present and may be closely applied to portions of the thrombus. In the larger vessels and in the heart, remains of old organised thrombi are frequently found in the form of small polypi; in the heart they may be of very considerable size and they very frequently calcify (phleboliths, arterioliths and cardioliths).

Embolism.—The formation of emboli has been alluded to on several occasions both in the present and in preceding chapters (pp. 104, 111, 148, 177, 210). An interesting example remains to be furnished by the fat embolism which occurs after extensive fractures. The emboli are best seen in the lung, but they may also be found in the kidney. In **Figure 83,** which is a section of a lung stained with osmic acid, the capillaries are crowded with oil drops, the alveoli are at the same time filled with red corpuscles. It is to be presumed that the mechanical obstruction offered by the emboli has led to this very extensive diapedesis.

Infarcts.—This term is given to the more or less wedge-shaped or rather conical, pale or congested areas which occur in the periphery of the kidney, spleen, brain, &c., and which follow upon embolism or thrombosis. When an embolus lodges in the mouth of a small terminal artery, it may lead either to an anæmic or to a congested state in the area supplied by the artery, owing to the cutting off of the influx

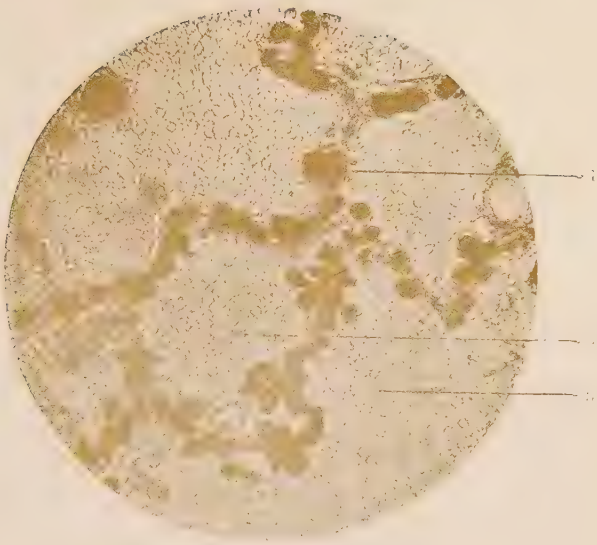

Fig. 83. FAT EMBOLI IN THE LUNG

1. Fat emboli in alveolar walls.
3. Alveoli filled with red corpuscles.

Obj. ⅛ in., without eyepiece. (Osmic acid.)

Fig. 84. INFARCT IN KIDNEY

1. Periphery of infarct marked by a small round-celled infiltration.
2. Necrotic centre of infarct.
3. Renal tissue.

Obj. 4 in., without eyepiece. (Carmine.)

or the retardation of the rapid circulation of the normal blood stream. In the kidney both the white (anæmic) and red (hæmorrhagic) infarcts may often be seen; in **Fig. 84** the former is represented. It will be observed that the infarct does not quite reach the capsule of the kidney* and that it is surrounded by a dark zone 2. It is much paler than the surrounding renal tissue 3, and even though so slightly magnified can be seen to possess less structure; it is in fact an area of necrosis in which the outlines of the various tissue elements are gradually being lost. The deeply stained zone (2) consists of an area in which cell proliferation is taking place, and from which the vascularisation proceeds which ultimately effects the absorption and contraction of the infarct. The hæmorrhagic varieties contrast with the preceding; in the kidney they are frequently multiple, there is much extravasation and the renal tissue is disintegrated and stained by the red colouring matter of the blood; they are surrounded by a bright area of congestion in which the capillaries are dilated and many of the renal tubes filled with blood casts. In the kidney a fatty degenerated and wedge-shaped suprarenal rest must not be mistaken for an infarct.

Reference has already been made to the so-called calcareous, uric acid and bilirubin infarcts. In the splenic infarct the extravasation is very extensive and the same may be said in the case of lung infarcts.

The infective infarct differs from the above simple forms, in that the embolus or thrombus which produces

* This accords with the anatomical distribution of the vessels; the portion of the cortex immediately adjacent to the capsule is supplied by outside vessels.

it is infective and is therefore followed by secondary results, such as intense inflammatory reaction and usually abscess formation.

In the liver, an unusual seat of infarction, Wooldridge produced hæmorrhagic infarcts by the injection of thymus extract. He explained this result on the ground that the thrombi formed, were *active* though not infective, and that they led to marked chemical changes in the area of the thrombosed vessels; these changes were especially manifested by the rapid hæmorrhagic exudation throughout the area of infarction.

Changes in the tissues of the heart and vessels.—*Fatty degeneration* occurs both in the intima and endocardium, and in the muscular fibres of the heart and vessels. In the former situations it leads to slightly raised opaque patches, sections of which show the endothelial cells in process of fatty degeneration. The fatty degeneration of the muscular element is very obvious, especially in the heart where the process has already been described, p. 76, **Fig. 28.** In this organ the degeneration may be general as in diphtheria, or scattered as is often seen in severe anæmic and chlorotic conditions; like fibrosis the change is early seen in the musculi papillares.

Pronounced *hyaline* rather than cloudy changes are occasionally seen in the cardiac muscle fibres. In the smaller vessels and capillaries hyaline changes were long ago laid stress upon by Klein in cases of scarlatinal nephritis, but similar changes are met with in other febrile conditions. *Pigmentary degeneration* of the muscle fibres is occasionally observed, and gives to the heart a deeper red brown tint. *Fatty infiltration* of the cardiac muscle is often very pronounced, the

infiltration spreading from the region of the coronaries; very marked examples occur in overfed animals. *Calcification* of the muscular fibres of the vessels is not uncommon as a senile change; it is, however, more frequently seen in the intima of atheromatous vessels and in sclerosed conditions of the valves, much less frequently in the endocardium. *Amyloid degeneration*, which is so common in the walls of the small vessels (*see* p. 81), is only rarely met with in the endocardium.

Myocarditis.—On page 27 will be found a description of **Fig. 7,** a section of *acute pericarditis.* The inflammation was more or less limited to the pericardium, and was manifested by an abundant small round celled infiltration and a fibrinous exudation on the free surface. After healing a considerable amount of sclerosis is left in the pericardium and the fibrin exudate becomes vascularised. The latter process takes place in the manner described in thrombus organisation. There is early canalisation; the endothelium proliferates and grows amongst the trabeculæ of fibrin, and gives rise to a lacunar system in communication with the cavity and fluid of the pericardium, there is then the new formation of capillaries and small vessels which are derived from the nutrient vessels of the heart. In *acute myocarditis* there is an abundant small round celled infiltration most marked around the small vessels; the muscle nuclei appear to largely share in the proliferation, whilst the muscle fibres occasionally show hyaline changes. In *chronic endo- and myocarditis* there is a very considerable overgrowth of dense often hyaline fibrous tissue, which rapidly leads to the atrophy and disappearance of the

muscular fibres and to the thinning of the cardiac wall. These changes are well seen in **Fig. 85.**

Valvular endocarditis.—**Fig. 86** is a section of the aortic valve, close to the free edge of which is seated a polypoid vegetation. It was from an acute case of endocarditis, not apparently of mycotic origin. The tissue of the valve is much swollen, especially near the edge, and has ruptured at one or two places; at these spots a polypoid hyaline thrombus is intimately adherent. In the mycotic valvular affections of which *ulcerative endocarditis* is a type, numerous species of bacteria, including the pyogenic staphylococci and streptococci, bacilli and diplococci, excite a rapid inflammation followed by necrosis of the valve tissue and adjacent portions of the endocardium; spreading scraggy ulcers are formed, upon which clots readily form. The necrosis of the valves is sometimes very rapid, and is of the kind known as coagulation necrosis; the disintegrating tissue is a fertile source of infective emboli, and both rupture and aneurism of the softened valves are very frequent. The micro-organisms can as a rule be readily demonstrated in the hyaline necrotic mass by Gram's method. *Chronic valvular endocarditis* is common, and usually leads to marked thickening and distortion, or even fusion of the valves. The process is quite analogous to that which occurs in the sclerosed patches in the intima or endocardium; proliferative changes in the valves are followed by the formation of hyaline and partly structureless connective tissue, which may further become the seat of fatty and calcareous changes. A new formation of vessels in the thickened valves appears often to occur. Rupture of the surface, as in

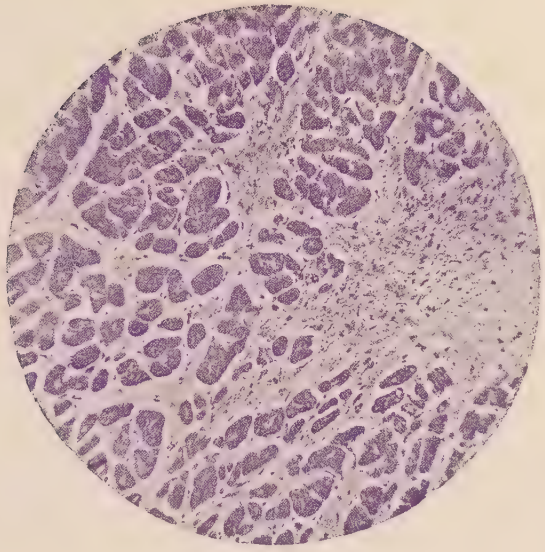

Fig. 85. CARDIAC SCLEROSIS

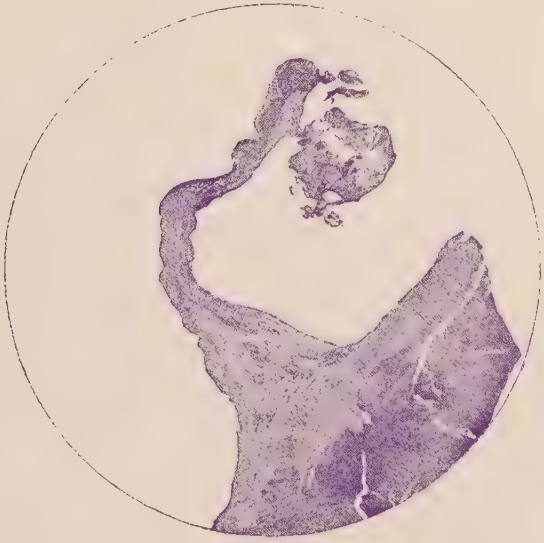

Fig. 86. VEGETATION ON AORTIC VALVE.
(Acute Endocarditis.)
The "vegetation" is attached to the valves by a very delicate stalk.
Obj. 4 in. (Logwood)

atheromatous patches, may take place and lead to the formation of fibrin masses.

Arterio-capillary fibrosis, endarteritis and atheroma, endocarditis, nodose and diffuse periarteritis, phlebosclerosis.

Both the arteries and veins, but especially the former, may exhibit extensive degenerative changes in their coats. This may result from such causes of widespread fibrosis and degeneration as old age, alcoholism, syphilis and gout, or from some purely local cause. The most striking alteration occurs in the intima, but careful examination of the whole wall reveals the fact that all three coats are diseased. Vessels of all sizes, from capillaries to the aorta, are affected and perhaps the term *arterio-capillary fibrosis* of Gull and Sutton is therefore more suitable to this condition than any other. In the kidney the change is very obvious in the glomeruli where proliferation of the endothelial and connective tissue corpuscles is followed by hyaline transformation and condensation (*see* Kidney). In the small renal vessels (efferent arterioles, &c.), and in the small vessels of the brain, and of the other organs and tissues, and especially in the vasa vasorum, the intima becomes considerably thickened by an increase of hyaline fibrous tissue; there is usually at the same time considerable spreading periarteritic fibrosis. Sometimes the endarteritis, at other times the periarteritis, is most marked. The muscular coat usually early shows signs of degeneration, consecutive for the most part to fibrous tissue overgrowth. In vessels of the size of the radial or basilar and upwards, and in the endocardium whilst uniform fibrosis does occur, yet it is more usual to find the sclerosis most advanced

at certain spots, viz., at the mouths of branches, in the heart-valves, in the arch of the aorta, &c., at places, that is, which are subjected to more strain; after a time the patches become more abundant and irregularly distributed. This condition has been termed *atheroma* or *endarteritis nodosa*.

Fig. 87 typically exemplifies the above changes in the basilar artery. The lumen of the vessel is triangular and narrowed, an alteration which is caused by the remarkable thickening of the intima at two places in the wall. At 1 the normal thickness of the vessel is seen, the elastic lamina serving to indicate the relative thickness of the coats; at (3) the intima is enormously thickened, whilst the media (2) is thinned, and on one side has partly disappeared. Under the high power the thickened intima is composed for the most part of nearly structureless hyaline tissue, corpuscular immediately beneath the endothelium, but quite structureless in the deepest layers, where there are already signs of calcification and fatty change; the elastic lamina has completely disappeared, and in places also the muscular coat. No vasa vasorum are to be seen. **Fig. 88** is a section of an atheromatous plaque on the aorta. At the lowest portion of the figure, the almost normal thickness of the wall is seen; higher up the inner coat (3) swells out and the media (1) is also thickened, but little change is observable in the adventitia under this power. More highly magnified there is an atheromatous deposit in the deepest layers of the intima, consisting of calcareous and fatty matter and cholesterin crystals; the elastic laminæ have disappeared, and more superficially there is the peculiar hyaline tissue already noticed in the preceding specimen. Though the



Fig. 87. FIBROID BASILAR ARTERY.

1. Elastic lamina at a portion of the wall which has a normal thickness.
2. External coat with the atrophied muscular layer in front.
3. The completely changed and thickened inner coat.

Obj. 1½ in., without eyepiece. (Logwood.)

Fig. 88. AN ATHEROMATOUS PATCH ON THE AORTA.

1. Muscular coat somewhat atrophied.
2. External coat.
3. Intima, much thickened and altered.
4. Calcareous and fatty debris.

Obj. 4 in., without eyepiece. (Logwood).

muscular coat appeared thickened under the low power examination with the high shows that it is extremely degenerate. In the adventitia the vasa are very conspicuous owing to the small round celled infiltration around them; in places they are almost completely blocked by endarteritis; tracing them it will be found that they penetrate through the media to the deepest portion of the intima, and that their course is marked by a periarteritic infiltration. The corpuscular infiltration is especially noted in those portions of the inner coat where the necrotic changes have not as yet commenced. In the valves as previously described, and in the endocardium the same atheromatous and fibroid changes may be witnessed. In the smaller branches of the coronaries, as in the vasa, the diffuse endarteritis is often extremely marked. In some atheromatous conditions there is a new formation of capillaries, and as remarked in a preceding chapter, the calcification may give place to true ossification; Thoma has further observed giant cells applied to the atheromatous débris and lying in lacunæ around it.

The changes in endarteritis appear to commence in the deepest layers of the intima, but the elastic and muscular layers early show signs of degeneration; at the same time a small round celled proliferation followed by fibrosis spreads away from the smaller vessels. Many views are however held concerning the causes of the endarteritis. Gull and Sutton stated broadly that there is a "diseased state characterised by hyaline fibroid formation in the arterioles and capillaries which entails atrophy of the adjacent tissues; that in the kidney the contraction and atrophy due to the connective tissue is well marked, and that

though the morbid condition is allied to a senile change, it may yet be due to distinct and as yet unascertained causes." Thoma regards the thickening of the intima as a compensatory process (compensatory endarteritis). He supposes that the degenerate vessel tends to dilate and to thereby slow the circulation; the slowing leads to hyperæmia of the vessels, and to a consequent connective tissue new formation in the intima which narrows the vessels. He further states that these changes also occur in the middle and outer coats. Indeed both himself and his pupil Sack regarded the degenerative changes in the media as the primary cause, the cause which led to the dilatation and subsequent compensatory increase in the intima. **Fig. 87** would serve to illustrate these points. Numerous observers have pointed out that the sclerotic changes tend to occur in those regions subjected to much strain. Thus in the heart, the left ventricle is by far the commonest seat of endo- and myocarditic changes, and as showing that a purely local cause may produce a fibroid patch, may be mentioned the case of the "milky patch" on the surface of the heart at the spot most exposed to friction. Such a patch consists of a greatly thickened sub-endothelial layer of dense hyaline tissue and proliferating corpuscles. *Phlebo-sclerosis* is much less common than arterio-sclerosis, but it is seen when strain is thrown upon the walls as in the case of varicose veins.* *Pulmonary endarteritis* is extremely uncommon, but does occur in cases of mitral stenosis, more especially perhaps of congenital origin. Köster regards the atheromatous

* An hereditary proneness to varicose veins is often manifested, and this implies an hereditary weakness of the vessel walls.

patches as due to a perivascular infiltration around the vasa, which first produces a mesarteritis, then an endarteritis. The mesarteritis leads to the destruction of the muscular fibres and elastic tissue. Mott regards the endarteritis as first occurring in the deeper portion of the intima, or the part furthest away from the vascular supply, comparable therefore to the fatty and fibroid changes which occur in the musculi papillaries. That in the atheromatous patches, both in the vessels and in the endocardium, there is a primary endarteritis of the vasa or coronaries as the case may be, which leads to the change, first in the intima, then in the muscular layer. Johnson believes that there may be a general hypertrophy of the muscular coat like that of the ventricular wall, and which may be sometimes confounded with endarteritis.

The changes in the intima in *syphilitic endarteritis*, appear to form almost a type of their own (*see* page 123). It is worthy of note in connection with the new formation of elastic tissue which occurs in syphilitic endarteritis, that Bramwell has observed a similar new formation in those cases of myocarditis which he considered due to syphilis.

Aneurisms.—One of the best examples of an acutely formed aneurism is that very often seen on a valve in acute endocarditis. As previously remarked, the tissue of the valve becomes swollen and soft, so that it is no longer able to withstand the pressure to which it is subjected. It therefore yields at the softest part and bulges into a sacculus, it usually ruptures however before attaining any great size. Infective emboli are a frequent source of small multiple aneurisms; thus

emboli may become detached from the valves in mycotic endocarditis and may lodge at the bifurcation of the smaller vessels. At these places they excite inflammation and consequent softening and dilatation of the vessel walls, and the remains of the embolus or of a thrombus is usually to be found in the sacculus. In the larger vessels emboli may lodge in the vasa and produce softening in their vascular area in the vessel wall and consequent dilatation. Animal parasites may be the source of emboli which excite at places where they become impacted or attached, a slower endarteritis and dilatation. Traumatic injury of the vessel wall produces a like result.*

A miliary nodose periarteritis occasionally affects the small vessels of the brain and its membranes as well as those of other tissues. It is marked by a very abundant local small celled infiltration of the outer coat which extends to the others and is rapidly followed by aneurismal dilatation (miliary aneurisms of Charcot, &c.). Some of these cases as suggested by Ziegler may be mycotic. In the above examples it will be noted that a local arteritis is the cause of the weakening and giving way.

In the heart lessening of the resistance of the wall of the left ventricle through fatty degeneration, acute myocarditis, sarcomatous infiltration, &c., more often results in rupture than in aneurism. On the other hand more chronic endo- and myo-carditic conditions are often followed by aneurismal dilatation. In these

* In some experiments by Dr. Mott, the external coat was carefully cauterised at one spot. The result was a very pronounced swelling of the inner coat and yielding of all three coats at the injured spot.

cases the coronaries are almost if not always the seat of endarteritic changes which have resulted in connective tissue overgrowth and muscular atrophy. A section through the wall of a cardiac dilatation, shows that almost all the muscular fibres have disappeared and that their place is occupied by dense hyaline tissue, with here and there perhaps calcareous and atheromatous foci. A large proportion of the nutrient vessels are endarteritic, and on the ventricular surface laminated fibrin may have been deposited.

In the vessels aneurism is most frequently associated with some endarteritic process, and it is in such a vessel as that represented in figure 87 that the condition is very often seen. Although in this section the wall is considerably thickened at the two endarteritic patches, both the muscular and elastic coats are almost entirely destroyed and therefore with them the elasticity and tone of these portions of the wall. The heart's force therefore acts on the fibrous tissue and gradually stretches it. As the bulging becomes more marked, laminated fibrin very often forms on the surface of the inner coat and becomes intimately incorporated with it, so that the relative thickness of the wall is still further increased. Occasionally the atheromatous patch partially ruptures and the blood may force its way between the coats of the vessel and produce a dissecting aneurism, more usually, however, a sacculated aneurism results. A large diffuse dilatation of the aorta sometimes occurs from weakening produced by *fibroid* degeneration of the wall; and from a still weaker point in its wall (*i.e.*, an atheromatous patch) a secondary sacculated aneurism may result.

Numerous views are held as regards the cause of the

yielding in these cases of more chronic aneurisms. It is agreed that as aneurisms are more common between 20 and 40 and atheroma at a later age, that the former condition does not necessarily follow upon the latter. But as has been pointed out above, old age and general degenerative conditions are not the only causes of endarteritic patches, local causes can equally well act at earlier ages. Thoma regards the relation of arterio-sclerosis to aneurism as indirect only, and that both result from the same cause, viz., weakening of the media. Köster believes that the primary condition is a mesarteritis set up by inflammation around the vasa, proceeding from the adventitia to the media and then to the intima. Eppinger, Recklinghausen and his pupil Manhot look to a primary tearing of the media and especially of the elastic laminæ. Bramwell regards the degeneration of the media as the chief factor and that it may be primary or secondary to changes in the intima.

Chapter XII.

THE ADENOID TISSUES.

In this chapter are included the lymphatic glands, spleen and marrow, tissues which are closely related to the vascular system and usually regarded as *hæmapoietic.**

Insoluble foreign particles introduced into the tissues, either by way of the lungs as in the various dust inhalation diseases and experiments; or through the intestines, skin, or by subcutaneous injection, soon accumulate in the lymphatic glands or spleen. It is probable that at the seat of introduction the wandering cell elements are increased and that they intussuscept the foreign particles and carry them into the lymph stream. Here the cells collect both in the lymph channels of the tissues leading away from the seat of the introduction and in the lymph channels of the lymphatic glands. For example in the lung particles of carbon may be found in cells lying free in the alveoli and in the alveolar walls, but they are especially abundant in the interlobular septa, beneath the pleura and in the bronchial glands; a few carbon cells may be found even in the spleen. If the foreign particles are introduced directly into the blood a large proportion is intussuscepted in the spleen. The accumulation of inert foreign particles in the tissues and lymphatic

* Reference will be made to the thyroid in the succeeding chapter.

glands is followed by connective tissue overgrowth and contraction. The pigmented glands are indurated and a section shows considerable overgrowth of hyaline connective tissue in which the pigment is usually distributed. The adenoid tissue is atrophied.

The above changes throw light upon those which occur when irritating substances and particles, very often micro-organisms, are introduced into the tissues or directly into the blood. In localised inflammatory and suppurative conditions of all kinds, a temporary increase in the number of leucocytes in the blood (*leucocytosis*) is commonly present.* There is as already mentioned in the chapters on chronic inflammation a local increase in the small round cells of all kinds; in addition, the nearest lymphatic glands are usually the the seat of hyperplasia (*adenitis*) and the lymph channels leading to them may be markedly swollen in the more severe and acute cases. In typhoid Peyer's patches and the solitary follicles as well as the mesenteric glands undergo considerable hyperplasia (*see* figures in chapter on Alimentary Canal). In diphtheria similar changes are often observed; and in chronic dysentery a diffuse adenoid hyperplasia of the mucous membrane may be very pronounced. The spleen moreover is in many of the more prolonged fevers the seat of overgrowth, especially in those cases in which the irritating bodies are in the circulation. Leucocytosis is very frequently observed† after venesection or accidental

* In a case of osteomyelitis the recorded increase in the number of white corpuscles was very great.

† It has been recorded in Typhoid, Pneumonia, Erysipelas, Septicæmia (puerperal, &c.), Relapsing fever, Glanders, Small-pox, Tuberculosis. It is also observed in cases of Cancer, but more precise information is still wanted concerning this.

hæmorrhage in the human subject or experimental in the horse (Mosler), or in the dog (Muir and others). Different views are held as regards their production in these latter cases and there may be probably more than one cause; perhaps the withdrawal of the blood acts as a stimulant to the white corpuscle-forming tissue.* In the inflammatory conditions the leucocytosis may be accounted for by the increased production of the wandering cell elements in the lymphatic tissue at the seat of inflammation or in the hyperplastic glands or spleen. The hyperplasia in the lymphatic glands gives place after a time to connective tissue overgrowth and induration as in the case of pigmented glands; there is often in addition thickening and induration of the lymphatic channels which lead from the source of inflammation. The enlarged spleen may as in the case of Malaria undergo very considerable fibrosis.

Contrasting with the preceding group of temporary glandular hyperplasia and leucocytosis are the very numerous cases of true lymphatic tumour formation and permanent leucocytosis.

The tumours vary somewhat in microscopic structure and especially so in distribution and in gross anatomical form; and the absence or presence of an increase of white corpuscles in the blood is likewise the subject of much variation. There are cases of adenoid overgrowths, localised or diffuse, the LYMPHO-SARCOMATA

* Litten and Orth have recorded a very great increase in the number of nucleated red corpuscles in the marrow in dogs after bleeding. Muir in recent experiments has also found them in the marrow and blood of bled dogs and in the human subject after long continued hæmorrhage.

or LYMPHOMATA, which may involve the kidney, testis, liver, thymus and probably the central nervous system, bones and other organs. There are other cases in which the adenoid tissues throughout the body are the seat of tumours. When the glands are more especially involved, the cases are usually described under the term LYMPHADENOMA and the tumours are called lymphadenomata. In these cases there may or there may not be an increase in the number of white corpuscles of the blood; if there is a marked increase they are usually classed under LEUKÆMIA or LEUCOCYTHÆMIA with the prefix *lymphatic* to distinguish them from the other types *splenic* and *medullary* leukæmia, in which either the spleen or marrow is especially involved. Whether there is any fundamental difference between any of these cases will be better determined after the descriptions which follow.

Lymphomata or *lympho-sarcomata.*—Reference has already been made (p. 150) to this class of tumours. They consist of small round cells and of a delicate reticulate stroma. They are infiltrating growths which spread along the perivascular lymphatic channels in a very characteristic manner. Examples are seen in the central nervous system where the perivascular system is sometimes beautifully traced out by the growth. The lymphoma forms one of the commonest tumours of the mediastinum where it either starts from the thymus or the lymphatic glands. In this situation it "creeps along the bronchial and vascular sheaths and guided by the lymphatic paths invades either the lung, heart or other structures" (Douglas Powell). Sometimes the growths are multiple, spreading along the bloodvessels in the kidney, liver, or amongst the

muscles. In the above cases examination of the blood is usually not practised.*

Lymphadenoma or *Hodgkin's disease.*—The way in which a tissue system like the adenoid may be the seat of multiple diffuse or localised tumours, is quite similar to what was observed in the case of the fibroneuromata of the nervous tissues. Variations in consistence, in richness in corpuscles, in rapidity of growth, and in the tendency to remain localised or to invade surrounding structures will be noted just as in the case of neuromata.

The tumour formation may be limited to the adenoid tissue or lymphatic glands of a particular region. The glandular affection is the commonest and according to Gowers the glands most frequently diseased are in order, the cervical, axillary, inguinal, retro-peritoneal, bronchial, mediastinal and mesenteric. The enlargement may take place slowly or rapidly, in the former case which is the commoner, they are hard, in the latter soft. They may remain a long time encapsuled and separate, but the adenoid tissue may break through and invade the tissues and unite with that of the other glands. Sections of the softer tumours consist almost entirely of small lymphoid cells with some epithelial cells, and of a reticulate stroma. In a section of a hard tumour whilst there are numerous small cells at the periphery or scattered in groups, there is at

* Kelsch and Vaillard have recently recorded a case of a rapidly growing small round celled tumour in the lower eyelid of a soldier of twenty-four. Recurrence rapidly took place after removal and with it very marked anæmia and cachexia. There were numerous growths in the bones.

Fever, often intermittent, and profound anæmia may be present in cases of lymphomata.

the same time a very universal increase of the reticulate framework, often hyaline in character; where the latter change is present the number of corpuscles is diminished. The epithelioid cells may be readily recognised, as well as numerous transition forms to large uni- or multi-nucleated corpuscles or still larger giant cells. This alteration in the appearance of the gland tissue is well shown in **Fig. 91.**

Nodules of new growth may appear along the course of the lymphatics in various localities. The Malpighian bodies on the branches of the splenic artery are frequently affected. Of these only a few or the majority may be diseased; in the former case the tumours may reach a considerable size and contrast markedly with the splenic tissue around ("suet masses"). In the *miliary* form the bodies may remain very small. Owing to one or other of the above forms or to diffuse overgrowth of the adenoid tissue the spleen may reach a very great size and be either irregularly or uniformly enlarged. An increase in the splenic pulp as distinct from the Malpighian corpuscles is described. Sections of the enlarged spleen vary, but as in the glands marked increase and hyaline changes in the stroma with a diminished number of corpuscles is very frequent. Patches of pigment and areas of necrosis (which probably constitute some of the "suet masses") may be found. In addition to the spleen, miliary forms may occur in the kidney, liver, lungs and peritoneum, where the appearance may be strongly suggestive of tuberculosis; in the alimentary tract, Peyer's patches and the solitary glands may be solely affected or the lymphoid follicles in the pharynx, root of tongue and tonsils.

Diffuse infiltration occurs in many of the organs, but it is especially well marked in the alimentary canal where it leads to more or less extensive thickening of the walls; noted examples have been recorded in the duodenum, at both orifices of the stomach and in the œsophagus. In other cases, the thymus, testes or the liver may be the seat of diffuse infiltration.

Coverslip preparations of the blood show that the number of white corpuscles is often increased; where the increase is very marked the case is reckoned as one of leukæmia.

It is worthy of note that in one case recorded by Gowers the tumours had involved the solar plexus and had produced bronzing of the skin.

Leucocythæmia (Bennett) or Leukæmia (Virchow).—A large excess of leucocytes in the blood associated with tumour formation in the spleen, lymphatic glands or marrow characterises leukæmia; and there are thus three principal types, the splenic, lymphatic and the medullary or myelogenic, of which the former is by many regarded as the most characteristic.

In lymphatic leukæmia the adenoid tissues are the seat of local or universal soft lymphadenomatous growth as previously described in Hodgkin's disease. The infiltration of the tissues is sometimes extreme, especially in the alimentary canal, root of tongue, pharynx, sometimes even in the nasal cavity, &c. The white corpuscles in the blood are, according to Hyem and other authorities, similar to the adenoid corpuscles of the tumours, and are for the most part small round uninucleated forms.

In medullary leukæmia a notable alteration and overgrowth of the medulla is one of the most striking

anatomical changes. The increase is sometimes very great, the overgrowth of the medulla in true tumour fashion sometimes leading to the softening and expansion of the bony wall. The growth replaces the fat and the marrow assumes various tints from grey to a purple splenic pulp-like appearance. Neumann described two forms, a lymphadenoid in which the lymphatic tissue of the marrow was increased, and a pyoid in which the cells were larger. The excess of marrow and its alteration is probably in the majority of cases due to adenoid infiltration and precisely similar to what occurs in other organs and tissues. In medullary leukæmia the adenoid growth is mostly confined to the osseous system, but similar changes may be seen in lymphatic and splenic types, or they may be altogether absent. In an adenoid overgrowth in the marrow it is possible that the cells may run a greater chance of getting into the circulation; witness for instance the large increase in corpuscles which has been referred to in a case of osteomyelitis, and the readiness with which fat embolism occurs after a fracture. Whether in the marrow, other hæmapoietic tissue than the adenoid may be the seat of neoplastic change, is difficult to decide.

In the splenic variety, the splenic enlargement is very striking. In many cases this enlargement is undoubtedly due to an obvious adenoid infiltration. But it has been considered characteristic of this variety that the *pulp* only is increased and that the Malpighian corpuscles may remain small. It is however very difficult to decide this point from sections. In support of special splenic and medullary types might be mentioned the statement of Hyem that in these forms large

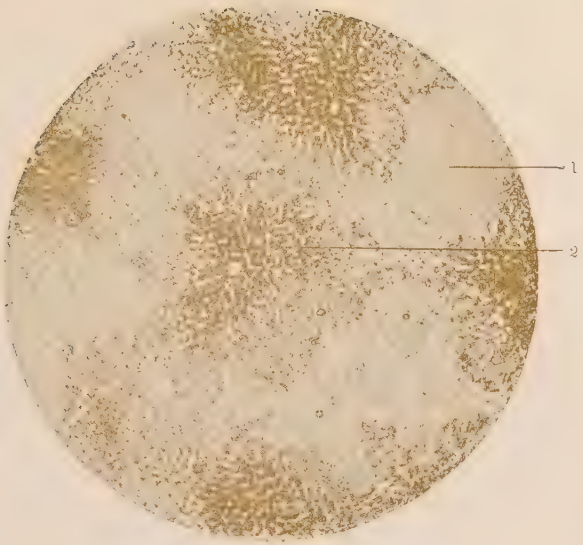

Fig. 89. LIVER. LEUCOCYTHÆMIA.
(Pearly infiltration).

The hepatic lobules, 2, are surrounded and invaded by lymphoid cells, 1.

Obj. 1 in., without eyepiece. (Osmic acid

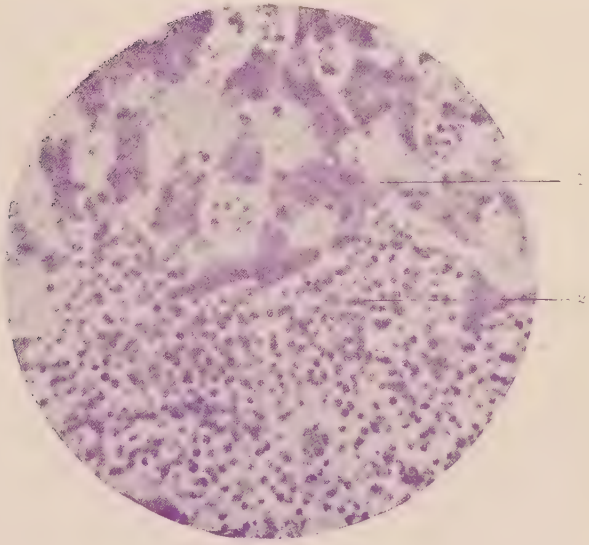

Fig. 90. The same under ⅛ obj.

1. Liver cells undergoing atrophy and degeneration
2. Lymphoid cells

(Lockwood

white corpuscles and nucleated red corpuscles are most frequently present.

Changes in the tissues.—The *liver* is very frequently the seat of adenoid infiltration, which follows the lymphatics beneath the capsule and along the portal canals. In the slightly magnified section, **Fig. 89,** the perilobular growth is extremely well marked and suggests the naked eye term "pearly infiltration" which has been applied to this form of liver. The section has been treated with osmic acid and the liver cells have stained brown, whilst the tumour corpuscles have remained almost colourless. Under the high power, **Fig. 90,** the relation of hepatic and lymphoid cells is seen; the former are separated from one another and are undergoing atrophy and degeneration; the growth consists of small nucleated corpuscles and of a delicate reticulum. The growth is usually by no means uniformly distributed throughout the liver; a common seat is immediately beneath the capsule where there may be a very thick growth; or it may occur in the miliary form, small growths being collected around the smaller branches of the portal canals. Similar changes may occur in the kidney but they are much less common. In both organs however secondary parenchymatous changes are extremely frequent. In the kidney the fatty changes are sometimes very obvious, and it is also worthy of note that in this organ crystalline deposits are frequent in the interstitial tissue; they are said to be composed of uric acid. In the liver dark brown granules may be conspicuous in the cells.

The *spleen.*—The enlarged spleen is on section firm and several large pale or blood-stained areas are

usually to be seen, some in the substance of the spleen, others at the periphery where they are often typically wedge-shaped. On microscopic examination of such a spleen, a striking change is the great increase of hyaline stroma and connective tissue and corresponding diminution in number of corpuscles. The capsule and trabeculæ are greatly thickened and from them proceeds the thickening in the reticulum; in places there is a marked connective tissue overgrowth composed of elongated spindle cells and proliferating endothelial corpuscles; here and there also patches of pigment and groups of adenoid cells. The structure of the pale areas varies; they may be composed of masses of red and white corpuscles which do not stain and are in all stages of necrosis; or they may be formed by hyaline masses of tissue. The nucleated corpuscles vary in size from small nucleated adenoid cells to very large uni- and multinucleated corpuscles which stain less deeply than the former. In the more cellular and in the less advanced spleens the number of lymphoid cells may be increased. Many of the infarcts and necrotic patches appear to be vascular areas in which nucleated and red blood corpuscles have accumulated and then undergone necrosis.

The *blood*.—The white corpuscles are in great excess and the red corpuscles are greatly diminished; in the several varieties striking alteration in form may occur. The leucocytes may be small and uninucleated or there may be a very considerable number of large uninucleated forms, some may be multinucleated. Alterations in form and size of the red corpuscles also occur. Stress is laid upon the presence of nucleated red corpuscles which according to Hyem are con-

stantly present, even before the anæmia is advanced. The white corpuscles exhibit amœboid movements, but they are not universal (Fagge and Golding Bird, Cavafy, Hyem), and the appearances are often suggestive of degeneration. Karyokinesis occurs in the cells of the adenoid tissue (Bizzozero). *Charcot's crystals* are frequently present in the blood and tissues after death.

Summary.—In lymphoma, lymphadenoma and leukæmia the adenoid tissue is the seat of tumour formation which may break out in one or more places and may assume different types such as the miliary, nodular, diffuse, &c. From the growth a large number of corpuscles may find their way into the circulation. When the overgrowth occurs in certain tissues as in the bone, more corpuscles appear to enter the circulation than is the case in growths elsewhere. It is difficult to state whether there is hyperplasia of some hæmopoietic tissue other than adenoid.

Anæmia, cachexia and fever may be present in all forms but they are most marked in lymphadenoma and leukæmia.

Leukæmia may occur in the new born, and it has been often met with in the lower animals. Bollinger injected the leukæmic blood of a dog into another healthy one, but without result. In this connection it may be mentioned that the vitality of the white corpuscles does not seem great and that *there does not appear much evidence to support the view that the white corpuscles form metastases, at least to any extent.*

In one form of anæmia—*splenic anæmia*—the spleen may be greatly enlarged, but without increase of the white corpuscles. The converse has already been

stated, viz., that the spleen may be apparently normal, but the leucocytes greatly increased.

In another form termed *pernicious anæmia*, the following are the changes observed, and they are for the most part characteristic of any profound cachectic and anæmic state. In the *blood* the white and red corpuscles are diminished; amongst the latter are found small and large forms (microcytes and macrocytes*), poikilocytes and occasionally red nucleated corpuscles; Eichhorst's corpuscles, which are small, 3μ, spherical red corpuscles, are described by some. The marrow is frequently changed; the fatty tissue may be replaced either by a gelatinous or a carmine coloured tissue. In the red altered marrow Cohnheim, Rindfleisch and many observers have described a large excess of red nucleated corpuscles, and some regard the anæmia as due to a failure of the transformation of these elements into red corpuscles. On the other hand Hyem and others look upon the changes in the medullary tissues as secondary and unimportant. The *spleen* may be normal or slightly enlarged. The mucous membrane of the stomach has in several cases been markedly atrophied. *Fatty degeneration* of the heart and glandular organs and *petechiæ* are common accompaniments. Reference has been made on pages 89 and 90 to the *iron pigmentation* in the liver (Fig. 33) and kidneys. These last changes are by Hunter and others regarded as very characteristic, although a few look upon the pigment as derived the from iron administered. (*See* Bibliography).

In chronic inflammation of the lymphatic glands, the endothelioid and connective tissue elements are often

* These terms are also used for leucocytes.

considerably increased and altered, this is especially so in tubercular inflammation. Amongst the changes encountered in the spleen may be mentioned chronic fibrosis and pigmentation. In chronic phthisis, Grohé found an increase in the lymphoid tissues of the marrow in many cases. Similar changes have been observed in other chronic inflammatory affections, both general and local, and in cancer.

Chapter XIII.

ADDISON'S DISEASE, MYXŒDEMA, ACROMEGALY AND DISEASES OF THE BONES AND SKIN.

Addison's Disease.—In this disease the changes in the skin, suprarenal bodies and in the solar plexus call for a few remarks. Bronzing of the skin (*see* p. 91) and mucous membranes, either uniform or in patches is characteristic, and is usually most marked at those spots which are normally pigmented, *i.e.*, the areolæ. According to Leva minute patches of pigment may very frequently be found on the ocular conjunctiva. The heart muscles may also be much darker than normal. If the pigmentation of the skin is to be regarded as a constant feature, disease of the suprarenals cannot, although the frequency of the latter was sufficient to justify Addison in associating them together. The most frequent pathological change in these bodies is their destruction by tubercular tissue, but there are also other lesions such as carcinoma, sarcoma, atrophy, fibroid, fatty and cystic changes; both suprarenals may, however, be extensively involved without bronzing. The changes in the medullary portion of the capsules appear to be the more important, and this has suggested that the disease is due to degeneration of the solar plexus; careful examination has, however, shown that lesions of these plexuses are not constant, but when diseased pigmentation of the ganglion cells has been described as a noticeable feature.

Apart from Addison's disease a ganglionated neuroma of the suprarenal body has been recorded which consisted of medullated and non-medullated fibres and of ganglion cells. Stilling has described in the rabbit hypertrophy of accessory suprarenals amongst the sympathetic ganglia and branches after extirpation of the capsules.*

Myxœdema, Pachydermic Cachexia or Cachexia Strumipriva.—The peculiar mucoid change in the connective tissue has been already referred to, p. 80. In the sheep Horsley succeeded in producing typical mucoid changes by extirpation of the thyroid in his cases sections of the connective tissue show the presence of a large amount of mucinous substance separating the connective tissue bundles.† The thyroid is always diseased; the whole of the gland is often replaced by a delicate fibrous growth, with "only a few scattered and enlarged epithelial cells buried in leucocytes to indicate the former existence of a glandular nodule." According to Horsley the chief characteristic changes which follow extirpation of the thyroid may be grouped in order of severity into the *neurotic*, *myxœdematous* and *cretinic*. The fact that the thyroid of intra-uterine cretins does not develop or early undergoes atrophic changes, so that no traces can be found at birth, agrees with this statement.

Tumours of the thyroid, or as they are termed

* In a large series of experiments in rabbits, Tizzoni describes marked changes in the central nervous system (especially the cord), also in some cases pigmentation of tongue. The observations are not, however, confirmed by Stilling and others, nor by Kahlden in human subject. (*See* references in Bibliography).

† For illustration see Report on Myxœdema. "Clinical Society's Transactions," 1888.

bronchoceles or *goitres*, are according to Schönlein most frequent at puberty and at the age of senile involution. In addition to the fibroid changes described above (fibroid bronchoceles) diffuse and nodular hypertrophies of the gland occur which consist either in a repetition of the follicular structure or of epithelial cylinders only. In the former case the follicles may be larger than natural or one or two may greatly enlarge and form cysts lined by flattened epithelium and containing clear fluid. An intracystic papillomatous tumour is sometimes the cause of a goitre, and malignant typical and atypical glandular cancers are described. A remarkable variety of bronchocele is caused by increase and dilatation of the vessels in the glands (pulsating bronchocele), and many of these cases are associated with Graves' or Basedow's disease. In phthisis according to Defaucamberge the secretory activity of the gland is notably decreased and the colloid substance disappears from the acini, which then take on the form of epithelial cylinders (Horsley).

ACROMEGALY.—This disease is characterised according to Marie by an "hypertrophy in the limbs which manifests itself preferably in the bones of the extremities and in the extremities of the bones." The hypertrophied bone is spongy rather than dense and the subcutaneous tissues and perhaps the cutaneous glands share in the overgrowth of the part. In addition to these changes Souza-Leite gives the following as the most constant. Enlargement of the pituitary body, apparently of the nature of an hypertrophy; corresponding widening and deepening of the pituitary fossa. Changes in the thyroid; persistence of the thymus; hypertrophy of the ganglia of the sympathetic trunks; hypertrophy of the

heart and vessels; marked dilatation and thinning of the walls of the antrum, frontal, sphenoidal, ethmoidal and mastoid sinuses; exaggeration of the muscular impressions in the long bones. Owing to some of the above changes and to hypertrophy of the lower jaw the features are often considerably altered, but the hand is the most characteristic and has gained for itself the term paw-like. The resemblance of this disease to myxœdema is worthy of note.

Hypertrophic Osteo-Arthritis (*pneumonic*).—This disease resembles the preceding, but the fingers are enormously enlarged, the terminal phalanxes being blown out in drum-stick fashion. The long bones are hypertrophied. "Pneumonic" has been applied because very many of the cases have been associated with pneumonic or bronchitic affections.

The terms Pachyacria ossea and mollis have been used (Arnold) to designate overgrowth of a part due either to the bones or to the soft parts.

Diseases of Bones.—In studying the lesions of the osseous system the complex nature of the tissues which are found in the skeleton must be borne in mind. In the preceding pages most of the hyperplasias and tumours of the lymphoid, cartilaginous and bony elements have been described. Attention was directed to the tumours of the vascular connective tissue which included nævi and lipomata, fibrous, round, spindle and myeloid celled sarcomata. In the myeloid tumours giant cells appear to have become very definite connective tissue elements, and to their presence in connective tissue overgrowths generally of bone (under the name of osteoclasts) is due probably not only the absorption of old bone, but also that of the osteoid neoplasms. The lesions now about to be described include (1) rickets,

osteomalacia and Paget's disease; (2) rheumatoid arthritis; (3) tubercular, syphilitic and other changes in bone; (4) certain bony tumours and hyperostoses.

Rickets, Osteomalacia and Paget's Disease.—In examining sections, undecalcified fresh and hardened preparations should always be made in addition to decalcified ones. This is very important as the sections readily reveal whether the bone is soft or hard to cut and whether the osteoid trabeculæ are ossified or not. Of stains, picrocarmine and hæmatoxylin are the most serviceable.

There are many points in common between these three affections. Bone salts fail to be deposited or after deposition are removed; in rickets in the young this shows itself in the non-calcification of the cartilage and in the incomplete ossification of the osteoid trabeculæ; in osteomalacia in the adult, by the decalcification and absorption of the trabeculæ, and in a much less degree by the incomplete ossification of new trabeculæ; in Paget's disease, by the absorption of old bone and a uniform new formation of incompletely ossified trabeculæ. The above changes are accompanied by hyperæmia and the affected bones tend to yield to pressure.

Rickets.—The most marked changes occur at the ends of the long bones, at the junction of the ribs with the rib cartilages and in the cranial bones. **Fig. 92** is a very slightly magnified section of rib at the junction of cartilage and bone, which at this spot is typically "beaded," owing to a very considerable overgrowth of cartilage. The preparation has been strongly stained with a weak solution of hæmatoxylin, thereby rendering prominent the translucent zone of proliferating and

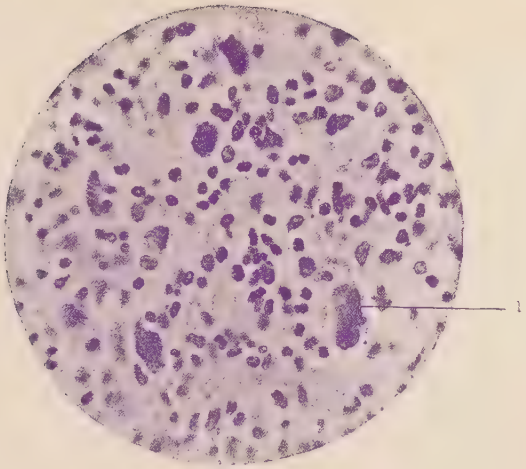

Fig. 91. LYMPHADENOMA.

Section of a gland showing the increase in the ground substance and the small and large corpuscles, 1

Obj. ½ in (Logwood)

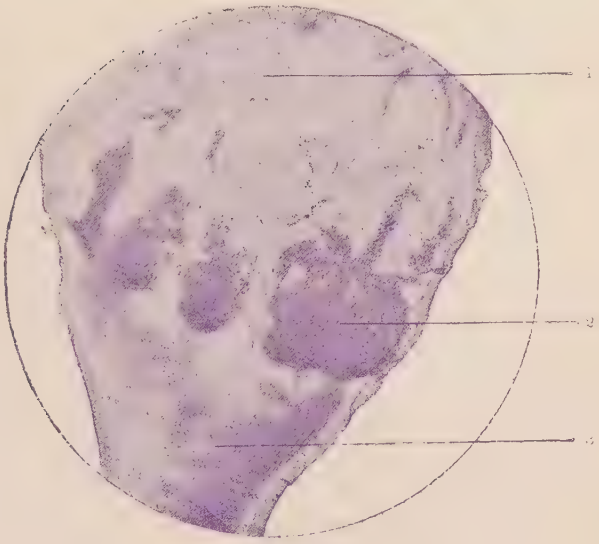

Fig. 92. A RICKETY RIB

1. Zone of osteoid proliferation.
2. Zone of cartilage proliferation
3. The rib cartilage.

Obj. 4 in (Logwood)

swollen cartilage cells. Instead, however, of this zone of transforming cartilage appearing as a thin and regular line, it is composed of large irregular masses (1). When the ramifications of these are traced towards the bone they are found to imperceptibly give place to osteoid trabeculæ, without apparently undergoing any previous calcification; moreover the osteoid trabeculæ are at first imperfectly ossified, if indeed at all. The connective tissue is very cellular and vascular and appears transparent; osteoclasts are present. The The cartilaginous and bony proliferation may be great and give rise to chondromata and osteomata. In some cases the failure of the conversion of the cartilage into bone is extreme, and Stilling has described under the name *osteogenesis imperfecta*, a case in which masses of cartilage remained over in the diaphyses and in which the skull bones had not ossified. In less marked cases small islets of cartilage may be encountered near the epiphyses and unossified spots in the cranial bones; on the other hand soft bony overgrowths on the latter, especially near the free margins, are common.

Rickets occurs frequently in the lower animals and in them the excess of cartilage is well marked. It also often occurs in utero (fœtal rickets) and a cretinoid and an adult rickets are spoken of. Wilks suggested the numerous rickety conditions should be regarded as varieties of osteomalacia.*

* Thus, intra-uterine osteomalacia or congenital rickets, infantile osteomalacia or rickets of young children, osteomalacia of adults, osteomalacia of pregnancy, osteomalacia of insanity and osteomalacia of senility. No doubt there are many disturbances of nutrition which lead to hyperæmia of bone, softening and proliferation.

Osteomalacia or *mollities ossium* is characterised by extensive absorption of lime salts and consequent yielding and distortion in the bones. The process is not one of mere absorption only, the structure of the softened bone being very considerably altered.* In some places the bone may be so soft as to be readily cut with the knife, at other places decalcification is necessary. The regular arrangement of Haversian canals is soon lost and gives place to a meshwork in which the lamellæ run in various directions and the bone corpuscles are scattered irregularly. In some places the osteoid ground substance may have a distinct fibrous appearance. There is a noticeable increase in the connective tissue element, and giant cells are numerous; the fat also and the lymphoid tissue may be much more abundant than normal. Considerable hyperæmia is usual and cysts are occasionally found.

Paget's disease or *osteitis deformans* occurs late in life and is characterised by a uniform overgrowth of the cranial or long bones. The new bone may be dense or porous, but as the long bones usually become bent softening must occur. A large proportion of the cases have been associated with new growths.† One of the best descriptions of the histological changes is furnished by H. Stilling (V. A., 119) who with Paget regards the disease as specific, although possessing many points in common with rickets and osteomalacia. Rarefaction starts beneath the periosteum, osteoclasts in Howship's

* This is not always the case, and sections may resemble partly decalcified bone.

† The nature of these growths have not unfortunately always been stated. See further on for a case of multiple soft osteomata, with bone softening, closely resembling Paget's disease.

lacunæ become numerous and the Haversian canals widen. A new formation of osteoid tissue follows both beneath the periosteum and in the medulla, but the osteoid tissue long remains uncalcified; here and there, however, complete or partial ossification occurs.

Rheumatoid Arthritis, Arthritis Deformans or Spondylitis Deformans.—These conditions are characterised by marked absorptive and proliferative changes in the tissues of the joints of either the small bones (multiple form) or of those of the larger as the hip and knee (monarticular form). In spondylitis deformans the vertebræ are especially affected. One of the earliest changes to be observed in the joint is a roughened or villous-like condition of the cartilages where they are most exposed to pressure. Sections in this stage show that the villi are produced by superficial splitting of the cartilage; this is a degenerative change,* yet deeper down the cartilage cells may be found proliferating. Later the cartilage wears away here and there and exposes the bone; by this time there is very considerable hyperæmia of the joint and absorption of the exposed bone soon occurs, its place being taken by cellular connective tissue and a loose meshwork of bone. Proliferative changes take place in the various tissues of the joint where removed from the friction and pressure. The capsule thickens and synovial fringes hypertrophy (p. 137) to large villous tufts; the cartilage and bone give rise to numerous ecchondroses and exostoses and cysts have also been described in the bone. The

* Dr. Ringer pointed out to me the frequency with which softening and *fibrillation* of cartilage previous to vascular irrumption and ossification occurs in the rib cartilages. The fibrillation is now well figured in Ziegler's "Path. Anat.," b. ii., p. 206.

changes met with in advanced cases, *e.g.*, when the head of the tibia or the acetabulum becomes extensively hollowed out, accord with those seen in the expansion of bone by tumours (aneurisms, new growths, &c.). In both cases pressure gives rise to a vascular connective tissue overgrowth which replaces the bone, and in both osteoclasts share largely in the work of absorption.* Further away the osteoblasts are in both cases stimulated to increased activity and new bone is formed to take the place of that which is absorbed.

Where bony surfaces are exposed to friction rather than to pressure they become dense near the surface and eburnated or polished. If the joints become fixed, connective tissue, or less commonly, bony anchylosis may supervene.

In some lesions of the cord marked joint and bone changes, chiefly atrophic and destructive, occur; this is especially noteworthy in locomotor ataxy (Charcot's joints).

Necrosis, Tubercle, and Syphilis.—There are numerous causes which lead to extensive necrosis of bone, amongst which acute infective periostitis and osteomyelitis, phosphorus poisoning, syphilis, tubercle and trauma are the commonest. Repair thus takes place. Hyperæmia and rarefaction (rarefactive osteitis or osteoporosis) very early occur in the surrounding healthy bone and may extend for a considerable distance. Cellular connective tissue and osteoclasts de-

* Ziegler figures in his "Pathologischen Anatomie," b. ii., p. 193, a good example of the appearance of the phalanx of osteoclasts which may surround a tumour. Myeloid tumours it may be remembered give rise to some of the most remarkable specimens of expansion of bone.

velop abundantly in the rarefied bone which soon completely separates itself from the necrosed area or sequestrum. At the same time new bone commences to be deposited on the rarefied tissue both beneath the periosteum and in the interior of the bone (osteoplastic periostitis and osteitis) and thus tends to wall in the sequestrum. **Fig. 93** serves partly to indicate these points. The new bone is represented by (1), and possesses the characteristic reticulate appearance; it springs from a small piece of shaft (2) which is in process of rarefaction. Between the latter and the sequestrum (3) there is a gap where the bone has been absorbed. If there is complete necrosis of the bone, the periosteum, if intact, forms a new shell which invests the sequestrum. When the proliferative changes are extensive not only is the shaft considerably thickened (*hyperostosis*) but it may be even increased in length, and the bone which is at first porous may afterwards become exceedingly dense or sclerosed. All inflammatory processes readily excite a new formation of bone, thus an abscess or a foreign body such as a bullet may in time become surrounded by a dense bony wall, and corresponding to the seat of a chronic ulcer on the leg a crateriform growth may be found on the tibia. The most conspicuous examples are however furnished by tubercle and syphilis. In tubercle typical granulomata are formed which consist of cellular gelatinous tissue, which replaces the medullary fat. Foci fuse, caseation occurs, and trabeculæ, which are involved, necrose (tubercular ulceration or caries). As the process spreads, rarefactive and ossific changes (proliferation of the connective tissue and osteoblastic elements) occur in the bone in the growing granulation tissue; the

compact bone gives place to a delicate reticulum. If the process is slow the tubercular tissue may become walled in by denser bone; progressive expansion of the bony shell is, however, common. Occasionally the rarefactive and osteoplastic changes are very extensive causing considerable hyperostosis and formation of osteophytes. Sclerosis may occur. If the joints are involved hyperplasia of the synovial tissue and cartilage occurs, and after healing bony anchylosis is common.

The syphilitic lesions of bones are amongst the most frequent of dried preparations in museums. The bones are either thickened uniformly or at one spot (syphilitic node) and the hyperostosis is caused by either dense or porous bone; the latter may be very irregularly deposited. The periosteal *gumma* is described as consisting of soft gelatinous or corpuscular tissue; it causes ulceration and often extensive necrosis of the bone when it spreads and after healing may leave considerable hyperostosis.

Hyperostosis and Leontiasis Ossea (Tumours of Bone and Teeth).—Ilg has figured an enormously thickened cranium in a child, the skull weighing 8 kilos altogether, and another case has been recorded of 5 kilos. In some cases the increase in size of the skull bones is very unequal and to this condition Virchow applied the term leontiasis ossea. Where the weight of the skull or other bones is greatly increased, it may be taken for granted that the structure is dense. There are cases, however, recorded by Paul Gervais and Buhl and there are some specimens in the Musée Dupuytren, where the skull bones are greatly thickened by a porous uniform growth which tends to obliterate the orbits,

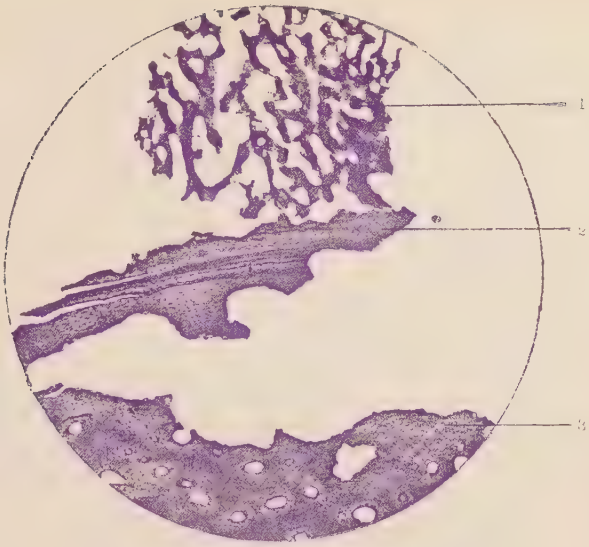

Fig. 93. INFLAMMATORY HYPERPLASIA

1 Spongy new bone. 2. Remains of shaft 3 Sequestrum

Obj. 4 in. (Logwood)

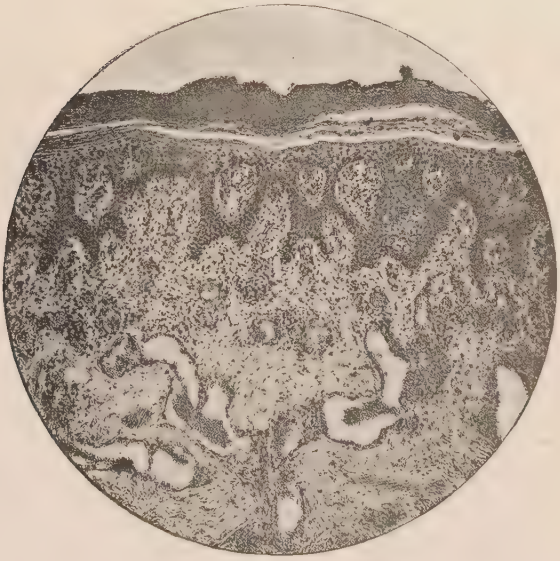

Fig. 94. CHRONIC INFLAMMATION OF SKIN.

(Pityriasis rubra).

Observe the scaling of the horny layers and the infiltration of the connective tissue.

Obj. $\frac{1}{2}$ in., without eyepiece.

antra and other cavities. Recently Spencer* drew particular attention to a very interesting diffuse and uniform soft overgrowth of bone in goats which although it chiefly affected the lower and upper jaws yet might occur in several bones in the same animal. Harley it appears long ago described a similar condition in the horse, and Virchow has referred to a case of soft osteomata in the jaw of the goat. In the case of this animal the advanced growths are readily cut and when macerated the resulting bone is exceedingly light and fragile. Undecalcified sections show numerous osteoid trabeculæ, some ossified, some apparently not; there is an abundance of spindle-celled fibrous tissue and osteoclasts are present. Pollard has described a large diffuse growth of the tibia of a child and from naked eye and microscopic appearances it is probably of the same nature as the tumours in the goat. We think that these and many of the cases of hyperostosis just mentioned belong to the same category, viz., diffuse osteomata or osteo-sarcomata which may occur singly or multiple (compare neuro-fibromata).†

* *See* "Path. Soc. Trans." 1889, for macro- and microscopic descriptions. To the kindness of Dr. Spencer I am indebted for very numerous specimens of the disease.

† Recently I had an opportunity of examining a case which may be allied to osteitis deformans. The compact bone of the long bones was replaced by a weak open reticulum, there was no hyperostosis and the femora were bent. The tables of the cranial bones were occupied by a uniform close reticulum (not hard) and there was slight increase in thickness. Throughout the bones were scattered numerous soft tumours, and in the lungs there was also a very great number. In the bones the tumours were composed of osteoid trabeculæ with very slight central calcification; similar tissue infiltrated the bone. The tumours in the lungs were composed of osteoid tissue, with only here and there faint traces

Lastly, we would direct attention to the hard osteomata (ivory exostosis) which are very often found in the ethmoidal and frontal sinuses and less commonly in the cavities of the antrum and skull. In some cases as when situated in the jaws or antra they clearly possess the structure of dentine and have often in addition a large quantity of enamel. But similar odontomata have been found attached to the temporal and other bones in the cavity of the skull. In addition to dentine odontomata, cementomata are occasionally found in connection with teeth or teeth sacs, especially in the molar regions.

Diseases of the Skin.—The knowledge gained in the preceding chapters, notably in those on acute and chronic inflammation, the infective processes and tumours, will render easy the study of very many of the morbid changes encountered in skin diseases.

There are numerous skin affections which fall under the heading of *inflammation*. Thus in the *erythemata* and in *erysipelas* (p. 101) congestion is a marked feature. The *weal* in *urticaria* is a vesicle (p. 37) due to the raising of the cuticle by an albuminous exudate. The *bulla* in *pemphigus* is similarly caused either by raising of the cuticle or of the whole of the epidermis. The *blister* of a burn or other blistering agent affords the readiest opportunity of studying the formation of the vesicle. The more superficial rete cells swell, loose their nuclei and break down ; fluid accumulates in their place and the horny layer becomes raised. Accom-

of calcification. The structure of the tumours approached closely those of Spencer's cases, and we regard them as examples of malignant multiple osteomata with metastases. (Specimen in University College Museum).

panying the formation of the vesicle in the above cases, there are the other signs of inflammation as congestion and small round-celled infiltration. The *pustule* has also been referred to on p. 37 and the malignant pustule on p. 108. The *small-pox pustule* **Fig. 95** affords yet another example. In this preparation the thinned horny layer is raised by an exudate in which pus cells and the nuclei of rete cells are very abundant. Remains of the rete cells in the form of an irregular meshwork is plainly visible. On each side of the pustule the rete cells (under the high power) are swollen and vacuolated.* The deepest layers of the epithelium are destroyed although this is not always the case, and the floor is formed by the corium which is extensively infiltrated and appears as if it had undergone coagulative necrosis. Should healing occur the pustule gives place to a scab and eventually to a depressed scar.

In *herpes* further examples of vesicles and pustules occur. *Catarrh* (p. 53) is typically represented in *eczema*. In the more chronic form there is congestion and corpuscular infiltration of the corium and epithelium as well as fluid transudation through the latter. There is proliferation of the rete cells and increased desquamation. In the acute form there are vesicles, whilst in the very chronic the epidermis becomes much atrophied and the corium dense and fibroid. In *psoriasis*, which is an allied affection, the epithelial hyperplasia is very much more marked and there is an abundant formation of horny scales (compare with the psoriasis of mucous membranes, p. 157).

* Unna (V. A., 69) lays great stress on the early and marked swelling of the stratum lucidum and of the granular layer.

Ulceration has been described in *Lupus* (p. 56) and referred to under *Leprosy* (p. 119). Other examples occur in *Tubercle* and *Syphilis*. The *perforating ulcer* is a curious pathological process which is closely associated with lesions of the nervous system; from the histological point of view, the great thickening of the marginal epithelium is to be noted. *Rodent ulcer* and *Paget's disease* of the nipple were described on pp. 164 and 165, they are examples of malignant ulceration.

In lupoid, tubercular, syphilitic and leproid diseases of the skin, micro-organisms give rise to characteristic granulomata. In *favus*, *tinea* and in *pityriasis versicolor* (pp. 124 and 125), the higher fungi are the cause of much less marked inflammatory reactions. Animal parasites are the source of other skin diseases. Thus in *scabies* the female acarus scabiei (*see* Parasites) burrows amongst the horny cells, produces eggs and gives rise to many different appearances of the skin. An eczematous state with vesicles and pustules is common; occasionally irregularity of the rete and considerable hypertrophy of the horny layers is observed, and sections of the skin reveal the parasites, adults, larvæ and eggs, scattered throughout the irregular horny layers. In examining sections, search should be made for the ova, which are usually only represented by a shell, the contents having fallen out in the preparation, and for the fæces which are minute (size of nucleus) dark brown irregular masses. *Acarus* or *demodex folliculorum* gives rise in the dog (Sparks) to a very severe rash in which desquamation and loss of hair, scabbing and pustulation are prominent. According to Sparks sections of the skin showed the animal in all stages of development in the sebaceous follicles which they con-

verted into abscesses (*acne pustules*).* In acne rosacea (p. 172) I have observed similar abscesses produced around a brood of the parasite, in the acini of the hypertrophied sebaceous follicles.† Lastly Darier describes a follicular psorospermosis (or keratosis follicularis) in which minute dry papules are formed and in which coccidia can be demonstrated.

The hair follicles are often the seat of interesting changes. Hair follicle cysts have been noted in atrophic conditions of the skin (p. 194). In *ichthyosis* there is an increased growth in the epidermis which expends itself in horny transformation and this is as one would expect particularly evident at the mouths and in the interior of the hair follicles. The increase in the horny material leads either to the formation of plaques on the surface (congenital ichthyosis and other forms) or as in ichthyosis hystrix to irregular horny papillomata.‡ The formation of horny flakes in the crater-like mouths of hair follicles may be observed in other

* Demodex is usually regarded as an epiphenomenon in acne vulgaris, though I think some of the older writers considered it as a possible cause.

† Acne rosacea is usually divided into cases in which the sebaceous glands are hypertrophied and secondly into those in which there is vascular and connective tissue hypertrophy. In the former I have always found demodex in large numbers and cannot but help thinking that it is a factor of some significance.

Pringle describes a congenital adenoma sebaceum and a somewhat similar affection of the sweat glands seem to occur.

‡ These are comparable to the filiform papillæ of the tongue. The papillæ themselves of the tongue are sometimes greatly exaggerated and have been described under "hairy tongues." It is this condition in the tongue which should have received the name of ichthyosis linguæ and not the psoriasis or leucoplacia.

skin affections such as lichen pilaris and lupus erythematosus. But in addition in ichthyosis Esoff has described the formation of epithelial prolongations from the root hairs in many of which there were horny nests; these he considered to be rudimentary hairs. He also drew attention to the extremely bent condition of the hairs in the corium; some were quite horizontal and the arrectores pulled very obliquely. The latter had in some cases even *drawn away* a prolongation of epithelium from the hair follicle. Evidently an impediment to the exit is at least accountable for some of the irregularity of position of the hair, for Esoff further mentions that the sebaceous follicles were atrophied or cystic and that the sweat glands showed signs of cystic change. In congenital ichthyosis bending of the upper portion of the hairs has been likewise recorded.*

Pityriasis rubra, **Fig. 94**.—In this affection there is a very considerable alteration in the appearance of the epidermis. The rete is thinned and the epithelial papillæ assume a comb-like appearance as in the figure; there is an increased formation of horny material which desquamates in large flakes. The cutaneous appendages are atrophied, the corium is infiltrated and the vessels are widely dilated. According to Crocker these changes may manifest themselves in two weeks.

The *sclerodermata* are characterised by a connective

* The occurrence of horny pearls attached to the hair follicles not only in this disease as recorded by Esoff but also in other conditions and even normally in the hairs of the mons veneris (Wertheim), favours a view which I have long held, namely, that the sharply circumscribed horny nests of the squamous epithelio-mata and warts are morphological equivalents of hairs. In connection with this subject may be taken the remark made on p. 195 relative to the formation of horns from hair follicle cysts.

tissue fibrosis and atrophy which leads to a parchment, puckeral or scar-like condition of the skin. To the same cause is due the atrophy of the epidermis and its appendages. Sometimes the change extends over wide areas, at other times it is limited as in *morphœa*. Similar changes occurring in the deeper connective tissue and aponeurotic structures give rise to *Dupuytren's contractures*. The connective tissue atrophy seems always to be preceded by proliferative changes and to be similar to the atrophy observed in scars where, as is well known, the skin often remains silvery, hairless, dry and readily wrinkled. A most typical thick parchment like feeling is imparted to the skin by the slowly growing atrophic scirrhus (p. 175).* There is nothing specific in the nature of the connective tissue changes in the sclerodermata; they are the same which are encountered in all atrophic fibroses and in the causation of which some form of "irritation" plays such an important part.

The large diffuse connective tissue hyperplasias are described under *congenital elephantiasis*, *elephantiasis neuromatosa* and *arabum*, pp. 133 and 134; the *multiple fibromata* on p. 136 and lymphangioma tuberosum multiplex on p. 132.

Note.—To stain Herxsheimer's spirals which appear to be of the nature of fibrin and which are found in the rete, Eddowes after Unna thus employs the Weigert method. Sections from absolute alcohol to Ehrlich's gentian-violet for 5 to 10 minutes. One minute in Gram's iodine. Decolorised with a mixture of xylol (restrainer) and aniline oil (decoloriser) until a clear deep blue tone is observed. Washed in xylol and mounted in xylol balsam.

To demonstrate eleiden granules Schuchardt employs the follow-

* A similar feeling is obtained in these cases where the skin becomes fixed by a severe burn.

ing picrocarmine solution. Dissolve 10 grs. of carmine in 50 grs. ammonia and evaporate to dryness. To the residue mix in 2·5 grs. picric acid and add fifty grs. ammonia and again evaporate to dryness. Dissolve in 250 grs. of hot distilled water and whilst hot filter. What remains in the filter dissolve up in a further 110 grs. hot water and add to the other. Evaporate all again to dryness. For use, a 1 per cent. watery solution may be employed for general purposes, or for the eleiden granules a 1 per cent. solution for 5 minutes on sections from absolute alcohol which are then mounted in glycerine.

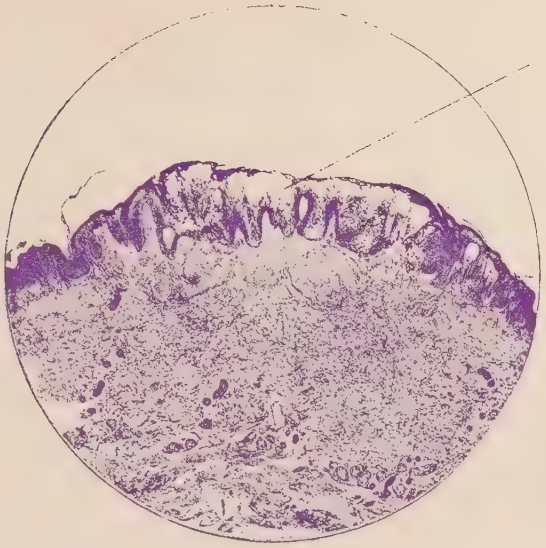

Fig 95. A SMALL-POX PUSTULE

1. The pustule

" $\frac{1}{2}$ in. (Logwood)

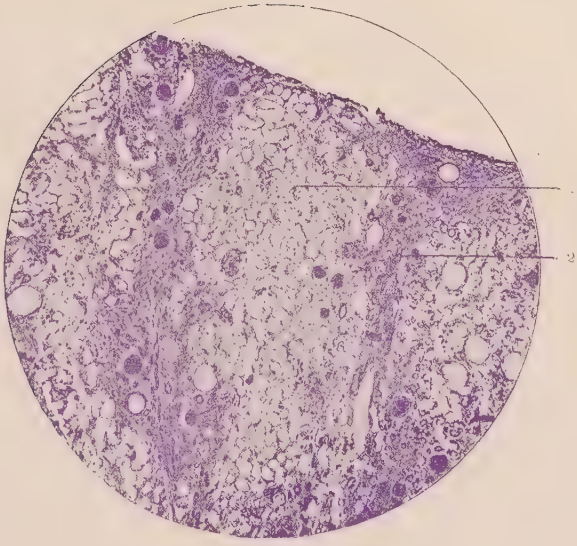

Fig 96. GRANULAR CONTRACTED KIDNEY

1. Area of convoluted tubules.

2. Glomerular and small vessel area in which the fibrosis is well marked.

Obj. $1\frac{1}{2}$ in. Logwood

Chapter XIV.

THE URINARY SYSTEM.

A thorough knowledge of the anatomy of the kidney is indispensable, and attention should especially be given to the following points:—

1. *Vascular supply.*—The terminal system of the renal artery; the comparative sizes of the renal vessels including the interlobular, afferent arterioles and vasa recta, the glomerular and interlobular capillaries; the relative thicknesses of the three coats in the larger vessels; the collateral circulation in cortex and hilus.

2. *Parenchyma.*—Bowman's capsules, the convoluted straight and collecting tubules; that as each collecting tube receives several renal tubules, the kidney is made up of so many independent glands as are represented by the mouths of the collecting tubes; the nature of the epithelium in the various portions of the renal tubes; the smallness of the lumina of the tubules.

3. *Stroma.*—The excessively small amount of stroma in the cortex, its slight increase around the glomeruli and larger vessels and in the pyramids; the thickness of the capsule; the presence of a basement membrane.

4. The grouping of the glands and vessels in the cortex and pyramids. All these points are admirably illustrated by stained sections of a carefully injected complete kidney.

In the post-mortem room, the size, shape, colour, consistence, and the readiness with which the capsule strips off must be noted. The colour of the kidney varies from that of the normal to white, yellow, chocolate, red, and the red of venous congestion. Mottling is produced by contrasts between the changes in the parenchyma, interstitial tissue, and blood-vessels respectively (parenchyma light coloured often slightly yellow, interstitial tissue, white or grey, vessels red). Under shape may be noted gross irregularities in contour, such as depressions and puckerings, or minute irregularities in the form of *granulations;* these latter are pro-

duced both by the contracted state of the interstitial tissue which follows chiefly the lines of the interlobular vessels and by the often dilated condition of the tubes in between; the size and uniformity of the granules must be noted. On section much can be learnt. The relative size and colour of the cortex and pyramids; the presence or absence of mottling; again the presence of granulations, their size, arrangement and distribution; whether the renal artery shows signs of atheroma and whether the smaller vessels stand out rigid on section; the condition of the glomeruli whether more conspicuous than normal. Tests must be employed for lardaceous degeneration and for scrapings of any crystalline salts which may be present (*see* chapter on Degenerations). Small wedge-shaped areas in the cortex should always be carefully examined, for if encapsuled they are probably suprarenal rests.

The correctness with which the naked eye examination can be carried out is immeasurably increased by a thorough knowledge of the microscopic appearances of the various types of diseased kidneys. Sections should be made as large as possible in order that both cortex and pyramids may be examined. Vertical and transverse sections are those usually made, but tangential and sections at right angles to the divisions of the renal artery as they are entering the kidney may be practised. In examining and describing sections, record the changes in the *vessels*, *stroma* and *parenchyma*, commencing with the system most obviously altered. Thus under vessels observe if the lumina are diminished, or if there is peri- or endarteritis; whether the glomeruli are hypertrophied or atrophied and the causes (*i.e.*, hyperplasia of nuclei, hyaline fibroid changes, &c.). The relative number of glomeruli diseased should be noted and also the presence of vessels of new formation, congestion or anæmia. Under stroma, whether it is increased; its distribution, whether uniform, or irregular following the distribution of the vessels, and commencing either around the larger trunks or in the neighbourhood of the glomeruli. Whether the fibrosis proceeds from the pelvis and whether the capsule of the kidney is increased in thickness. Whether Bowman's capsules are fibroid. Whether the stroma is richly corpuscular or not, and whether the corpuscles if present are uniformly distributed or

massed in foci, either around the glomeruli, interlobular vessels or tubes. Under *parenchyma* whether the epithelial cells are swollen, net-like, granular, vacuolated or hyaline, whether the nuclei stain or not. If there are evident signs of necrosis (hyaline or granular protoplasm and unstainable nuclei) ascertain whether the necrosis is uniform or limited to certain gland systems or to certain portions of the tubes themselves. Do not use the term fatty degeneration unless fat globules are proved by the presence of osmic acid or other reliable test. The shape of the cells should be noted, whether swollen, cubical or flattened; whether there is evidence of proliferation; whether the lumina are increased and Bowman's capsules dilated. Whether there are casts. If pigment or crystalline salts are present ascertain whether they are in the tubes or not, and in what part of the tubes. If lardaceous disease is suspected use methyl-violet.

Having ascertained the changes in the kidney an endeavour must be made, bearing in mind the changes in the other tissues of the body and the clinical history, to find out the probable causes and nature of the renal disease. With these ends in view the results of some experiments on the kidney will be first described and afterwards some of the most important varieties of renal disease.

Results of Experiments on the Kidney.*

1. Effect of Poisons.—*Cantharidin*, according to Dunin, whose experience accords with my own, produces hyperæmia of the kidney in the early stages both in the glomeruli and elsewhere. The renal epithelium shows early signs of hyaline transformation and the nuclei here and there commence to lose their power of staining. On about the fifth day the kidney is large and pale and the above mentioned necrotic changes

* Removal or destruction of one kidney leads to compensatory hypertrophy of the other. In wounds of the kidney, there is atrophy of the renal tissue immediately involved in the scar tissue.

more pronounced. The glomeruli are, however, hyperæmic and there is a certain amount of congestion and extravasation. Thus the most noticeable features are the congestion and necrotic changes. On the other hand Cornil and Browicz describe the appearances as still more closely resembling those of acute nephritis, in that the glomeruli are markedly hyperæmic, the epithelium swollen, the capsules and tubes containing leucocytes and hyaline casts. Other poisons as *chromic acid* (Kobierske), *sublimate* (Neuberger), *glycerine*, *toluylendiamin* and *pyrogallic acid* (Afanassiew),* *phosphorus* (Krönig and others) and *alcohol* (Kahlden, Afanassiew), give rise for the most part to marked parenchymatous changes, viz., degeneration and necrosis of the epithelium, especially in the convoluted tubules; sometimes one set of tubes is affected more than another.

The degeneration and the necrosis is marked by granular, fatty, hyaline, reticulate and vacuolated changes in the protoplasm and loss of staining power of the nuclei. Of very frequent occurrence is the precipitation of calcium salts. Congestion and slight extravasation may be present. The changes in the glomeruli may include hyperæmia, shedding of the epithelium and accumulation of extravasated products beneath the capsules, proliferation of the endothelium and periglomerular small round celled infiltration. Although some of the poisons were administered for very long periods, yet there was no noticeable increase in the fibrous tissue. **Fig. 102,** which must be compared with the other figures of the kidney, represents

* The glycerine gives rise to hæmoglobinuria, the toluylendiamin to jaundice.

extremely well the changes seen in *phosphorus poisoning;* it is from the same case as that mentioned on p. 77. Very striking is the faint and unstained appearance of the epithelium (2); here and there, however, patches of straight tubes (1) still preserve their staining power and nuclei. The glomerulus (3) appears slightly compressed as if by the swelling of the parenchyma around. The epithelium of the faintly staining tubes completely fills the lumina and consists of shreddy and vacuolated cells, together with oil droplets and fragments of nuclei. By the prolonged administration of *lead salts*, Charcot and Gombault obtained very profound *interstitial* changes, a typically granular kidney ultimately resulting (according to the above experimenters). The changes consisted of flattening of the epithelium, widening of the tubes, deposition of calcareous salts, proliferation of the glomerular and renal epithelium and increase of the connective tissue around the glomeruli and between certain of the tubes.

2. EXTENSIVE BURNS or the injection of heated blood (Lesser, Afanassiew) produce parenchymatous degeneration, and blood crystals and hyaline casts may be found in the tubes. In man congestion and extravasation may be marked.

3. Inoculation with MICRO-ORGANISMS and the induction of pyæmic and septicæmic states produce in the kidneys both general parenchymatous changes (especially in the case of septicæmias) and focal reactions at those places where microbes are arrested.

These changes are well illustrated in **Fig. 36,** from a case of pyæmia following ulcerative endocarditis. The reaction starts in many cases around the glomeruli, small round cells accumulate and the nuclei

of the epithelial cells even show signs of proliferation; the surrounding vessels become deeply congested and slight hæmorrhages may occur, and the adjacent tubes become occupied by blood and hyaline casts. The renal epithelium in the vicinity, or in severe cases throughout the kidney, may be swollen or undergo granular changes, and the nuclei, especially in the foci, often refuse to stain; later on the focus itself usually gives place to an abscess cavity. A contagious disease in cows* produced by a streptococcus excites a glomerulo-nephritis quite similar, according to Klein, to that of scarlet fever (pp. 33 and 271). As the result of puerperal septicæmia the kidneys may present marked degenerative and necrotic epithelial changes.

4. Ligature of Renal Vein.—**Fig. 101** represents extremely well the early effects of ligature. The renal tubes (2) are widely separated by the over-distended intertubular capillaries (3), and by blood extravasations. The glomerular capillaries (1) completely distend the capsules. The renal epithelium is swollen, granular, vacuolated and may contain oil droplets. To the naked eye the kidney is almost double the volume of the sound one and has a deep purple colour. By the sixth day, however, according to Buckwald and Litten, the kidney becomes smaller and the necrosis of the renal tubes more pronounced. Still later the kidney is smaller than the sound one, there is extensive necrosis, the dilated capillaries have disappeared and there is much granular pigment instead; but according to these authors the glomeruli are fairly preserved, and there is no trace of interstitial overgrowth. Finally complete

* Klein, "Hendon Cow Disease." *Report of Med. Off. of Loc. Gov. Board,* 1885.

atrophy of the ligatured and compensatory hypertrophy of the sound kidney result. Congestion of the kidney is often seen in *cardiac disease;* there is usually at the same time some overgrowth of delicate connective tissue, as well as parenchymatous degeneration. Marked congestion of fibroid kidneys is frequently observed.

5. Ligature of Renal Artery and Branches.—Many important researches* have been made on this subject which throw much light upon the numerous local and general kidney changes associated with disorders of the blood supply. When a branch is ligatured an *infarct* resembling that seen in **Fig. 84** is the result. There is at first hyperæmia throughout the area of infarction; later the hyperæmia becomes confined to the margin, and the central portion soon undergoes necrosis as the result of anæmia. The degeneration and necrosis is marked by fatty, granular, hyaline and calcifying changes and later by disintegration of the cells. Regeneration is effected, as mentioned on p. 213, by the ingrowth of connective tissue from the seat of collateral circulation and proliferation at the periphery. When the renal artery itself is ligatured the changes in the infarct are repeated on a larger scale, although some observers state they can produce changes in the kidney resembling those encountered in interstitial nephritis. Leyden lays stress on the probable analogy, in mode of production (compression of renal artery) and in the resulting changes, between the experimentally ligatured kidney, and the *large white kidney* sometimes observed in *pregnancy* and marked by extreme fatty and necrotic changes. Similarly, endarteritis which is so frequent an accompaniment of renal disease leads to partial

* Notably by Litten, Platen, Talma, Werra, Grawitz and Israel.

anæmia and its results; in marked endarteritis (syphilitic see below) actual infarction has even been described.

6. Ligature of the Ureter.—An exceptionally interesting series of experiments were made by Charcot and Gombault on the one hand, and Straus and Germont on the other. The latter observers with careful antiseptic precautions obtained almost pure atrophic changes. The first effect of ligature was to cause marked dilatation of the glomeruli and tubules and flattening of the epithelium, the cystic changes commencing in the cortex. After some time (one month) the cystic dilatation gave place for the most part to collapse of the tubules, a few only of the capsules remaining distended or further increasing in size. During these changes there was little new formation of connective tissue, a small increase only being noticed in the pyramids and around the vessels. But Charcot and Gombault working without antiseptic precautions obtained very pronounced proliferative changes in the connective tissue and moreover described the dilatation of the tubes as commencing in the collecting tubes. Clearly the marked proliferative changes were due to something more than the mere mechanical effects of ligature and there is every probability in favour of their kidneys having become infected.

In the human subject types of kidney corresponding in many respects with the above, both in the changes due to mechanical impediment and in addition to effects of micro-organisms, are observed as the result of lesions in the lower urinary tract such as stricture, calculous pyelitis, cystitis and reflex irritation (Beck). In the description of these changes Beck's classification into *hydro-* and *pyelo-nephritis* (pressure effects),

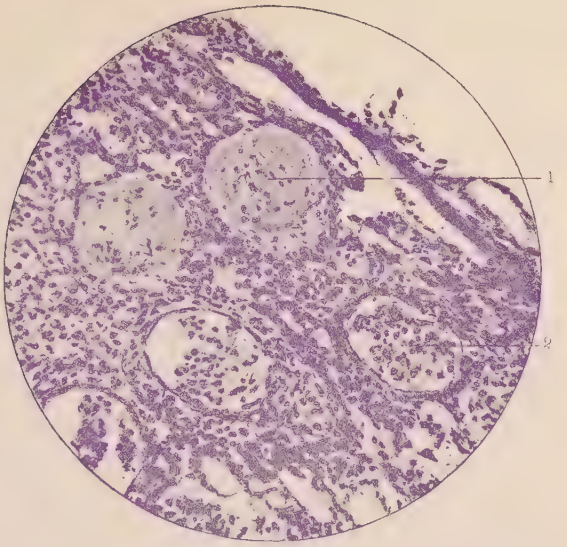

Fig. 97. FIBROUS OVERGROWTH OF KIDNEY (from pyelitic distension).

1. Advanced fibroid glomerulus.
2. Earlier proliferative stage of same. Observe the general interstitial fibroid proliferative changes, and the complete destruction of the parenchyma

Obj. ¼ in., without eyepiece. (Logwood

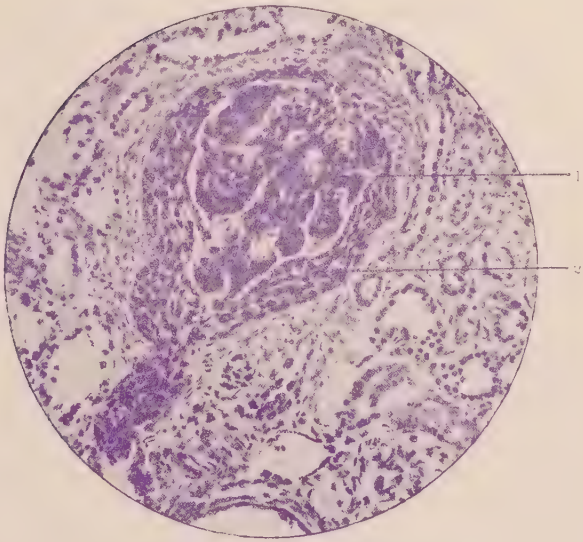

Fig. 98. PROLIFERATION OF GLOMERULUS

From an early fibroid kidney

1. Proliferation of cells of glomerulus.
2. Proliferation of endothelial cells of capsule

Obj. ¼ in., without eyepiece. (Logwood)

diffuse interstitial and suppurative nephritis will be adopted.*

1. Effects of pressure—*Hydro-* and *pyelo-nephritis.* On p. 185, **Fig. 78**, a remarkable acute cystic change is described affecting both the glomeruli and tubes, the kidney being at the same time the seat of parenchymatous degeneration. Although an explanation was then offered, another view might still be held, viz., that the changes were due to compression of the ureter and perhaps in addition of the renal artery, as the case was one of pregnancy. It is more usual, however, in obstruction, to meet with dilatation of the pelvis and atrophy and finally complete absorption of the renal tissue; a few small cysts usually remain and there is very little connective tissue proliferation or small round celled infiltration (*hydronephrosis*, pp. 185, 186). The appearance of such a kidney therefore closely resembles that of Straus and Germont. When, however, a stone is present in the pelvis, the irritation leads to a small round celled infiltration. This is well illustrated in **Fig. 97,** from a case in which the pelvis was dilated and the seat of chronic inflammation—*pyelitis*—owing to the presence of a stone. The kidney substance was reduced to $\frac{1}{4}$ in. thickness and there was no distinction between pyramids and cortex. The section shows that there is complete disappearance of the glandular parenchyma, its place being occupied by a very corpuscular fibrous tissue. The glomeruli are crowded together and atrophied (compare with other figures) so that the renal tissue must have undergone considerable shrinking. Two of the glomeruli have

* "Consecutive nephritis and pyelitis," by Marcus Beck, in Reynolds' *System of Medicine*, vol. v.

been converted into impervious hyaline masses. In other parts of the section Bowman's capsules were here and there thickened and the vessels were extensively invaded by connective tissue, the smaller ones being completely blocked.*

2. *Diffuse interstitial nephritis.*—In this variety the pelvis is not dilated and the kidney is if anything slightly larger than normal, firm or tough, and with a pale or mottled appearance. In a well marked case the kidney is the seat of a uniform, richly corpuscular, vascular, fibrous overgrowth, the only signs of kidney structure being the glomeruli which always stand out either as proliferating groups of nuclei, surrounded by the capsules, or as hyaline fibroid masses. A string of nuclei here and there may indicate the remains of a renal tube, and occasionally they contribute largely to the small round celled infiltration. In earlier stages a connective tissue overgrowth may be found spreading up from the pelvis (p. 186), or small round cells may be grouped around the glomeruli or between the tubes.

3. *Suppurative nephritis*, *suppurative pyelo-nephritis*, (*surgical kidney*), *lymphomatous nephritis* (Wagner).—Such a kidney as the preceding or a pressure kidney (group 1) may become infected from micro-organisms in the urinary tract. In these cases inflammatory reactions either spread from the pelvis over the kidney and are marked by abundant small round celled infiltration (compare experiments of Charcot and Gombault).† Or the small round cells may first

* According to Beck the pressure kidneys, though they may be extremely atrophied, are not accompanied by cardiac hypertrophy.

† The pelvis may in addition ulcerate and foci of suppuration may be formed throughout the kidney (suppurative pyelo-nephritis).

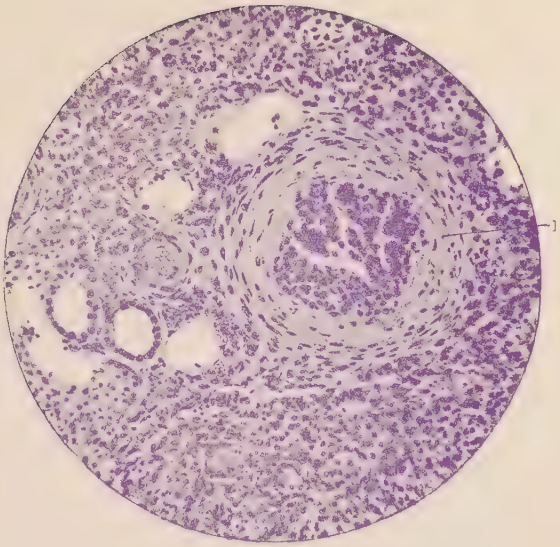

Fig. 99. CONTRACTED GLOMERULUS.

From a more advanced case of fibrosis than the preceding.

1. Hyaline change in the capsule, which is causing compression of the glomerulus.

Obj. $\frac{1}{4}$ in., without eyepiece. (Logwood)

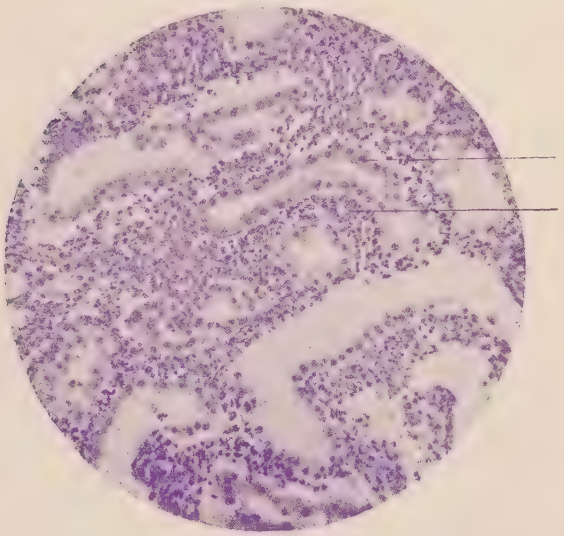

Fig. 100. SMALL ROUND CELLED INFILTRATION OF KIDNEY.

(Surgical kidney)

1. Tubules undergoing degeneration.
2. Small round celled infiltration.

Obj. $\frac{1}{4}$ in., without eyepiece. Logwood.

appear in the neighbourhood of the interlobular vessels or around the convoluted tubes and later give place to suppuration. **Fig. 100** shows a typical leucocytic infiltration between the convoluted tubes, the lumina of which are dilated and the epithelium disintegrating. If the foci are circumscribed they have the appearance of those represented in fig. 38. The kidney is at the same time the seat of congestion and extravasation, cloudy and granular changes are present in the epithelium or there is actual necrosis in the neighbourhood of the foci. Casts, hyaline, blood or leucocytic are often present and sometimes the filling of the tubes with leucocytes is marked.*

DIFFUSE NEPHRITIS DUE TO SENILE AND CACHECTIC CONDITIONS, DIABETIC NEPHRITIS.—The changes met with in these conditions are various, sometimes there is general increase of fibrous tissue accompanied by endarteritis, at other times a special type is assumed. **Fig. 96** is taken from the kidney of a boy, æt. 17, the subject of phthisis and strumous disease of the tibia for seven years. Albuminuria and hemiplegia were present for 52 hours before death. Both kidneys were equally affected.†

The kidney is a typical example of the *granular contracted*, it is firm and uniformly contracted; the granules are due to the bulging of the lobules of the convoluted tubes (1) and the atrophy and contraction of the renal tubes and fibrous tissue in the interlobular striæ (2). The cortex is considerably thinned. The

* Diffuse interstitial nephritis and suppurative nephritis do not appear to be accompanied by œdema or usually by albuminuria (Beck).

† Catalogue of Museum of University College, London, no. 3429.

glandular portions had in the recent state a pale yellow colour, the fibroid striæ a red congested appearance. Minute examination of the latter show that they are composed of dense fibrous tissue in the neighbourhood of the interlobular vessels and around the glomeruli; there is a periarteritis and a new formation of vessels. The glomeruli are much altered and with few exceptions are converted into hyaline atrophied masses; in the adjacent parenchymatous portions some of the glomeruli are in a state of slight proliferation and in other cases the capsules are much dilated (*see* fig. 96). There is evidence in the striæ of atrophy and absorption of gland tubes; in the lobules the tubes are, however, dilated and the epithelium flattened. There is considerable fibroid overgrowth in the pyramidal portion.

In addition to fibroid, endarteritic and parenchymatous changes, *amyloid degeneration*, **Fig. 30,** p. 83, is very common and its presence need not be indicative of suppuration. In occurs in kidneys the seat of early or advanced fibroid changes and may be found in the scarlatinal, tubercular and syphilitic kidneys, &c., but as the albuminoid kidney is usually associated with some of the symptoms of Bright's disease, the types in which it occurs will be mentioned under that disease. In *Diabetes* one can only refer to the secondary parenchymatous and interstitial changes resulting probably from the irritation of the urinary secretion. These include fatty degeneration; necrosis (Ebstein)* and sometimes advanced cirrhosis. Glycogen may in addition be present in Henle's loops (Fichtner).

* Also produced by administration of acetone (Albertini and Pisenti).

Fig. 101. CONGESTION OF KIDNEY.

The tubes and glomeruli 1 and 2 are widely separated by engorged capillaries and extravasated blood 3.

Obj. ¼ in., without eyepiece. (Eosine and logwood.)

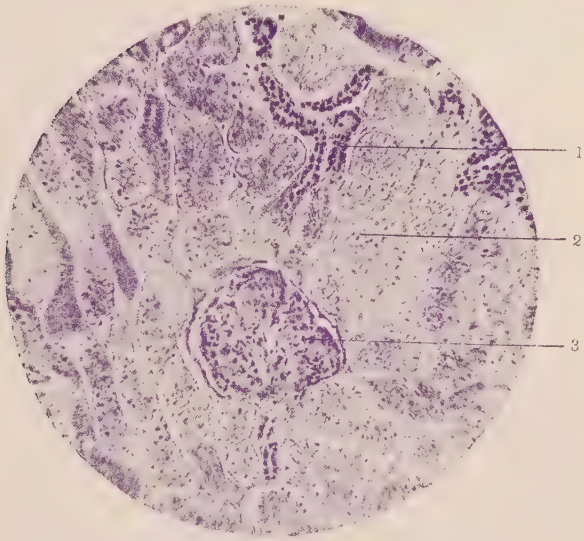

Fig. 102. PHOSPHORUS NECROSIS OF KIDNEY.

1. Renal tubes scarcely affected.
2. Convoluted tubes almost completely necrosed.
3. Glomerulus.

Obj. ¼ in., without eyepiece. (Logwood).

THE SYPHILITIC KIDNEY.—This is a very important variety owing to the pronounced local endarteritic changes which early occur. In one case of the disease in the adult I was able to observe the following, viz., marked endarteritis and periarteritis; nuclei of glomeruli greatly increased but no fibroid glomeruli; small round-celled infiltration and fibrous overgrowth around root of glomerulus; early proliferative changes along the minute vessels but no marked interstitial overgrowth; here and there proliferation of renal epithelium. Greenfield records a case in which the endarteritis led to infarction. Gummata have been much too hastily diagnosed in the kidney.

THE ACUTE NEPHRITIS OF FEVER.—The kidneys of typhoid and diphtheria serve as examples, although there are numerous acute specifics which are accompanied by acute nephritis and albuminuria.

Fig. 12 illustrates the changes. The glomeruli are enlarged, owing to swelling of the interstitial substance and to engorgement of the capillaries and often swelling of the endothelial cells; there is in addition an increase in the number of nuclei in the glomeruli due partly to leucocytes partly to proliferation of the various cell elements of the glomeruli. Bowman's capsules may be slightly distended, their endothelium swollen or proliferating and the spaces occupied by fibrin or white or red corpuscles. There may be an increase in corpuscles around the roots of the glomeruli. The tubules may be dilated, the epithelium swollen and granular, or there may be some proliferation. Casts are numerous, though usually hyaline they may consist of blood. Small hæmorrhages are frequent, especially in diphtheritic kidneys.

In the above descriptions a brief account has been given of the various parenchymatous, interstitial and vascular changes brought about by anæmia, compression, congestion, poisons, micro-organisms, or naturally in the course of senile decay, cachexia or fever. These changes have embraced cloudy, granular, fatty, hyaline and atrophied changes in the renal epithelium, necrosis, or on the other hand proliferation; cystic dilatation of tubes, glomeruli or pelvis; fibrous overgrowth, uniform or seeking out certain paths and associated with endarteritis or periarteritis, and in structure dense or very cellular and sometimes combined with amyloid degeneration. The changes were grouped together into various varieties of nephritis. There yet remains to be considered another class of nephritis in which structural changes similar to the above are found; they are grouped into a few fairly well-marked types and are associated with the train of clinical symptoms included under the term Bright's disease.

The nephritis of Bright's disease.—Two clinical types of Bright's disease are usually given, one in which there is œdema and a small quantity of urine of high sp. gr., the other in which the urine is increased, of low sp. gr., with or without albumin, the heart hypertrophied, retinitis, or only slight dropsy.* Corresponding to this division there are two principal types of nephritis, one in which parenchymatous changes are conspicuous, the other in which interstitial changes are the more striking; the former usually associated with the œdema, the latter with the polyuria and cardiac hypertrophy. The association is, however, not constant.

As scarlatinal nephritis affords an opportunity of

* Uræmic symptoms may supervene in both.

studying some consecutive stages in the renal changes of Bright's disease it will be first dealt with.

Scarlatinal nephritis and its developments.—It develops as an acute nephritis, or better glomerulo-nephritis, and as such shows parenchymatous and interstitial changes as already described above p. 269 and early on p. 32, Fig. 12. At a little later stage the perivascular corpuscular infiltration is more marked especially around the glomeruli and interlobular vessels. Fourteen months after the first attack Greenfield* describes a case ending fatally in which the kidneys were *large* and *white*. Sections showed extreme interstitial proliferation and disappearance or cystic dilatation of the renal tubes; proliferative changes in and around the glomeruli and around the vessels. Such a kidney is an example of a large *diffuse interstitial nephritis* gradually developing from the acute glomerulo-nephritis. Another variety, the *large soft white kidney*, to be described afterwards (Fig. 103) in which the interstitial changes are not so pronounced, is also mentioned as proceeding from the acute scarlatinal kidney. Further Greenfield mentions the case of a kidney of a child of 10, which came under examination two years after the first attack. The kidneys were very small, tough, puckered and full of granulations on the surface and in section;† the pelves were dilated. Sections of such kidneys would show a structure somewhat like that depicted in **Fig. 96**

* Greenfield, in New Sydenham Society's "Atlas of Pathology," articles on the kidney. There is much information to be obtained especially on scarlatinal nephritis. The coloured illustrations are admirable and are striking pictures of the various diseased types of kidney.

† "Atlas," fascic. I., plate iii., figs. 1, 2, 3.

only in a more marked degree. Overgrown fibrous tissue surrounds small islets of dilated tubes; a large number of the glomeruli are converted into hyaline fibroid masses and a large proportion of tubes are atrophied or have completely disappeared; the vessels would in most probability be the seat of endarteritis. Such kidneys are examples of the *granular contracted.*

The types described above proceed from an initial glomerulo-nephritis, but there are other forms of the nephritis of Bright in which there is no history of previous ill, though the changes found in the kidneys must in many cases date back from a remote period. In these cases it is much more difficult to say how the changes commenced and what the causes are, and the following descriptions can only aid in a very small way to elucidate these points.

From the anatomical standpoint, the changes will be divided only into *interstitial* and *parenchymatous*, and only the more striking and constant of the naked eye forms assumed by both varieties will be referred to.

Interstitial nephritis, including the *granular*, *arterio-sclerotic*, *gouty*, *lead* and *alcoholic* kidneys. Interstitial nephritis may occur in the quite young; it is, however, much more frequent in later life. The kidney may be enlarged or normal sized, but is more usually contracted; in colour, pale, chocolate or red, and with a capsule which is usually adherent. The new connective tissue is either dense and fibroid or corpuscular; it starts around both the large and small vessels, favourite seats being the roots of the glomeruli and interlobular vessels; and according as it affects the kidney uniformly or in patches, a uniform or irregular fibroid kidney results. The granulations may be regular as in **Fig. 96** owing

to the uniform interlobular fibrosis. The pyramids are often extensively fibroid. Of great importance are the changes very frequently observed in the vessel walls. They may be affected secondarily like the tubes by the invasion of the perivascular tissue which may lead to their complete fibrosis and often occlusion; or the endarteritic and sclerotic changes may start simultaneously. There appear to be several varieties of endarteritis; in one form the endarteritis is regular and consists of a delicate fibrous and cellular tissue closely resembling that met with in syphilis (Ewald, myself and others, *see* Fig. 46); at other times there is a hyaline change in the intima which may be regularly or irregularly distributed (Thoma, Leyden, &c.); or the lumen of a vessel is rendered triangular by a coarser fibroid change more akin to that seen in atheroma (myself, *see* Fig. 87). The endarteritis may affect some vessels more than others, and the areas of the more endarteritic vessels are then more fibroid than other parts and more glomeruli are hyaline. The endarteritis may be part of the arterio-capillary fibrosis discussed on p. 219. Thus the endarteritis may be brought about by local causes acting in the kidney or by general causes producing wide-spread fibroses. The vessels may be the seat of lardaceous degeneration. Thoma (V. A., 71) describes and figures sections of injected fibroid kidneys. In these numerous interesting points are brought out. For instance how endarteritic changes in the capillaries of the glomeruli bring about occlusion of their lumina, and how in very many cases there is a new formation of vessels which spring from the root of the glomerulus (afferent arteriole). The glomeruli including the capsules are early affected, indeed

one might almost say they are the most sensitive points in the kidney. Comparing the glomeruli in **Figs. 30, 79, 97, 98, 99** and **103,** a very good idea of the wide range of changes is obtained. An early alteration is proliferation of the nuclei of the glomerulus and the slight increase in size (Fig. 79, 1); later this inflammatory overgrowth may be followed by hyaline fibroid transformation, and the glomerulus then shrinks and becomes impervious (Figs. 79 and 97). A primary capillary endarteritis as mentioned above, probably occurs in very many cases. The glomerulus sometimes enlarges and assumes a rosette or radiate form as partly seen in Fig. 98, 1; this change seems to be due to an overgrowth of the covering endothelium. Amyloid degeneration of the capillaries of the glomerulus is described under **Fig. 30.** The capsules may or may not participate in the glomerular changes, or they alone may be affected. The peculiar hyaline change, similar to that noted in the glomerulus, is frequent and in some cases appears to be preceded by cellular overgrowth (*see* Fig. 99, 1); in some cases of pronounced endarteritis the hyaline transformation is most complete and striking. Of great interest is the hyperplasia of the endothelium lining the capsule; proliferation early occurs in most glomerulo-nephrites, but especially in the scarlatinal, and subsequently may lead to such an extreme growth as that represented in **Fig. 98,** 2; this hyperplasia has been described under the head of commencing malignant disease. Cystic dilatation of the capsule has been referred to many times; although the most pronounced dilatation occurs in fibroid kidneys and is very common, yet the fact must not be overlooked that in many early nephrites it is also of frequent occurrence (*see* Figs. 78

and 103). In many cases the remains of the glomerulus can be recognised in the distended capsule. Thoma describes the formation of a vascular network surrounding the cysts and taking its origin from the afferent arteriole. The immediate causes of the changes in the glomeruli appear to be several. The most marked cases of hyaline change are associated with endarteritis and it is probable that in these cases the endarteritis commences first in the capillaries themselves, and that as in the case of the larger vessels the change is associated with either local or general causes. In syphilis we have already noted the presence of endarteritis of the vessels without fibroid changes in the glomeruli, and the atrophied and hyaline glomeruli in Figs. 96 and 97 are not accompanied by endarteritis in the vessels. The atrophy of the glomerulus seems in many cases to entail atrophy of the tube corresponding to it.

Condition of the *renal epithelium*. Parenchymatous changes are always present in the fibroid kidney. Atrophy, necrosis or disappearance of a large proportion of the tubes is common in the small advanced fibroid kidneys. Dilatation is extremely frequent and characteristic, Figs. 30, 79, 96, 99; the tubes are then usually lined by a flattened or cubical epithelium (Fig. 79, 2); there may be all stages of dilatation up to large cysts, and sometimes they are arranged in "corkscrew-like rows." Occasionally the epithelial cells are large, granular or may contain oil globules. Proliferative changes are very frequent in the small vascular (gouty) and large fibroid kidneys; they are especially prone to make their appearance early in the straight tubules; small localised hyperplasias of an acinous or cystic and

papillomatous type are not uncommon. In the collecting tubules, in a case of fibroid and albuminoid degeneration, I have noted marked stratification and commencing papillomatous change in the epithelium. *Casts* in the tubules but not in the urine are very common, they are usually hyaline. Hyaline or colloid masses are frequent in the cystic tubules. *Deposits* of calcareous, uratic and other salts and substances are not infrequently met with (*see* Degeneration).

The following are some of the forms assumed by fibroid kidneys :—

1. Small pale granular kidney. Of the type of Fig. 96. The granules are regular, the cortex is atrophied and there may or may not be endarteritis. It is derived apparently in many cases from the "large white kidney" described below.

2. Large pale granular (Greenfield, "Atlas of Pathology," plate iii., fig. 8), an earlier stage of the preceding.

3. Small red fibroid kidneys. Smooth, irregularly granular or with depressions; capsule much thickened and adherent. To this category belong in many instances the *arterio-sclerotic*, *gouty*, *lead*, and *alcoholic* kidneys. Endarteritis is marked; there is a new formation of vessels and frequently congestion and dilatation of these as well as of the old vessels; cystic and proliferative changes are common, and there may be deposits of calcareous or uratic salts. The changes may result from an acute glomerulo-nephritis, or be more directly dependent on the endarteritic changes; and in hastening the endarteritic changes, not only in the kidney, but in the other organs of the body (but perhaps not in such a marked manner), the gout, lead, and perhaps the alcohol exercise their influence.

4. Large red or pale fibroid kidneys (large red granular, Greenfield) are described, and a normal sized or large white fibroid kidney with or without albuminoid disease is not uncommon. In the *large white albuminoid* kidney (**Fig. 30**), there is connective tissue overgrowth, although the changes in the parenchyma are also very striking and consist in dilatation of the tubes with cubical lining, or granular and fatty degeneration; the glomeruli or perhaps more often the vasa recta are the seat of lardaceous change. Hyaline casts are as a rule numerous.

Parenchymatous Nephritis.—Examples of this type are found in the *large white* (soft) kidney and in the much rarer fatty kidney. The most striking changes occur in the parenchyma, and are exemplified in **Fig. 103**. The tubules and many of the capsules are *dilated;* the lining epithelium usually shows signs of disintegration and is detached from the walls with characteristic ease. In the post-mortem room many of these kidneys, owing to their colour, are pronounced to be fatty; examination with osmic acid, however, usually fails to detect this rare condition. There is always some increase and change in the connective tissue as in the figure. Attention is directed to the dilated condition of the tubes and glomeruli as evidence of some impediment to the outflow of urine.

Pigmentary and Crystalline Formations.—In the chapter on Degeneration, the occurrence in the kidney of blood, bile, urates, cystin, lime and silver salts, has been referred to.

Tubercle of the Kidney.—The tubercles occur either in the miliary form and as part of a general tuberculosis,

or as large caseating, mortar-like or suppurating foci, primary in the kidney or spreading from the lower urinary tract. In tubercular pyelitis ulceration of the pelvis occurs, which may scollop out the kidney very extensively. If at the same time, owing to the tubercular swelling of the mucous membrane of the ureter, the latter becomes blocked, *pyonephrosis* results.

The kidney is a frequent seat of parasitic affections, both fungoid and animal, some of which in the lesions which they excite closely resemble both the miliary and crude forms of tubercle.

Tumours of the Kidney.—Tumours of the kidney (primary) especially the larger ones appear very frequently in fœtal life or in early childhood. In addition to the remarkable cystic tumours described on p. 186, there are two very important classes, the *adeno-* and *myo-sarcomata*. These tumours may appear in one or both kidneys, and in a multiple form in either. The adeno-sarcomata, adeno-carcinomata, or congenital adenomata, as they are variously termed, consist either of solid epithelial acini, or of tubes, papillomatous cystic formations, and so-called pseudo-glomeruli, thus more closely resembling kidney tissue. The myo-sarcomata consist of a small round or spindle celled stroma and of striated muscle fibres of various shapes and degrees of striation ; both glandular acini and fat cells are in addition very frequently found. Cartilage islets have been recorded in a sarcoma consisting of spindle and other cells. Metastasis of the myo-sarcoma may occur, and in one case both kidneys being the seat of tumours, a third adjacent but independent mass was found. Ribbert has described very interesting striated myo-sarcomatous polypi in the pelvis and ureter, and

has thus raised the question of the ætiology of these tumours.* Complex angiosarcomata and nævoid tumours have been frequently described in the kidney.

Attention has already been directed to the glandular hyperplasias which may occur, both in the cortex and pyramids, in chronic inflammatory conditions in the kidney. In the cortex the growths which are usually small white nodules and frequently multiple, may form intracystic papillomatous or solid glandular growths. Some, however, of these epithelial tumours may have a much earlier origin being allied to the congenital glandular tumours. On many occasions in the chapters on Tumours, the presence of aberrant suprarenals in the kidney and elsewhere, was referred to. They are undoubtedly common in the kidney, in the cortex of which they form small wedge- or lens-shaped white or yellow nodules. They are surrounded by a distinct fibrous capsule, and this serves to differentiate them from infarcts. They have been mistaken for gummata and lipomata (p. 145), some of the so-called "false lipomata" (*i.e.*, suprarenal rests) reaching a very large size. They are prone to fatty degeneration, the fat being in the form of globules or crystals; it is likewise probable that they may undergo cystic and atrophic fibroid changes, just as in the case of the suprarenal bodies themselves. In the pyramids small fibrous and hyaline tumours are described. (For the diffuse infiltrating, miliary and nodose forms of lymphatic growths, *see* Chapter XII.).

* By supposing that they spring from the unstriated muscle fibres of the pelvis, and not as Cohnheim supposed caused by a "vitium primæ formationis" of the kidney, by the cutting off of adjacent muscle tissue. (*See* myosarcomata of vagina and uterus).

Pelvis, Ureter and Bladder.—Reference has been made to simple and tubercular pyelitis, and on p. 158 to epithelial hyperplasia. Papillomatous growths in the pelvis and ureter are described, also cases of numerous small cysts in what appeared to be the upper portion of the ureters. In the bladder *cystitis* is a frequent affection; it may be of the catarrhal type with hyperplasia of the lining epithelium, or possess a diphtheritic or ulcerative character; vesiculation sometimes occurs. Under **Fig. 61** one of the most frequent tumours of the bladder—the papilloma—has been described. These tumours may be single or multiple and are very often seated at the orifices of the ureters or urethra, or in the neighbourhood of a stone. The papillæ may be long as in the figure, or the tumour may form a low "cropped" or velvety growth. The presence of villi in the urine must not be taken as indicating that there is only a simple growth in the bladder, for frequently the villous tumour is associated with an *epithelioma*—the common malignant tumour of the bladder. A fibro-myoma of the prostate may form a projecting tumour into the bladder. On p. 205 the causes of pilimiction were mentioned. An epithelioma with horny nests has been described by Godlee, rhabdomyomata by Cattani and Vincenzi, and a myocarcinoma by Virchow.

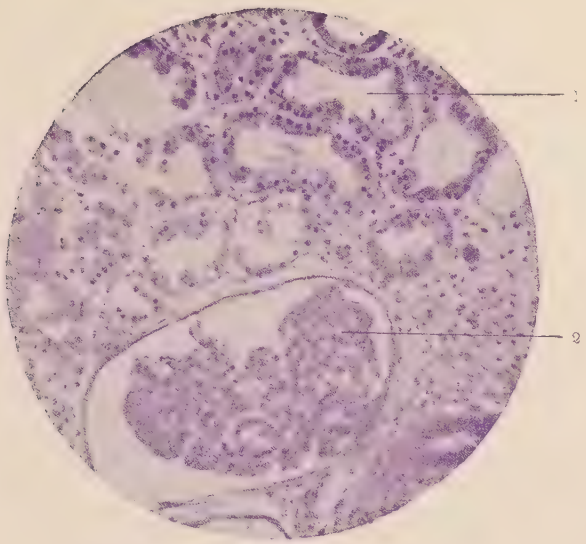

Fig. 103. PARENCHYMATOUS NEPHRITIS

1. Degenerated and dilated tubule.
2. Glomerulus, the capsule is much distended and the glomerulus degenerated.

Obj. ⅓ in., without eyepiece. (Logwood)

Fig. 104. CIRRHOSIS OF LIVER.

1. Subscapular and interlobular connective tissue overgrowth.
2 & 3. Hepatic lobules in various stages of atrophy

Obj. 1 in. (Logwood).

Chapter XV.

LIVER, PANCREAS AND PERITONEUM.

Liver.

Parenchymatous Changes.—The anatomical changes to which the liver cells are subject are numerous and in many cases very striking. They include :—

(*a.*) *Hypertrophy* and *proliferation.*—These changes have been observed in diabetes, in compensatory hypertrophies when portion of a liver has become naturally atrophied, or when large portions have been extirpated, and in certain cirrhoses.

(*b.*) *Atrophy*, a frequent and striking change due to pressure of tumours (p. 177), fibroid overgrowth (**Figs. 45** and **104**), lardaceous infiltration, blood pressure in the "nutmeg liver" (**Figs. 105** and **106**), and as part of a general atrophy of the liver as in acute yellow atrophy.

(*c.*) *Fatty Changes.*—These are of all conditions the most frequent, being present in almost every variety of diseased liver. **Fig. 29** illustrates a very common appearance (p. 78) ; from this there are all stages to the extreme fatty degeneration observed in the liver in phosphorus poisoning, where portions may "burn like the wick of a candle." Over-feeding, exposure to high temperatures, pyrexia, cachexia, cirrhoses, presence of tumours, administration of phosphorus and other bases and alcohol, are some of the more prominent causes. Various conditions appear to lead to a curious disseminated fatty degeneration.

(*d.*) *Granular degeneration, cloudy swelling* (often ex-

treme) and *vacuolation* are observed in the acute specifics, especially of the severe infective types, in acute yellow atrophy, in phosphorus and arsenic poisoning.*

(*e.*) *Pigmentation.*—Obstruction of the bile duct is usually followed by an intense diffuse pigmentation of the liver tissue, the hepatic cells containing fine yellow or brown granules. Popoff described a very fine injection of the ramifications of the bile ducts after ligature of the common duct; and in a case of obstruction of the duct by a tumour I have observed the ducts filled with green pigment, whilst the hepatic cells contained yellow granules. The bile pigment may be crystalline (*see* p. 90).

Blood pigments, especially the iron derivatives of the same, are observed under numerous circumstances, viz., in pernicious anæmia (p. 89, **Fig. 33**), leucocythæmia, prolonged fevers, malaria, tumours, and in congestion of the liver. The administration of iron (Quincke, Nasse, Bistrow) seems to cause a not very marked accumulation of iron in the liver cells. Iron pigmentation is also observed in cases of absorption of extravasated blood and in purpura. The pigment granules are of various shades, colourless (Quincke), brown or black; they occur in the liver cells, Kupffer's star cells and in the connective tissue;† the distribution is most fre-

* Under the title *bacterial necrosis of the liver*, Hamilton, Eberth, Schütz and others describe a curious necrosis of areas of hepatic tissue, in which the outlines of the cells are retained and there is no suppuration; micro-organisms are present.

† In sections of a liver of a case of melanæmia the very abundant black pigment was not in the liver cells but free in cells in the capillaries (compare the "golden corpuscles" of the nutmeg liver).

quently periportal. In argyria, the black silver salt may pick out the walls of the hepatic veins and of some of the smaller portal vessels (Frommann). Hanot and Schachmann describe several cases of marked pigmentary cirrhosis accompanying diabetes, the granules were brown and the cells showed marked signs of degeneration. Lastly attention may be called to the apparent fact that primary melanotic tumours of the liver are not very rare.

Lardaceous degeneration of the vessels is described on p. 84, **Fig. 31.** As in the kidney so in the liver, this change may be associated with either parenchymatous or cirrhotic changes. It may be met with in the scar tissue of syphilitic lesions.

CIRRHOSIS OR INTERSTITIAL HEPATITIS.—There are several varieties of cirrhosis, chief of which are the atrophic, hypertrophic, congestive, and the cirrhosis of so-called "acute" and "subacute red" atrophy. The changes encountered in the first three will be described forthwith and afterwards the results of numerous experiments on the liver will be given with a view of helping to elucidate the causes of the cirrhotic and parenchymatous changes.

Since Charcot's researches on the liver, it has been held by a great many that a *hypertrophic* cirrhosis accompanied by jaundice, but without ascites, should be separated from the long recognised *atrophic*, *granular* or *hobnailed* form, which, commonly associated with excess in *alcohol*, has for chief symptom ascites. The former was considered by Charcot to be a *biliary* cirrhosis, the latter a *portal*. But though we agree with Charcot that cirrhosis may be provoked from the bile ducts or from the portal vessels respectively, yet it cannot be said

that sharp clinical or anatomical lines exist between the two forms.

Atrophic cirrhosis (annular, multilobular and extralobular) is very frequently associated with drink and hence the names drunkards' or gin drinkers' liver. It may, however, occur in the strictly temperate and in young children (in some of these cases there has been a history of alcohol). The surface aspect is well described by the term hob-nailed, for the granulations are large, being formed of one or more hepatic lobules circumscribed by dense connective tissue. A slightly magnified section is well represented in **Fig. 104.** Dense connective tissue overgrowth everywhere follows the ramifications of the portal canals; larger bands surround groups of lobules, whilst smaller ones isolate individual ones (multilobular, annular, monolobular); the fibroid process may here and there even penetrate between the cells. The lobules are atrophied, Fig. 104, 2 and 3, and the cells at the periphery especially so, where in addition a large number have completely disappeared. Fatty and pigmentary changes are present. The connective tissue as represented in the figure is dense and not very corpuscular, the majority of the portal and many of the hepatic vessels are obliterated, a few bile ducts are scattered about and are distinguished as double rows of deeply staining nucleated cells. Examining and comparing other preparations it will be found that the appearances vary slightly. There is usually at the spreading edge of the fibroid overgrowth the usual small round celled infiltration, in the proliferative changes of which many of the hepatic cells share (whilst others atrophy); the bile ducts appear often

increased in number and they are certainly changed in appearance, many are the seat of marked proliferation; the portal vessels and the hepatic arteries and sometimes the veins become gradually involved in, and obliterated by connective tissue, at the same time there is a new formation of vessels and dilatation of others. Injection through the portal vein with difficulty reaches the hepatic vein. The result of this obstruction is very frequently dilatation of collateral vessels, increase in size of the spleen, ascites and intestinal hæmorrhage. In the earlier stages of atrophic cirrhosis the liver is enlarged and there is a small round celled infiltration around the portal vessels.

Hypertrophic cirrhosis (insular, monolobular and both extra and intralobular). In a typical example the liver in spite of extensive cirrhosis is not contracted and is frequently larger than normal. The cirrhosis spreads or radiates out from the tissue of the portal canals and does not tend to assume the lobule encircling form (annular) of the atrophic variety. The fibroid process penetrates into the lobules; the liver cells are usually the seat of pronounced fatty degeneration and the lobules may thereby be considerably increased in size; at the periphery destruction and atrophy of the liver cells may be observed and occasionally what by some is regarded as characteristic, viz., a tendency of the atrophied peripheral cells to arrange themselves into duct-like columns. The fibrous tissue does not usually possess the dense character of the atrophic form, and it has been compared to an elephantiasis of connective tissue; there is not such complete obstruction of the portal vessels, injection readily reaching the hepatic veins; in advanced cases, however, very many of the

vessels are obliterated and a cavernous nævoid dilatation and new formation of portal and hepatic venules and capillaries is frequently seen in the wide bands of connective tissue. What, however, has been most insisted upon is a new formation of bile ducts, more marked than in the atrophic variety. The number of these seems to depend greatly upon the density of the connective tissue, thus in loose vascular and corpuscular tissue like that met with in hypertrophic cirrhosis, and in the earlier hypertrophied forms of atrophic cirrhosis, and even as we shall see in many forms of the so-called acute yellow atrophy, the amount of duct-like tissue is increased; whilst in contracted forms the ducts become atrophied and many disappear. Numerous views have been held as regards their origin, we consider them as modified from the pre-existing hepatic and duct tissue. Apart from the abundance of bile ducts, proliferation of the duct cells takes place, as in the other forms of cirrhosis, and leads to glandular accumulation of cells and often to adeno-papillomatous and cystic formations.*

A fibrosis spreading from thickened hepatic veins has been observed in some cases (Sabourin). And in very chronic cases of obstruction to the venous outflow from the liver (in cardiac and pulmonary diseases) a gradual infiltrating *pericellular* fibrosis may proceed from the hepatic veins and capillaries; the latter are greatly dilated, and on section the liver has a red congested appearance; it is tough, enlarged and heavy or small

* It will have been observed how often atrophic and destructive changes of the large secreting gland cells is accompanied by persistence and even proliferative changes in the duct cells (compare especially kidney). There is a marked difference of resistence.

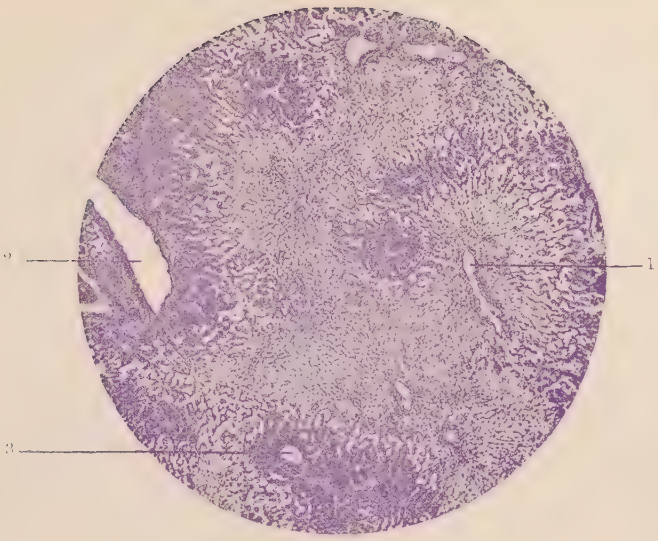

Fig. 105. CONGESTED LIVER

(Nutmeg liver).

1. Hepatic vein and surrounding congestion (the lighter stained tissue)
2 & 3 Sections of portal vessels and remains of hepatic parenchyma around (darkly stained portion)

Obj. 1 in. Logwood

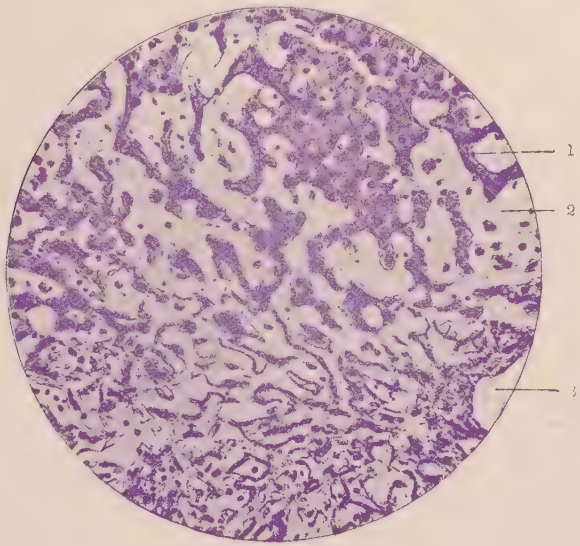

Fig. 106 CONGESTED LIVER

(More highly magnified).

1. Atrophying liver cells, in some places reduced to shreds
2. Widely dilated capillaries.
3. Hepatic vein

Obj. ¼ in. Logwood

(red atrophy) and is a fibroid form of the "nutmeg liver" represented in Figs. 105 and 106 and which more commonly follows cardiac obstruction.

The "*nutmeg liver*," *cyanotic atrophy*. In this form the increased pressure in the hepatic vein leads to dilatation of its branches and capillaries throughout the liver. A sponge-work of dilated capillaries is formed in the centre of the lobules, which fusing form wider areas; the deep red mottling which this produces contrasts in the recent state with the lighter tinted peripheral portions of the hepatic lobules and the appearance of a nutmeg in section is accurately simulated. This is well seen in **Fig. 105,** but the colours are reversed, for in logwood-treated sections the hepatic cells are stained darkly, whilst the blood remains colourless. In **Fig. 106** the changes wrought by the engorged capillaries are illustrated. (1) is the central hepatic vein, surrounded by a meshwork of enormously distended capillaries (2). Around the vein the liver cells have completely disappeared, further away they are represented by compressed trabeculæ and even at the periphery the cells are considerably atrophied; they are in addition fatty and pigmented. In the distended capillaries there are numerous golden pigmented corpuscles. There is no fibroid overgrowth, but as mentioned above this may occur; the capsule may greatly thicken. Pulsation during life is often a marked phenomenon.

Ligature of the hepatic artery, *i.e.*, the nutrient artery of the liver which supplies Glisson's capsule and the vasa of the portal and hepatic veins, is not in the larger animals followed by necrosis. This is due to the abundance of collateral arteries; but where as in the rabbit they are not so numerous, typical

necrosis may be produced (Cohnheim and Litten). Infarction as mentioned in a previous chapter is difficult to produce and can only be brought about under special circumstances (experiments of Wooldridge, Rattone and Mondino).

Occlusion of the portal vein slowly brought about, experimentally or naturally, seems to have little effect. Osler examined an interesting case in which the portal must have been long obstructed, yet there was no fibrous overgrowth nor ascites ; the liver was shrunken, the spleen enlarged, collateral veins dilated and there was hæmatemesis. Goodhart* in summing up the large experience of 13 cases of portal obstruction, says there is little evidence of cirrhosis and that if any symptoms at all exist they are ascites, intestinal hæmorrhage, extreme congestion and inflammation of some part of the small intestine or colon, or enlargement of the spleen. In one of his cases the liver was traversed by large fibrous bands and was in consequence *lobulated*, but there was no minute fibrosis. Some observers, however, describe cirrhosis (S. West, Litten) and it has been recorded after slow experimental thrombosis (Solowieff). The evidence on the whole shows that occlusion pure and simple of the portal vein is not followed by widespread cirrhosis. Rapid occlusion may cause cloudy swelling and necrosis, embolism of the portal branches, little effect. In some forms of syphilitic livers a most pronounced overgrowth of the intima of the portal veins and hepatic arteries, often leading to complete occlusion, may be seen ; the result in a case which I observed was local and limited

* Goodhart. "Pathology of Liver" in Sydenham Society's *Atlas of Pathology*.

to a fibrous overgrowth. Attention is not often called to occlusion of the branches of the hepatic vein; Sabourin, as already mentioned, has described a fatty hypertrophic cirrhosis unattended by jaundice or ascites, in which the veins were remarkably thickened and in some cases blocked, and from which a cirrhosis extended.

Obstruction of the Bile Ducts.—Partial or complete obliteration of the main duct or of a branch is frequent. Congenital obstruction seems often to occur in syphilitic infants (Goodhart, Lomer) and therefore the changes found must not wholly be attributed to the occlusion of the duct. The changes observed include atrophy of the liver, although hypertrophy is occasionally found; formation of cysts (usually filled with mucus); fibroid changes, the liver being described sometimes as cartilaginous or leather-like; shrivelling with no marked cirrhosis. Goodhart goes against the view that general cirrhosis follows obstruction of the bile duct and mentions a case in which a child which lived seven months with an occluded duct showed no cirrhosis. It is rare to find obstruction from tumours and gall-stones in later life giving rise to a fibrosis comparable to those described in the commencement of this chapter. When a large division only of the bile duct has been occluded, the region drained by it has been found cystic, fibroid and atrophied—the remainder of the liver frequently hypertrophied. Raynaud and Sabourin mention a very instructive case of obstruction; the large, many of the smaller ducts and Luschka's glands were dilated, the former enormously; there was an overgrowth of hyaline fibroid tissue around the ducts, which involved the

portal and hepatic vessels and ramified in bands over the liver; there was thus a lobulated cirrhosis but no perilobular or interstitial change and the liver substance appeared only to suffer from the compression effects of the cystic ducts.

Ligature of the bile duct has been performed on a very large scale but the results are somewhat conflicting. Charcot and Gombault in well known experiments obtained a rapid pericanalicular cirrhosis, apparent increase and dilatation of the bile ducts and hypertrophy of the liver. It was from these experiments that they concluded that hypertrophic cirrhosis was of biliary origin. But it is evident just as in the case of their kidney experiments, p. 264, that micro-organisms were present, so that part of the connective tissue and biliary proliferative changes might have been of the nature of an inflammatory reaction excited by the microbes. Other observers (Blauvelt, Litten, &c.) have either obtained negative results or only slight fibrosis, when working antiseptically. Litten produced a cirrhosis by the application of croton oil to the duct without ligature. Other observers again incline to Charcot's view having induced a more considerable connective tissue overgrowth.* In addition to the fibroid changes, parenchymatous degeneration, diffuse or local, is described in many of the cases. As causes of the above cirrhosis are given the mechanical effects of the pressure of the dilated ducts, but more especially the irritation of the retained secretion; this latter factor, however, cannot be very potent as the bile rapidly tends

* Amongst additional observers on the effects of ligature of the duct, may be mentioned Wyss, Leyden, Mayer, Wickham Legg, Brieger, Foa and Salvioli, Beloussow, Cohnheim.

to disappear from ducts occluded naturally or experimentally; and all experience tends to show that the pressure of dilated ducts simply produces atrophy and destruction of the cells immediately around them, the place of which is then filled by connective tissue, and that there is no general fibroid overgrowth. In view of the evidence, however, it cannot be denied that cirrhosis is produced by ligature of the bile duct.*

There is no uncertainty about the cirrhosis which is produced when *in addition* to obstruction of the bile ducts there is an active irritant in them. Examples are furnished by the ZOOPARASITICAL CIRRHOSES. The parasites to which particular attention in this respect have been directed are Psorosperms (Nicati and Richaud), Distoma campanulatum in dog (Zwaardemaker), other Distoma in sheep and oxen (Virchow, producing a choleporitis with periporitis); I have myself observed marked cases in Flemish sheep. The effects produced may be thus summed up. The livers are usually enlarged and ascites may be present. The cirrhosis is well marked, insular and radiating, or more typically perilobular and starting around the bile ducts. The connective tissue is very cellular, both diffuse and focal collections of small round cells being abundant; the vessels become involved and obliterated by the overgrowth. The bile ducts appear increased in number, many are dilated and there is epithelial proliferation; in some places adeno-papillomatous and cystic

* *Icterus neonatorum*.—Birch Hirschfeld attributed the jaundice to œdematous swelling of the connective tissue of Glisson's capsule and consequent pressure on the bile ducts. In this disease a bilirubin infarct in the kidney may be observed.

growths are formed; Luschka's glands may show similar changes and many of the liver cells may share largely in the proliferative processes.

In the *portal vessels* Distoma hæmatobium (Bilharz) may excite a periportal cirrhosis (Kartulis) and Echinococci whether present in the vessels or lymphatics may also give rise to widespread cirrhosis.

The results of the administration of certain TOXIC AGENTS are interesting. *Alcohol* has naturally been largely used with a view of elucidating the share it may take in producing the familiar "alcoholic cirrhosis." Kahlden, one of the latest observers, was unable after the prolonged administration of the drug to observe any cirrhosis; fatty degeneration of the liver cells and of Kupffer's star cells were the noticeable alterations. Straus and Blocq even after one year obtained only slight connective tissue overgrowth, so likewise Dujardin, Beaumetz and Aucigé and Afanassijew. The chief changes which *phosphorus* produces are *parenchymatous*, and include cloudy swelling, fatty, granular and necrotic changes and vacuolation. Wegner (V. A., 55) has figured a perfect example of a granular cirrhosis, but no observer since seems to have obtained such a striking result, although new formation of bile ducts and interstitial overgrowth and small round celled infiltration is mentioned (Krönig, Aufrecht, Ackermann, Ziegler and Obolensky). It is really very doubtful therefore whether either alcohol or phosphorus, *per se*, can excite an extensive cirrhosis; and it must not be forgotten that the administration by the mouth of drugs like these to the lower animals excites intestinal inflammatory changes, which may not perhaps be without effect on the liver. To this little examined point atten-

tion will be directed further on under the changes observed in the liver in cases of intestinal inflammation and peritonitis.

In man the liver in *phosphorus poisoning* is usually large, lemon yellow or of a pale ochrey tint. There is extreme parenchymatous degeneration, the liver cells being represented by oil globules and a network of protoplasm; a large number of the nuclei may disappear; there is usually some small round celled infiltration in the portal canals, and there is evidence to show that this as well as some connective tissue overgrowth may be still more marked in chronic cases. It has been maintained that both the liver, with the intense parenchymatous changes, as well as that showing fibroid overgrowth is similar to the livers of "acute yellow atrophy" in which both a parenchymatous and an interstitial form may occur. Most evidence, however, seems to show that this is not the case at least for the second form.

"Acute Yellow Atrophy."—This is a curious atrophic condition of the liver which is usually associated with jaundice and coma. The name, however, is not accurate for in a large number of cases the majority of the liver tissue has a red colour and the process is not acute. The term *red atrophy* has been given to it; but this term has now been used too loosely to be applicable. As above mentioned it appears possible to distinguish two types. In one there is a profound degeneration of the liver cells without marked interstitial changes; the cells may be smaller than normal, finely granular or net-like and may contain numerous minute oil globules, the nuclei may not stain. In the other variety, which is the one usually figured, there is

a very abundant small round celled infiltration and connective tissue overgrowth side by side with areas of liver parenchyma in various stages of degeneration. To the former is due the red colour, to the latter the yellow. The yellow or golden areas may be mere specks or they may constitute a large proportion of the liver and on section stand out prominently from the red tissue; the hepatic cells of which they are composed may be swollen, atrophied, fatty or in process of proliferation, a large number disappear and are represented by pigment; there may be some pericellular fibrosis. The red tissue may be compared to very vascular and cellular granulation tissue; in it the liver cells have for the most part disappeared and are represented by detritus and pigment. The portal canals are the seat of an abundant small round celled growth and the fibrotic process appears to start here. The large vessels tend to become occluded, new ones are formed and the capillaries generally are distended with blood. The bile ducts are very often dilated, may even show an increase in number and their epithelium may here and there be in process of active proliferation. It will be thus gathered that the red tissue is the seat of active progressive changes and that it tends to replace the yellow parenchyma. Goodhart states that "acute yellow atrophy" may appear in an already fibroid liver or that the process may be limited to one portion. Leucin, tyrosin, fat crystals, but especially *micro-organisms* are described as often present. The presence of microbes has suggested a mycotic origin, and this is in some cases supported by the occurrence of atrophy in septic infective diseases. The likeness of many of the changes to those encountered in some forms of surgical

kidney (diffuse interstitial), is perhaps worthy of note.*

CIRRHOTIC AND OTHER CHANGES OBSERVED IN THE LIVER IN CASES OF PERITONITIS AND INFLAMMATION OF THE ALIMENTARY TRACT.—Goodhart, Sabourin and Brieger have recorded cases of marked cirrhosis in tubercular peritonitis. Handford has described interstitial hepatitis in enteric fever and lays stress upon interstitial changes in inflammation of the alimentary canal. It is a long known observation that suppurative inflammation of the alimentary tract is very often accompanied by *abscess formation in the liver.* The abscesses are especially common in dysentery; they may be small and numerous or large and in chronic cases they may lead to spreading fibroid changes in the liver. The suppuration is most probably of mycotic origin and due to metastasis from the intestine. Not only, however, do micro-organisms reach the liver from the intestine by the vessels, bile duct and lymphatics, but the ova and larvæ of the animal parasites appear to find their way to the liver by the same means; thus *Echinococcus multilocularis* has been described forming chains in the capsule of the liver (in the lymphatics probably) and in the lymphatic glands at the portal fissure. From the foregoing account it may therefore be assumed with some probability that inflammation of the intestines and peritoneum may react on the liver through the medium of the lymphatic and vascular systems.

* Amongst the general tissue changes often associated with acute atrophy may be mentioned, *acute desquamative nephritis*; extreme *fatty degeneration of cardiac* and perhaps other muscles, *hæmorrhages.*

PERIHEPATITIS.—Localised thickening of the capsule with fibrous extension into the liver substance may be produced by mechanical pressure. Where the capsule is uniformly thickened, the increase may be due to hyperplasia of the serous reflection or of Glisson's capsules, or of both. The thickening has been described forming an almost rigid tunic to the liver. In the thickened capsule nævoid and adenomatous growths may sometimes be encountered.

SYPHILITIC CIRRHOSIS, TUBERCULAR DISEASE, CHANGES IN THE ACUTE INFECTIVE DISEASES AND IN CACHEXIAS, IN RICKETS, DIABETES AND ECLAMPSIA.

Syphilitic cirrhosis has been described on pp. 122, 123 and 124, and illustrated by **Figs. 42-45.** A *pericellular* cirrhosis is especially obvious in Fig. 45. Attention has already been called (p. 288) to the marked overgrowth of the intima of the portal veins and hepatic arteries in some cases. Increase and dilatation of the bile ducts may also be observed. In *Rickets* a very definite hyperplasia and small round celled infiltration of the perilobular tissue has been described in the usually enlarged livers. In *Diabetes* hyperplasia and hypertrophy of the liver cells, increased glycogen, fibrosis and pigmentation are amongst some of the changes observed in different cases. In cachectic and senile states, parenchymatous degeneration and some interstitial change are common. In the *acute specifics* (scarlet fever, Klein), cloudy swelling, fatty degeneration and acute interstitial changes may be encountered. In *eclampsia* extensive hyaline thrombosis of the portal vessels and areas of hæmorrhagic and anæmic necrosis are described (Schmorl). In *tuberculosis* of the liver both the miliary or crude forms occur.

DISEASES OF THE GALL BLADDER AND BILE DUCTS AND TUMOURS OF THE LIVER.

Ulcerative and catarrhal conditions of the gall bladder and bile ducts are frequently occasioned by the presence of stones and parasites. As a result of cholelithiasis the wall of the gall bladder may become thinned or the muscular coat hypertrophied. Of more importance are the warty, polypoid, villous and cancerous conditions of the neck of the gall bladder and large ducts, which in the great majority of cases are associated with the presence of stones.* We have already noted cystic and proliferative changes in Luschka's glands and adeno-papillomatous and cystic conditions of the larger ducts in the case of animal parasites, or indeed in chronic fibroid processes generally. Apart from chronic imflammatory hyperplasia an acinous and duct-like growth may occupy the place of the smaller bile ducts; or a more atypical scirrhus-like growth may extend along the portal canals and be accompanied by extensive dense fibroid overgrowth and contraction. A malignant growth of a scirrhoid or encephaloid type may start from the neck of the gall bladder, infiltrate the surrounding tissue and give rise to numerous secondary growths throughout the liver; many of the large vessels may become blocked or their lumina occupied by the malignant polypi. Several varieties of primary tumours occur in the liver parenchyma without our being able to trace them to bile ducts. Many of them appear to be congenital, though they do not often reach a large size; they are very frequently multiple and encapsuled.

* Wilks and Moxon described what are probably *congenital* myxomyomatous growths in the common bile duct of a child.

Detached portions of liver tissue (*hepatic rests*), often very numerous, are not infrequently encountered in the peritoneal folds supporting the liver and in the portal fissure (Gruber, Wagner and others); they may be a possible source of cysts and tumours. In the liver itself multiple hyperplastic tumours have been observed consisting of what appeared to be encapsuled groups of liver cells (Friedreich and other observers since). As attention has been drawn to the presence of a *supra-renal rest* embedded in the under surface of the liver, it is possible that similar tumours may have been mistaken for adenomata in some cases (compare kidney). Small fibro-adenomata consisting of cylinders lined by cubical epithelium and embedded in fibrous tissue occur, and occasionally larger adenomatous formations; some may give rise to secondary growths (malignant adenomata). The acini may be solid and scirrhus-like, or they may consist of large cells and resemble the acini of the pancreas. Pigmented glandular epitheliomata are described. A peculiar myxomatous softening is not unrarely observed both in connection with primary and secondary growths.

Bollinger describes an interesting case of what he regards as an endophlebitis of the portal vessels in the horse, in which the intima was the seat of a *papillomatous formation*. He observed a similar condition in his endarteritis verminosa in horses.

Cavernous and angio-sarcomatous tumours are of very frequent occurrence (pp. 131 and 169).

Pancreas.

The pancreas may be the seat of *parenchymatous* changes, of which *fatty necrosis* and *atrophy* are important; the place of the atrophied cells is usually filled by fatty and fibrous tissue.

Acute and *chronic interstitial* changes may be secondary to inflammatory changes in the peritoneum, bile duct, or to concretions in the pancreatic ducts. In acute pancreatitis hæmorrhages and suppuration may be observed, as well as necrosis of the surrounding fatty tissue. In chronic pancreatitis cirrhosis is in some cases very marked and may be associated with cystic and adenomatous changes. *Cysts* may be found isolated in the substance of the pancreas; more frequently, however, the ducts are the seat of cystic dilatation (ranulæ) owing to occlusion of the main duct by calculi (calcium phosphate and carbonate) or parasites. *Malignant* tumours of the pancreas are not rare; they are mostly of the *scirrhoid* and encephaloid types; they may arise from the ducts and be associated with concretions. Adjacent organs, as the stomach, intestines, liver, spleen, and semilunar ganglia may be involved by the growth. The pancreatic duct may be occluded and fatty stools result (Bowditch). Blocking of the bile duct (accompanied by jaundice) and of the portal vein also not infrequently happens.

Much interest is attached to the various pathological changes in the pancreas, both on account of their being

often present in cases of *Diabetes* and because extirpation in animals may lead to glycosuria.*

Like so many other organs the pancreas furnishes examples of accessory glands or rests; thus small tumours resembling the pancreas in structure have been found (Klob, Zenker) in the walls of the stomach, duodenum, jejunum (upper part), and even it is stated 54 cm. above the ileo-cæcal valve. They usually lie between the serous and muscular coats, but may appear in the submucosa.

Peritoneum.

Acute peritonitis is very frequently secondary to acute inflammation of the intestines, stomach, genito-urinary organs, pleura, pericardium and other viscera. The inflammation may be dry, serous or purulent, and may lead to the formation of adhesions and bands. The adhesions are caused, as in the case of the pleura and pericardium by union of fibrin-covered surfaces. If the adhesion takes place between the more fixed organs as between the liver and diaphragm, a firm compact union is effected, as in pleurisy, by the formation of new connective tissue and vessels. If the parts are more moveable, as opposed surfaces of intestine or coils of intestine with other viscera, a condition already noted in pericarditis (Chap. II., see also p. 215) is still more exaggerated; the adhesions become drawn out and oftentimes form bands of considerable length. The

* Much depends upon the completeness of the extirpation—a difficult task in the lower animals. Old observations date from Cl. Bernard, recent ones have been made by Minkowsky and Mehring.

bands are covered by a reflection of epithelium and are penetrated by vascular fibrous tissue which are all derived from the peritoneum. Sometimes a loculated, cavernous or even *cystic* condition is produced by the numerous adhesions between the viscera; the spaces are lined by serous epithelium as in similar cases in pleurisy and pericarditis.

Chronic peritonitis may supervene upon the acute, or be caused by tubercular and malignant disease of the peritoneum—*tubercular* and *malignant peritonitis*. It may be associated with a cirrhosis of the liver, or as mentioned in the preceding pages the peritonitis may be limited to the capsule of the liver (perihepatitis) ;* similar localised inflammation may occur around other viscera as the uterus (perimetritis), and the cæcum and vermiform appendix (perityphlitis). As the result of the chronic inflammation the peritoneum becomes the seat of a small round celled infiltration and of proliferation of the connective tissue, vascular and epithelial elements. The serous cells may become cubical (compare pleurisy and pericarditis) or stratified, when they closely resemble in section the epithelium in figure 98. The connective tissue hyperplasia results in scar tissue and the most remarkable effects of chronic peritonitis are produced by its contraction. The intestines may become firmly bound down by a thickened contracted mesentery and constrictions may even occur; the uterus may become bent and displaced by the contraction of its folds. The appearance of the omentum in general chronic peritonitis is very characteristic, it becomes contracted to a thick rigid band consisting

* Or there may be general thickening and induration of the peritoneum with thickening of the capsules of the liver and spleen.

of dense fibrous tissue and atrophying fat cells. In *chronic tubercular peritonitis* the innumerable miliary foci of inflammation lead to an abundant vascular and connective tissue growth; the omentum becomes infiltrated by tubercular tissue and assumes its characteristic shape and bands and adhesions are formed; the mesenteric glands may become infected or the infection may spread to the pleura and pericardium. In *malignant peritonitis*, miliary cancerous foci, or in some cases (colloid) a diffuse cancerous lining, lead to adhesions and contractions and a rigid contracted omentum, consisting of a dense fibrous stroma and of the infiltrating growth.*

Ascites commonly accompanies the peritonitis. In some interesting cases the fluid has been *chylous* and milk-like. In these latter cases there may or may not be a slight amount of pus present. Reichenbach mentions two cases of chylous ascites, in both of which there was lymphadenoid disease, in one case the mesenteric glands being affected. Recently Renvers and Witla have described cases in which the upper portion of the thoracic duct was obstructed, the lower portion varicose; in Renvers' case the liver was cirrhotic, in Witla's there was tubercular peritonitis and a perforation of the duct. Straus records a very interesting case associated with malignant peritonitis and two minute perforations in dilated chyle ducts; there were in addition chylous extravasations beneath the serosa

* In addition to the above forms Pye-Smith has described an œdematous condition of the peritoneum, pleura and pericardium. The injection of tubercular virus into the peritoneum may cause a villous formation, and often the omentum is converted into a solid mass resembling a caseating lymph gland (Fox, ref.).

of the intestines. Quincke had an almost similar case. Filariæ have been mentioned as another cause of chylous ascites. In many cases there is an associated chylous pleurisy.

Tumours of the peritoneum.—The tumours of the peritoneum are in general characterised by their miliary or spreading tendencies and the proneness with which they infect the pleural and pericardial cavities, passing readily, as in the case of micro-organisms, by the lymphatics.

In chronic peritonitis numerous small fibroid papillæ may be found scattered on the peritoneum; they appear to be similar to those often found on the liver and spleen. On p. 168 a few remarks were offered about the primary *endotheliomata* and nothing now remains to be added. *Miliary lymphadenomata* are not rare (p. 230), they probably originate in the lymphoid collections in the peritoneum. Of still more frequent occurrence are the miliary growths secondary to ovarian, gastric, intestinal and other tumours. The growths are usually small, discrete and papillomatous or cauliflower-like; they may, however, be scirrhoid and occasionally the peritoneum becomes lined by a thick coat of colloid cancer.* The omentum is in all cases early affected, infiltrated by the tumours and contracted, or in the case of colloid disease converted into a huge band of the same.† As mentioned on p. 200, *q.v.*, a primary seat cannot always be detected, and an explanation has to be sought for the primary

* According to Hauser, of all tumours of the intestinal tract, the colloid are most liable to infect the peritoneum.

† In cases of ascites due to malignant disease growths may form at the seat of the punctures made to relieve the distension.

scirrhoid and colloid cancers of the omentum and the multiple *cystic* and *dermoid* (p. 204) tumours of omentum and peritoneum. In connection with this subject attention may again be directed to the question of rests, of which undoubted examples have been given in the preceding pages (accessory livers, spleens, suprarenals and ovaries). Under *lipomata* were described the large fatty tumours to which the appendices epiploicæ and the omental fat may give rise; and under congenital formations an explanation of the *retroperitoneal* lipomata and other tumours was offered.

Chapter XVI.

MOUTH, STOMACH AND INTESTINES.

As there is a great similarity between the changes encountered in the various sections of the alimentary canal, they can be conveniently grouped and described together.

Inflammation and Necrosis.—*Stomatitis*, *glossitis*, *pharyngitis*, *gastritis*, *enteritis* (colitis, typhlitis).

Under this heading may be grouped both *simple*, *catarrhal*, *croupous*, *diphtheritic*, *ulcerative*, *gangrenous* and *chronic inflammatory* changes and *necrosis*. In their production local causes, such as micro-organisms and parasites, and the application of irritant substances play an important part; very many of the changes accompany the infective fevers and some appear to be associated with skin lesions.

The severer forms of *stomatitis* may be accompanied by the formation of *vesicles* or *pustules*, or by superficial or deep destruction of tissue and coagulation necrosis, *ex. croupous*, *diphtheritic* and *aphthous* inflammation; in the latter condition, changes like those described under diphtheria are observed. (*See inflammation of mucous membranes*, Chap II., and *coagulation necrosis*, p. 97, and E. Fraenkel, *V. A.*, 113). A very severe gangrenous inflammation has been referred to under *Noma* (p. 101 and Chap. II., fig. 15). *Ulcerative* stomatitis frequently accompanies scorbutic affections and the administration

of mercury.* Various degrees of *glossitis* are common in febrile affections; they are marked by redness, swelling, softening (indicated by teeth impressions) and furring due to the accumulation of catarrhal products and the products of micro-organisms. In severe cachectic conditions, or as a mild infective process in children, *oidium albicans* (p. 125) produces the characteristic white patches of "thrush."† The *ulcers* of the tongue are the most important inflammatory affections of that organ. They may be simple, *tubercular*, *syphilitic* and *malignant;* a curious *ulcus migrans* is described by Barker.

In the inflammations of the *pharynx*, *redness*, *œdema*, *catarrh* and *ulceration*, and the formation of *membranes* are very obvious. Catarrh with the increased production of mucus to which it gives rise is very common in chronic inflammatory conditions; it is accompanied by atrophic and hyperplastic changes, (these will be referred to again under chronic inflammation). Tubercular and syphilitic ulceration produce widespread changes; *stenosis* may result in the case of syphilis.‡

Gastritis.—There are several varieties of gastritis of greater or less severity. In the *acute specific fevers*

* Specific ulcers may be produced by the virus of Syphilis, Tubercle or Actinomycosis.

† It may also occur in other portions of the alimentary canal, *i.e.*, the œsophagus.

‡ The pharynx, like the whole of the intestinal tract (especially around orifices), is very rich in lymphoid tissue, and in sections the small round cells are always a conspicuous feature in cases of inflammation. Special collections of lymphoid tissue exist in the tonsils, and these like Peyer's patches and the solitary follicles (see further on) may undergo inflammatory hyperplasia and ulceration (Tonsillitis).

(*ex.* scarlet fever) a simple gastritis is frequently present; an *eczematous* form associated with eczema is described by F. Fenwick; emphysematous (E. Fraenkel), diphtheritic and pustular gastritis, as well as localised and diffuse suppurative conditions are very probably *mycotic*. Marked inflammation and injection of the vessels are very frequently observed in extensive skin *burns* and constantly in *hydrophobia*. Amongst the changes to be noted in the less severe cases are, swelling of the mucous membrane, injection of the vessels, desquamation, fatty degeneration or proliferation of the gland cells, increased secretion of mucus, distension (often extreme), increased acidity (lactic and other acids), increase of micro-organisms. In hydrophobia the dark brown or black patches and streaks to which the congested vessels and extravasations give rise are very often extremely prominent. In the *membranous* varieties, which are often associated with similar conditions in the pharynx, the changes are similar to those described under croup and diphtheria. Smirnow following Recklinghausen lays stress on the hyaline transformation of the epithelium in these cases. *Ulceration* occupies a very prominent place amongst the pathological changes of the stomach. In its causation tubercle and syphilis, which throughout the rest of the intestinal tract are such potent factors, are here of little moment (compare p. 117). One of the chief causes appears to be the cutting off or diminution of the blood supply by thrombosis and embolism of the branches of the coronary arteries; a condition of *infarction* is thereby produced, and changes partly necrotic, partly due to digestion, proceed with greater or less rapidity. In the intestines very extensive in-

farction and necrosis may also result from thrombosis, emboli or strangulation cutting off the blood supply. The vessels in the former cases may be the seat of endarteritic and hyaline changes. In addition to the above there are numerous other causes of ulceration, the nature of which, except in the case of the mycotic, are very obscure. Thus in *pernicious* and other severe forms of ANÆMIA not only is gastritis very common, but ulcers are occasionally found; similar phenomena are observed in the stomach and the duodenum after extensive burns.* The ulceration and gastritis has in both cases been attributed to the excretion of some irritant toxic product; on the other hand Klebs lays stress on blocking of the vessels by hyaline emboli formed at the seat of the lesion. As will be seen further on, the local application of irritants produces ulceration, and in mercury poisoning extensive ulceration of the lower bowel is a marked feature. The ulcers may be single or multiple, acute or chronic; a sharply defined round ulcer of about one inch in diameter with a thin floor formed by the muscular or fibroid layers, appears not uncommonly on the posterior surface of the stomach. The ulcer may perforate and give rise to peritonitis; occasionally the floor is formed by the liver or pancreas. In the more chronic ulcers, the edges become heaped up owing to connective tissue and glandular hyperplasia. Healing with cicatrisation may terminate the process. Malignant ulcers are not uncommon, and chronic ulcerative processes are in many cases associated with tumour formation.

Post-mortem digestion.—This appears to be much

* Lesser observed in one of his experiments an ulcer in the intestine after severe burning.

more frequent in cases of sudden death. The mucous membrane of the stomach may be swollen and gelatinous;* or it may be completely dissolved, with perhaps the muscular layer, over a large or small area; sometimes all three coats are eaten through. The digestion occurs only where the gastric fluid is in contact with the stomach wall, and this is in the majority of cases the posterior.

Enteritis (*ileo-colitis*, *typhlitis*, *proctitis*).—The various forms of inflammation already met with in the pharynx and stomach also occur in the intestines. Some of the most characteristic of them are excited by *micro-organisms*, less commonly by *animal parasites*, and will be described under typhoidal, tubercular, dysenteric, choleraic and parasitic affections of the intestine. In the lower gut as in the pharynx *syphilis* seems to be a special cause of inflammation. *Putrid intoxication* (p. 102), and in certain cases *mercury*, produce an intense inflammation, most marked in the large intestine, and closely resembling that seen in dysentery (*q. v.*). Many of the *acute specific fevers* as scarlatina and diphtheria are accompanied occasionally by enteritis and swelling of the mesenteric glands. Irritating *foreign bodies* produce local reactions. *Embolism* and *thrombosis* of the mesenteric vessels (Altmann, Kaufmann) and *strangulation* of the gut produce various degrees of widespread necrosis and inflammation (including hæmorrhagic infarction, formation of membranes, &c.). The changes observed in the several forms of enteritis include congestion, swelling of the mucous membrane; swelling and increase of the lymphoid tissue, which as in the pharynx is especially

* Pitted in one case, Museum, U. C. L., No. 3036.

abundant; desquamation and proliferation of the glandular epithelium; formation of watery, albuminous, mucous, purulent and bloody discharges; blocking of the mouths of the glands and dilatation; ulceration and the formation of membranes as in croupous and diphtheritic conditions. The mesenteric glands and the spleen share to a greater or less extent in the inflammatory changes.

Typhoid, Dysentery and *Cholera.*—Typical pictures of enteritis are furnished by these three mycotic affections. In typhoid, changes are most marked, the bacillus (p. 103) gives rise to inflammatory reactions which usually last for some weeks. The lesions are most prominent in the small intestine and upper portion of the colon. In the earlier stages the solitary follicles and Peyer's patches are markedly swollen, and **Fig. 108** under a very low power shows the fungating mass of lymphoid tissue to which an agminated gland may give rise. In the more highly magnified section through a solitary follicle in the colon, **Fig. 107,** the results of the inflammation may be seen. The follicle (3) is swollen, and the columnar epithelium covering it has disappeared; the glandular layer on each side is swollen owing to the increase of the interstitial connective and lymphoid tissue; the glands show an undue tendency to fall out in preparation, some are dilated, and the mouths of many have disappeared together with the columnar epithelium on the surface. The submucosa (4) is swollen. Similar changes may be found throughout the affected portion of the gut. A later condition is well shown in **Fig. 109,** which represents the typhoid ulcer. A swollen Peyer's patch has ulcerated, or the commencing ulceration depicted in fig. 107

Fig. 107. ENTERITIS.

1. Crypt of Lieberkuehn. 3. Swollen lymphoid follicle
2. Muscularis mucosæ. 4. Swollen areolar tissue
5. Muscular layer.

Obj. ½ in. Logwood.

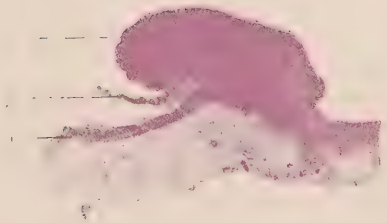

Fig. 108. SWOLLEN PEYER'S PATCH.
(Typhoid).

1. Swollen lymphoid tissue. 2. Glandular layer
3. Muscular layer

Magnified 4 diam. (Eosine and logwood)

has spread, resulting in the exposure of the muscular layer; the remains of the swelling are seen at the heaped up edges on each side; the latter are slightly undermined, and the vessels in them greatly engorged. The serous coat, as the figure shows, is distinctly thickened, and the lymphatics and vessels in it are dilated. Perforation or healing may occur; in the latter case only a slight cicatrix is usually left. There is very considerable hyperplasia of the adenoid tissue of the mesenteric glands and the spleen is in very many cases much swollen. The general parenchymatous changes indicated on p. 102 are marked in typhoid.

In *cholera* the reactions are much more acute; there is inflammation of the glandular layer, and there may be swelling of the lymphoid follicles; there is great vascular congestion often accompanied by hæmorrhagic exudation; ulceration and the formation of sloughs and membranes may occur.* The spleen may be very small.

Dysentery.—Dysentery furnishes several types of inflammation and the *hyperplastic* changes met with in the chronic forms are especially instructive and will be reserved for separate discussion. Under figure 11 a *croupous* and *diphtheritic* variety was described. More characteristic perhaps is a "spongy hypertrophy" of the mucous membrane. In this case the condition represented in figure 107 is more marked, and a pitted appearance is given to the mucous membrane by the ulcerated follicles buried in the swollen glandular layer.

In the more chronic cases the hypertrophied mem-

* In the Museum Catalogue of University College London it is stated that extreme congestion and sloughing of the uterine mucous membrane was frequently observed in the epidemic of 1866.

brane consists of very vascular and corpuscular granulation tissue and hyperplasia of the lymphoid tissue is especially evident; the mouths of the glands become lost in the granulation tissue, and only the fundi remain. Suppuration, deeper ulceration and sloughing may occur.

Tubercle.—The characteristic inflammation excited by the bacilli appears to commence in the majority of cases in the lymphoid follicles. The infected spot becomes the seat of numerous typical nests, and swelling and infiltration of the wall results. Tubercular foci fuse, caseation occurs and an ulcer is formed. This is well represented in **Fig. 110**; in marked contrast to the typhoid ulcer depicted above it, the floor is thick and formed of the infiltrating tubercular granulation tissue; the muscular coat is occupied by numerous nests (2);* the lymphatics (1) in the serous layer are the seat of early tubercular changes and were in the recent state plainly visible from the peritoneal surface. The edges of the ulcer are heaped up and undermined, and are very frequently the seat of interesting hyperplastic changes; thus proliferation of the glandular epithelium and the formation of cystic and adenomatous growths may often be observed, and in some cases the ulcer becomes fringed by papillomatous and polypoid glandular fibroid hyperplasias (*see* chronic inflammation). It is rare for healing and cicatrisation to occur, but it may happen and lead to stenosis (Treves). The mesenteric glands become infected.

In addition to the above mycotic affections there are others such as *actinomycosis* and *anthrax*. Numerous *animal parasites* infest the alimentary tract of which

* In the description to the figure the numbers 1 and 2 have been reversed.

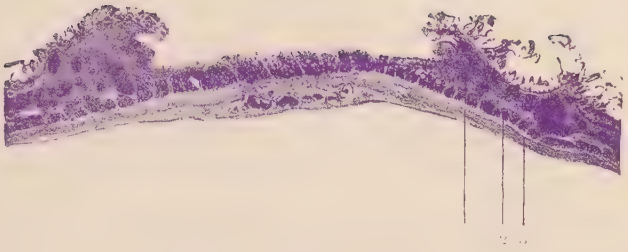

Fig. 109. TYPHOID ULCER.

1. Mucous membrane. 2. Muscular layer.
3. Serous layer

Obj. 4 in. Logwood.

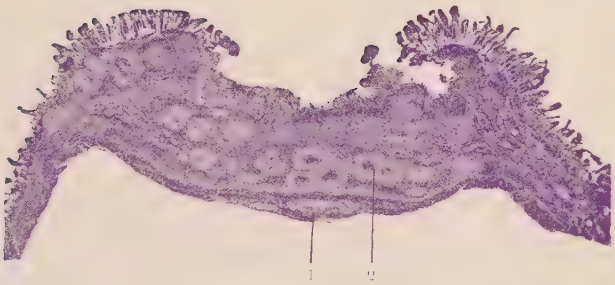

Fig. 110. TUBERCULAR ULCER OF INTESTINE.

1. Tubercle nests in the mucous membrane.
2. Tubercular thickened lymphatics in serous layer

Obj. 4 in. (Logwood).

some like the trichinæ may give rise to severe enteritis (*see* Parasites).

The chronic inflammatory processes such as *chronic glossitis*, *pharyngitis*, *gastritis* and *enteritis*, may be conveniently brought together in order to review the interesting atrophic, hyperplastic, cystic and other changes which result therefrom. In *chronic glossitis* the surface epithelium may assume a smooth whitish appearance from atrophy of the papillæ. To this condition the term *leucoplacia* has been given, but it is also used to designate the *psoriatic* and *icthyotic* condition described on p. 157 (*q. v.*) and which is not rare in chronic inflammatory conditions of the tongue. On the *gums*, in the case of carious teeth, the formation of papillæ has been referred to p. 134. In *chronic pharyngitis* both smooth, glistening and atrophic, and granular, papillomatous and hyperplastic changes are frequently observed. In *chronic gastritis* the changes are numerous and interesting, and consist of fibroid induration and hyperplasia, glandular proliferation and atrophy, and cystic changes. Most chronic inflammatory conditions appear to centre around the pylorus, and, as will be hereafter seen, tumours are most frequent in this situation. Habershon long ago described a pyloric sclerosis. As a senile change induration and atrophy of the glands may occur; the same may be associated with cirrhosis of the liver. Phthisis according to the great majority of observers is very frequently accompanied by an atrophic cirrhosis of the stomach; the association is also frequent in pernicious anæmia. According to Fenwick, mammary cancer is in very many cases accompanied by chronic gastritis. In gastric cancer marked inflammatory changes are very often present;

amongst these may be mentioned catarrh, cystic dilatation and proliferation of the gland tubes, connective tissue hyperplasia, induration and atrophy of gland tubes; ulceration may also occur. The question has naturally been asked whether these changes are the result of the cancer, or whether the cancer is secondary to the inflammatory changes and like them the result of chronic irritation; there is much evidence in favour of the latter view. The wall of the stomach may become atrophied or thickened, and the connective tissue increase is sometimes very great; the muscular and glandular layers in these conditions usually undergo atrophy, and papillæ and polypi may be formed. Hanot and Gombault describe an interesting case of hypertrophic cirrhosis associated with a retro-peritonitis. In *chronic enteritis* (very frequently dysenteric) the most remarkable hyperplastic changes are frequently found; thus the whole intestine may be studded with polypi, glandular, cystic or fibroid; cystic changes may be almost equally widespread; around ulcers as already mentioned, papillæ and polypi may be found. It may be mentioned that chronic inflammatory and ulcerative conditions are frequent in the neighbourhood of the ileo-cæcal valve, and that tumours are here also of very common occurrence. Amongst other changes, which may be observed, are either atrophy of the intestinal wall or connective tissue hypertrophy, leading perhaps to stenosis; in both cases there may be marked glandular atrophy.

Effects of Toxic Agents.—Numerous observations have been made upon the effects of *caustic fluids*, *alcohol*, *phosphorus*, *arsenic*, *lead*, *mercury*, *&c.*, on the alimentary tract, and many opportunities are afforded in

man of studying the lesions produced by caustic and powerful irritants. On more than one occasion reference has been made both to the severe enteritis occasioned by mercury (*in treatment of wounds, &c.*), and to the enteritis of septicæmia. Similarly intense hæmorrhagic and necrotic inflammation is produced by eating putrid meat. Weigert in his early experiments on coagulation-necrosis applied ammonia to the larynx and induced the formation of a membrane; Kiener and Kelsch applied it to the intestine with similar results. Phosphorus, arsenic, lead and alcohol produce inflammatory results proportional to the doses administered; amongst the changes to be observed are redness, œdema, hæmorrhage, fatty degeneration of the gastric glands, ulceration, fibrosis. R. Maier stated that he obtained, in experimental lead poisoning, sclerosis of the intestinal and mesenteric plexuses. The strong acids and caustics produce in the mouth, œsophagus and stomach various degrees of inflammation and necrosis, such as marked congestion and œdema, hæmorrhages, deep necrosis, ulceration and perforation; owing in addition to the inhalation of the fumes in many cases of poisoning by the strong acids, congestion and œdema of the lungs may occur.

Atrophy, Dilatation and Hypertrophy.—These conditions are typically illustrated in the alimentary canal. Atrophy and fibroid degeneration of the bowel is most conspicuous, when owing to the formation of an artificial anus, a portion of the gut is rendered functionless; in one of these cases the formation of fibrous bands and valves has been described. Atrophy and dilatation of the stomach and intestines, often extreme, are observed in cases of obstruction; in

some, however, no obstruction can be found. Hypertrophy of the muscular, followed by that of the other coats, is frequently seen in cases of partial obstruction, both in the œsophagus, stomach and intestines. The thickness of the muscular wall may be very great and the lumen may be considerably decreased, or on the other hand dilated ; the stomach is often rendered non-collapsable and has been compared to an india-rubber ball or leather bottle. When the obstruction becomes extreme, or when inflammatory changes supervene, the muscular tissue is gradually replaced by fibrous and the walls yield and give rise to a dilated fibrous sac.

Diverticula.—Diverticula of the pharynx, œsophagus and intestines are especially numerous and many examples have already been cited in the chapters on tumours (see p. 202). Attention should especially be directed to the branchial, Rathke's, Meckels' and post anal diverticula, and to the vermiform appendix.

Tumours.—There are two classes of tumours, both simple and malignant, one embracing the hyperplasias and closely associated with chronic inflammatory processes, the other allied to congenital growths and occurring independently of inflammation. As yet there are not sufficient data to sharply divide these groups, either anatomically or ætiologically, but we may venture to state that the former tends to be *atypical*, the latter *typical*.* The following tumours might be included

* Typical, that is, repeating peculiarities of the parent tissue more or less closely. *Examples :* the squamous epitheliomata with marked horny nests, enamel-germ tumours, adeno-sarcomata, typical columnar epithelioma, sarcoma, congenital cysts, very many ovarian cysts, &c. Examples of the *atypical* are, the solid glandular carcinomata, including the medullary and scirrhoid forms, rodent ulcer, Paget's disease and hyperplasias. *See mamma, Chap. XVIII.*

under the congenital:—*Leiomyomata*, which occur in the intestine. *Fibromata*, found in the tongue or intestine. *Nævi*, in the rectum, tongue, &c. *Lymphangiomata*, in the tongue especially. Typical *adenomata* or *adeno-papillomata*, unassociated with chronic inflammatory processes; examples may occur in the buccal cavity, stomach or intestine; some of the tumours reach a large size. *Cystic* tumours depending upon congenital defects are probably common (pp. 192 and 193); they include ciliated and dermoid cysts in the tongue and pharynx, cysts in the ileum, rectum, &c. The special congenital tumours of the pharyngeal region have been already sufficiently discussed. Amongst the *sarcomata* an interesting *melanotic* form has been described in the palate by Treves; this case may be associated with the occurrence of *black tongue* (non-mycotic), and the pigmented lingual dermoid, mentioned in the chapter on growths. The *adenoid* tumours are amongst the most striking of the alimentary tract and occur very often multiple as in lymphadenoma and leucocythæmia; they are, moreover, not confined to the special collections of lymphoid tissue such as the tonsils, solitary follicles and Peyer's patches, but also occur in the diffuse adenoid tissue, which is so plentiful throughout the alimentary tract.

Tumours which may be ranged under the acquired, include the numerous *hyperplasias* associated with chronic inflammation and already referred to in this chapter (chronic inflammation); the additional observation may be here noted, that *Bilharzia* may give rise to vegetations in the intestine (Zancarol).

The *malignant epithelial tumours* may be divided also into congenital and acquired. In the mouth (tongue es-

pecially) *squamous epitheliomata* occur, and we think that there is strong evidence in favour of two varieties, one (typical) which springs from a single point and is characterised by numerous horny nests, and another more common, which is associated with irritative processes, tends to affect a spreading area of epithelium, and in structure more closely resembles a rodent ulcer (scirrhoid or atypical type). The latter variety is the growth which commonly arises from the stratified surface of the pharynx and œsophagus.

The enamel germ tumours are examples of congenital epitheliomata.* Throughout the columnar celled portion of the alimentary tract, the atypical glandular cancers are much more common than the typical. The latter type is probably represented in **Fig. 75,** and is taken from the rectum—the commonest seat of this form; it corresponds to the typical columnar epithelioma and malignant adenoma (adenoma destruens, Ziegler); we know very little of its mode of origin. In the atypical growths,† the malignant change takes place in the glandular epithelium after the manner depicted in **Fig. 66.** The change affects several glands, and the area affected tends to increase; hyperplasia of the adjacent

* In the buccal and pharyngeal cavities, *glandular tumours* may occur in the lips, tongue, cheek, palate and tonsils.

† Hauser has beautifully illustrated these tumours in an extensive monograph, but he adopts a quite different method of classification. His divisions are:—

1. Carcinoma adenomatosum . { Simplex. Medullare. Scirrhosum. Microcysticum. Gelatinosum.
2. Carcinoma solidum . . . { Simplex. Medullare. Scirrhosum.

gland tubes and of other tissue elements is present, and usually all the signs of a chronic inflammatory process. The resulting tumours form solid epithelial cylinders and alveoli like those depicted in **Figs. 65, 67, 70, 71, 72** and **73.** Metastasis is common and of the type shown in **Fig. 76;** according to Hauser the gastric cancers form metastases in the liver more frequently than the others; metastasis of the typical columnar epithelioma seems a rare occurrence. The favourite cancer regions are the pyloric and cardiac orifices of the stomach, the ileo-cæcal valve and rectum, but they may occur in any part of the intestine or stomach.

Colloid or *gelatinous* and *cylindromatous* cancers are frequent modifications in the alimentary tract, the colloid variety very often occurs as a widely infiltrating growth, either in the stomach or intestine. Ulceration and papillomatous and polypoid formations are common to all varieties.

Healing of Wounds.—The process is simple, there is connective tissue, muscular and glandular hyperplasia; the connective tissue growth, as is generally the case, is in excess of the others and partly replaces both the muscular and glandular elements (*see* A. Ritschl, V. A., 109).

Animal Parasites.—These are very numerous, and the more important varieties will be illustrated and referred to in the chapter on parasites.

Chapter XVII.

RESPIRATORY SYSTEM.

Nasal Cavity.—Chronic inflammation of the nasal mucous membrane is common; it embraces chronic *catarrh* with muco-purulent, and *ozæna* with fœtid discharge, and the destructive *syphilitic* and much rarer tubercular ozænas. These conditions are marked by atrophic and hyperplastic changes, whilst in syphilis ulceration of the mucous membrane, and of the bones are very common; in some cases the epithelium stratifies (*psoriasis nasalis*). In the mycotic affection known as *Rhinoscleroma*, there is a small round celled infiltration of the mucous membrane, which commencing at the nostrils spreads upwards into the nasal cavity, and externally on to the face; the infiltration may be followed by the formation of a very dense, hard scar tissue. Small hyaline bodies are frequently present in the granulation tissue. Amongst the severe acute inflammations may be mentioned the *diphtheritic*.

The *tumours* of the nasal cavity include the *myxomatous polypi* already described (p. 134, **Fig. 51**) and *condylomata;* they may be covered by stratified or columnar epithelium. Nævoid cartilaginous and bony tumours may occur. An important group, including fibro-sarcomata, chondromata, and lipomata may grow down from the base of the skull.

Larynx, Trachea and Bronchi.—Acute inflammation of the larynx and trachea is very frequently observed in the acute specific fevers, in septicæmia, and after the inhalation of irritant gases (compare *intestinal*

tract). As already described in the chapter on acute inflammation, there is congestion, **Fig. 9,** œdema, small round celled infiltration, desquamation and proliferation of the covering epithelium. In the severest forms, *croupous* and *diphtheritic* inflammation occur, and in these cases the membrane formation may penetrate to the finer divisions of the bronchi; sometimes casts are expectorated. The application of ammonia (Weigert), and the inhalation of the vapour in cases of ammonia poisoning give rise to similar conditions. *Acute œdema of the glottis* may supervene in the course of the chronic inflammatory process or be due to acute irritation. A marked œdema may occur in Bright's disease.

Chronic inflammation of the larynx is due to a variety of causes, but *tubercle* and *syphilis* produce some of the most extensive and destructive changes. Tubercle appears under several aspects. In early stages the granulations may be recognised in the larynx and trachea, later these may give place to innumerable small punched out ulcers; or the inflammatory reaction may be limited to one spot and lead to spreading hyperplastic and ulcerative changes; in another variety—hypertrophic laryngitis—diffuse, polypoid and papillomatous formations of infiltrated connective tissue may occur. (All these forms are just like those seen in the alimentary tract). In syphilis gummatous infiltration of the mucous membrane, ulceration and hyperplastic changes occur; stenosis of the larynx much more frequently results from syphilitic inflammation than from tubercular. The *hyperplastic changes* met with in chronic inflammation of the larynx, have within the last few years attracted much attention, especially in connec-

tion with their relation to neoplasms.* The changes are quite similar to those already seen in other mucous membranes, serous surfaces, and in glandular organs. They consist (*a*) in *stratification* and often *cornification* of the epithelium in place of the ciliated, or single layer of flattened cells in the case of the vocal cords, and of hyperplasia and cornification of the epithelium where this is already stratified; (*b*) in the formation of granulations and *papillæ* of very various sizes, which are covered by stratified or columnar epithelium; (*c*) of *cystic* dilatation and proliferative changes of the glands; (*d*) of *hyperplasia of the connective tissue;* and (*e*) of *ossification* of the laryngeal cartilages. The majority of these changes are especially marked in tubercle of the larynx. In the trachea stratification has been recorded around ulcers.

Tumours of the Larynx, Trachea, and Bronchi.—The majority and most important of these are asso-

* Rheiner under Virchow's direction seems early (1851-1852) to have described these changes. Independently, apparently, French observers notably Doleris (1877) drew attention to the dermoid metamorphoses. In 1887, Virchow under the title of *Pachydermia laryngis* again brought these changes into prominence; since that date numerous communications have appeared from his and other laboratories by Heymann, Kanthack, Hünermann, Posner and the laryngologists Fränkel and Störk.

The minute anatomy of the larynx has been carefully worked out by many observers, and more recently, and in more detail by many of the above cited authorities. Solitary lymphoid follicles are occasionally found in the larynx, a diffuse infiltration of lymphoid cells is much more common; mucous glands are very plentiful, and come close up to the vocal cords. In the fœtus a much larger area of the larynx is ciliated than in the adult In connection with the subject of physiological dermoid changes. Posner and Bland Sutton have examined the stratification and cornification which is normal at the *pylorus* of certain animals.

ciated with the hyperplasias just mentioned, and consequently may be classed amongst the acquired growths. They include fibro-papillomata, cauliflower-like and polypoid growths, all of which may be covered either by stratified or columnar epithelium (ciliated rare), and of fibro-myxomata and cysts. In the larynx their most frequent seat is the anterior portion of the vocal cords, and they are much more frequently suprachordal than infrachordal. Amongst tumours which may be probably classed with the congenital are some papillomata and cysts, fibromata and chondromata. A case of *lymphoma* of the larynx is well figured by Wolfenden and Martin*; adenoid growth may also occur in lymphadenoid and leukæmic conditions. Adenomata have been described in the trachea of a tiger fœtus.

The keratoid and papillomatous conditions may give place to a *malignant* change; in this case papillomata if present tend to subside, and the epithelium grows in deeply amongst the tissues, and is followed by ulceration on the surface (*see* p. 161). The cancer is an epithelioma consisting of solid epithelial processes and nest-like formations. As a limited downgrowth of epithelium and formation of nests may be observed in tumours which remain local, a diagnosis founded on the microscopic examination of a minute fragment of a growth is in very many cases of little value as regards deciding whether the growth is malignant, but the discovery of these epithelial changes will leave no doubt as regards the malignant tendency of the growth.

Malignant epitheliomata of the trachea and larger

* "Studies in Pathological Anatomy of the Larynx," (excellent illustrations).

bronchi are rare, they consist of solid epithelial processes (scirrhoid and encephaloid types) and appear to take their origin from the epithelium or the mucous glands. The hyperplastic and malignant changes of the minuter bronchi are probably much more frequent, they will be referred to later on. Several cases of retrotracheal and other cysts have been described (*see* p. 202 for a congenital tracheal diverticulum). Paltauf has recently described thyroid tissue in the larynx and trachea (*see* Bibliography).

The Lungs and Pleuræ.

Inhalation experiments. Pneumokoniosis.—References (q. v.) have already been made to the subject of dust inhalation on pp. 86 and 225. Dust inhalation and the absorption of fluids from the lungs and pleura have been rightly made the subject of numerous important researches, notably by Arnold and Fleiner. The anatomy of the pulmonary and pleural lymphatic systems has at the same time been carefully worked out by Burdon Sanderson and Klein in this country.* These researches show that lymphatic nodules are to be found in the tracheal and bronchial mucous membrane, around the minute bronchioles and arteries, and beneath the pulmonary and mediastinal pleuræ,

* Virchow's Archives contain a large share of these researches, viz., Recklinghausen, B. 26; Afanassiew, B. 44; Knauff, B. 39; Arnold, B. 80; Fleiner, B. 112; Ins, B. 73; Rupperts, B. 72; Nothnagel, B. 71; Friedreich, B. 30; Slavjanski, B. 48. Amongst additional important observations may be mentioned those of Zenker, Merkel, Korn, Traube, Virchow, Holm, Lewin, Begbie, Greenhow, Thomson and Christison; numerous other references will be found in Arnold's works, and in the important "Atlas of the Pathological Anatomy of the Lung," by Wilson Fox.

&c.;* that fluid and minute particles are very readily absorbed from the respiratory passages and alveoli. Thus inhaled blood very rapidly appears in the interstitial tissue and in a few minutes in the subpleural and bronchial glands; fluids containing minute particles in suspension are with almost equal rapidity absorbed, the lines along which the absorption takes place being accurately mapped out. The experiments also seem to show that after a slightly longer period, a small portion of the fluid may find its way into the pleural cavity. Further, fluid containing minute particles in suspension injected into one pleural cavity rapidly passes into the other, and within a few minutes begins to map out the lymphatics of the mediastinal, diaphragmatic and costal pleuræ; a few minutes later the particles appear in the mediastinal, tracheal, jugular and left supra-clavicular glands; the pulmonary pleura and the bronchial glands remain free. Fleiner concludes from his experiments that there are two streams from the surfaces of the alveoli, one which passes to the bronchial glands and from them tends to be excreted into the bronchi, another which passes out to the subpleural glands and from thence into the pleural cavity; from this it is taken up and passes to the mediastinal and other glands as above described. He also concludes that carbon and other particles found in the mediastinal glands in cases of natural and artificial inhalation have passed through the lung and pleural cavity. He also draws attention to the difference in rate of absorption of different fluids; it may also be pointed out that in the case of the inflammatory

* The wide distribution of adenoid nodules is probably revealed in the cases of miliary lymphomata.

exudates, the initial damage to the absorbent surface has an important influence. There is considerable evidence in disease in support of the above experiments and deductions ; for instance, the very rapid absorption of certain exudates and the abundant expectoration which may accompany it ; probably the *black spit* mentioned on p. 86, and the red spit in Zenker's case,* support the view as well as the frequent deposition of particles of carbon in the costal pleura and in the pulmonary tissue when no adhesions exist, or in the case of adhesions, its occasional abundant deposition in them. The experiments further show that particles may pass directly into the lymphatic stream without the intervention of the lymphatic corpuscles. But it is also true that irritant particles and especially micro-organisms can call forth an inflammatory reaction in the alveoli, and that the particles may be taken up by the leucocytes which may transport them to the interstitial lymphatics or lymphatic glands. Numerous experiments have been made upon the effects of the inhalation of *irritant* gases, dust and micro-organisms ; the result is usually the production of a very severe broncho-pneumonia more rarely of a diffuse inflammation. Amongst the substances experimented with have been steam (Heidenhain), silver nitrate (Veraguth), perchloride of iron, metallic mercury, &c. ; Fox observed a case in which after the inhalation of ammonia the lung was studded with small foci as in broncho-pneumonia. Ether (**Fig. 1**) may produce a diffuse congestion and œdema. In relation to tubercle of the lung and pneumonia, a very large series of

* Oxide of iron. For further cases of black spit, *see* Thomson, "Med. Chir. Trans.," vol. xx.

inhalation experiments have been performed, either with cultures of micro-organisms or with infected substances; in the case of tubercle, broncho-pneumonic nodules of the characteristic structure of tubercular granulation tissue have been obtained, and occasionally more wide-spread catarrhal changes.

PNEUMOKONIOSIS OR DUST INHALATION DISEASES.—The dusts which occur in the various occupations are numerous, and include coal, stone, mineral salts, metallic particles, pigments, flour, &c. The pigmentation induced varies according to the nature of the dust, but a dark colouration even when the inhaled dust is white, is regarded as characteristic and is set down to a blood pigment. The irritant properties of the inhaled particles vary, and in consequence the inflammatory reaction may be slight and gradual or very severe. In the former case the dust slowly accumulates in the pulmonary tissue, bronchial and mediastinal glands; as it does so it excites a slow general cirrhosis, most marked in the interlobular septa, beneath the pleura and around the small bronchi. The supervention of acute inflammatory changes appears to interfere with the absorption of the pigment and to cause it to be deposited in greater quantity, witness for example the thick black layer of carbon to be found beneath the pulmonary pleura when the latter is thickened. Sometimes the pigmentation with the attendant cirrhosis is more marked in a particular lobe or apex; at other times it occurs in a scattered nodular form, and usually the more irritant the particles the more the *broncho-pneumonic* type is assumed. The predisposition of pneumokoniosis to infective processes, such as tubercle, varies much with the nature of the dust and attendant

circumstances; thus according to Ogle, phthisis is very infrequent in coal miners' lungs, whilst comparatively common in those of file makers or of Cornish miners.

Broncho-pneumonia (catarrhal, lobular or disseminated pneumonia).—Under these headings a very large proportion of the acute and chronic pulmonary lesions may be grouped. They are caused by the spreading of inflammation from the higher air passages to the lower minute branches and infundibula; by the inhalation of irritant dusts, vapours, micro-organisms and fungi, and they are further associated with many of the acute specific fevers such as measles, scarlatina and small pox, and with septicæmia. As seen in the dust diseases, the reaction may be confined to a particular group of lobules; more usually, however, the foci are scattered corresponding to the terminal bronchioles and infundibula, and present the picture of the *acute miliary broncho-pneumonia* represented in **Fig. 10**; in this particular case the cause was probably mycotic. Depending upon the nature of the irritant, the focal character of the lesions may give place to a diffuse inflammatory reaction affecting large areas and presenting the appearance of acute lobar pneumonia. The *chronic* types of broncho-pneumonia are very common, and one form the *catarrhal* is especially characteristic. A section of the latter condition is represented in **Fig. 5**, and contrasts with figure 10. Conspicuous in the alveoli are the large cell form (macrocytes) and the red and white corpuscles; the alveolar septa and minute bronchi are the seat of hyperplasia, connective tissue, vascular and glandular; in the older portions the place of many of the alveoli is occupied by a vascular connective tissue. In the catarrhal form the lesions tend

to spread over extensive areas of lung tissue. A large celled infiltration is present in all chronic pneumonias.

Chronic pneumonia, chronic cirrhosis, &c.—This condition may follow on any acute pneumonia provided the irritation is kept up ; the chronic infective granulomata already described furnish most marked examples, and cirrhotic processes associated with chronic bronchitis and the inhalation of dusts are frequent. If the process starts as a peri-bronchitis, the proliferative and fibroid changes around the bronchi spread to the interlobular and alveolar septa, and the pleura thickens. If the process is excited by tubercle, appearances similar to those depicted in figures 19, 20, 21, 22 and 111 are common. In most cases there is an overgrowth of vascular and corpuscular fibrous tissue, which spreads from the foci of irritation and involves the larger vessels, bronchi and interlobular septa ; the inter-alveolar walls thicken, and any alveolar contents which may be present become organised (fig. 17) ; finally, extensive patches of consolidation result as in figure 111 ; this figure also shows the *chronic pleurisy* which very frequently accompanies the pneumonia. Owing to the fibrosis of the walls of the bronchi and alveoli, *bronchiectasis* and *emphysema* are usual ; the latter condition is well represented in many of the preceding figures. A gradual *collapse* and approximation of alveolar walls is common, and is due to the blocking of bronchioles. The vessels may be the seat of *endarteritic* changes, and the impediment to the circulation may be great, congestion and dilatation as in other cirrhotic processes being often very marked. Many of the alveoli contain numerous red and white corpuscles and the large cells already described.

Patches of pigment are usually abundant. In the mycotic affections various forms of necrosis as *caseation* and *calcification* are prominent features, and these conditions as described in the earlier chapters very frequently lead to *ulceration* and the *formation of cavities*.

The very interesting *hyperplastic* changes in chronic pneumonia have long attracted a scattered attention. Two classes of hyperplasia, *epithelial* and *sarcomatous*, are met with, but both are usually combined. They sometimes tend to occur in a scattered nodular form, but more commonly the proliferative changes are diffuse. In the connective tissue growths the cells may be fusiform or round (probably many of the round celled tumours are lymphoid hyperplasias); sometimes they assume a *papillomatous* form, and have been described as papillo-sarcomata (p. 138, in Cobalt miners' lungs). In the latter case the papillæ are very often covered by a proliferating layer of cubical epithelial cells (adeno-papillomata). Sometimes the epithelial proliferation is very marked, and small solid glandular-like acini are formed; or what appear to be the remains of alveoli become lined by proliferating cubical cells and into these papillæ may project. The source of the cells appears to be the lining alveolar, infundibular and bronchial cells; but the minute glands of the bronchi, when involved, also share in the proliferative changes. Eberth has described in cases of pneumonia verminosa a *muscular hyperplasia*.

Hypostatic pneumonia and *Brown induration*.—The former appears to be a variety of broncho-pneumonia accompanied by much congestion and exudation into the alveoli. The congestion and extravasation is most

marked at the posterior portions of the lungs and appears dependent upon the effects of posture; the condition is observed in prostrating diseases, and as Fox remarks its mechanism is probably complex. Brown induration is a chronic congestive and cirrhotic condition comparable to the nutmeg liver, which is associated with mitral obstruction or regurgitation. It receives its name from the pigments derived from blood extravasation. The pigment is granular or crystalline, and is deposited in the interstitial tissue; or the numerous cell forms which usually fill them are pigmented; for my part, however, I have not observed any marked pigmentation.

Croupous, fibrinous, or *acute lobar pneumonia*.—This is a mycotic pneumonia (p. 102) in which Fränkel's pneumococcus and probably other bacteria take an active part. The inflammation is commonly primary in the lungs and involves extensive tracts (lobar); a metastatic origin is however possible. The changes which may be observed in the lung, parenchyma and vessels are represented in figures 1, 2, 3 and 4, and are those which we have regarded as typical of an acute inflammation. It is usual to divide lobar pneumonia into three stages, viz., engorgement, red and grey hepatisation, the latter stage corresponding to the abundant small round celled exudation; in microscopic sections very commonly all stages are to be found. The presence in the alveoli of the fibrin network and corpuscles is very characteristic, and occasionally there may be dislodged from them fibrin casts by scraping the cut surface of the lung. Rapid softening and absorption of the alveolar contents is also very characteristic, and may or may not be accompanied by

expectoration. In cases which have died at late stages, the catarrhal appearance seen in figure 5 is very frequent; still later the process of absorption by vascularisation (fig. 17), may be observed. Occasionally the inflammation proceeds to suppuration, but this is more especially seen in the metastatic foci of inflammation excited by pyogenic micro-organisms. The *pleura* over the affected lung areas is the seat of acute inflammation.

Acute interstitial pneumonia, pleuro-pneumonia.—An inflammation confining itself to the interlobular septa and their neighbourhood and to the pleura is very rare in man. Fox (Atlas) has published a case of Carswell's in which the lymphatic system of the lungs was picked out by the pus it contained. In animals, however, the interstitial form appears very common (*pleuro-pneumonia*).

Pleuritis.—The early stage of acute pleurisy is represented in figure 6, in which the congestion of the subpleural vessels is very manifest. A very much later stage is represented in **Fig. 111,** in which the pleura is enormously thickened and was adherent. There is an abundant formation of dense fibrinous material which is partly organised. As in the case of serous surfaces generally the fibrinous material may become canalised by endothelial proliferation, and both loculi and cystic cavities may be formed. In places cubical cells may replace the previously flattened endothelial cells. A very large proportion of pleurisies appear secondary to lung inflammations. It has been held, however, that a pleurisy may give rise to a pneumonia (*pleurogenous pneumonia*), but the evidence of this is not great, and it is doubtful whether an extensive

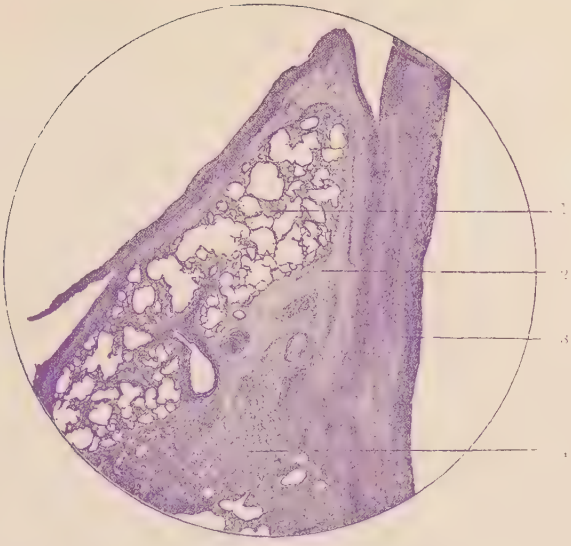

Fig. 111. CHRONIC FIBROSIS AND PLEURISY OF LUNG.

1. Pulmonary tissue, alveoli dilated.
2. Thickened interlobular septum.
3. Old partly organised fibrinous layer which bound the lung to the pleura.
4. Interstitial fibrous overgrowth.

Obj. 4 in. (Logwood).

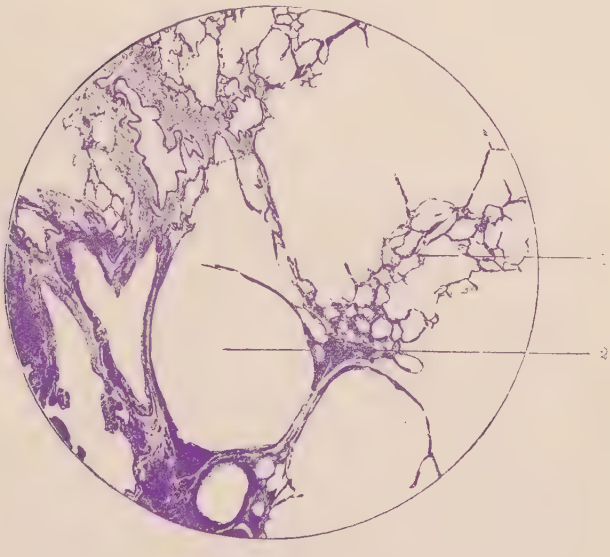

Fig. 112. EMPHYSEMA

1. Pulmonary alveoli with thinned walls.
2. Large dilated air space.

Obj. 4 in. (Logwood)

cirrhosis can originate in this manner (compare liver cirrhosis and peri-hepatitis). When the pleural cavity is the seat of a fluid or purulent exudation (*empyæma*), the lung tissue becomes compressed and atrophied, but there is no marked fibroid overgrowth.

The Chronic Infective Processes. (*Tubercle, pseudo-tuberculosis, actinomycosis, syphilis, pneumono-mycosis, zooparasitical granulomata and pneumonia verminosa.*

Tubercle—An immense number of experiments have been made relative to the artificial production of pulmonary tuberculosis.* These show that together with the lymphatic glands and spleen, the lung is the organ most prone to become infected by tubercle, either secondarily or when the virus is directly injected into the circulatory system. That infection by direct pulmonary injection or inhalation is very readily produced, and results in the majority of cases in a characteristic inflammatory reaction. The nature of the primary foci, their number and the rapidity with which generalisation occurs varies in different animals.

* In Fox's classical work (*l. c.*) will be found one of the best and most complete accounts of the artificial production of tubercle, a subject in which the author was most particularly interested, and concerning which he was led in his early experiments to conclude that tuberculosis could be produced by substances other than tubercular. Later he completely renounced this view "being convinced that there was some fallacy of his own, due probably either to imperfect disinfection of his instruments or to imperfect isolation of the animals."

Most interesting information is also to be obtained in the works of Burdon Sanderson, Klein and Watson Cheyne.

Sometimes there is an acute miliary broncho-pneumonia of the type represented in figure 10; very often indeed, scattered catarrhal foci are produced (fig. 5); more commonly, perhaps, the typical granuloma results (p. 49, &c.). The reactions may remain localised, spreading slowly, or they may more rapidly diffuse and give rise to secondary foci both in the lung and elsewhere in the system. Caseation is characteristic, but occurs in some animals much more readily than in others. Fox quotes an experiment of Veraguth's in the goat in which the nodules were large, fibroid, contained numerous giant cells, and had undergone calcification. The above variations in reaction may be accounted for by the differences of resistance to the virus, and the same probably holds good in the human subject. Thus in the common local form of tubercle, which occurs so frequently in the apex and is known as *phthisis*, the inflammatory reaction is very chronic; it is marked by the production of tubercular granulation tissue and outlying granulomata, by slow caseation, or under more favourable circumstances (p. 52, fig. 22), by a fibrous hyaline transformation, by calcification, by the formation of numerous giant cells and abundant epithelial connective tissue and vascular hyperplasia, by the slow breaking down of the necrotic material and its ulceration into a bronchus, expectoration and the formation of a cavity. Under unfavourable circumstances the chronic primary seat may give rise to wide spread secondary foci in the lungs or to general tuberculosis. Contrasting with the chronic form is the acute miliary tuberculosis, which frequent in young subjects, is marked by rapidly spreading small round celled in-

filtration and caseation, giant cell forms being absent.

The granulomata occur in various situations, a large proportion appear to commence in the walls of the alveoli; they are often found in the walls of the minute and larger bronchi; in the arteries and veins, wide spread miliary foci have been described in the intima by Weigert in a case of chronic tuberculosis; they are often abundant beneath the pleura.*

In the chapter on chronic inflammation and the infective granulomata, the anatomy of the changes which may be seen in pulmonary tuberculosis was described under figures 19, 20 (40 and 41), 21, 22, and above under figure 111. In addition stress may be laid upon the ulceration, formation of cavities, emphysema and bronchial dilatation which so frequently accompany the phthisical process. Particular attention is again directed to the hyperplastic processes which, as in the larynx and elsewhere, are particularly evident in chronic tuberculosis of the lung.

On page 113, *actinomycosis* of the lung is described, figure 39; on page 116, the *pseudo-tuberculosis cladothrica* of Eppinger, and on pages 118 and 119, further examples of pseudo-tuberculoses. From these pseudo-tuberculoses, which are due to a contagium vivum, must be separated the tubercle-like granulomata, which are produced by the inhalation of solid particles, or by the injection into the pulmonary artery (by the jugular vein) of lycopodium, cantharides and cayenne powders (Martin). The chronic infective processes excited by the higher fungi, as the aspergilli and mucorini

* Villi have been produced on the surface of the pleura by inoculation into the pleural cavity (compare peritoneum).

(p. 119), are sometimes spoken of under the term pneumono-mycosis. On pages 111, 112 and 113, examples are given of the *zooparasitical granulomata*. They are chiefly due to various species of nematodes, and the foci are local or diffuse; the term *pneumonia verminosa* (Eberth, ref.) has also been given to the process. In Japan a pulmonary *gregarinosis* is described by Baelz.

Syphilis.—As in so many other organs, great uncertainty exists in regard to the changes which should be considered as truly specific. Thus under syphilitic lesions there have been ranked a great number of pneumonic processes, either diffuse or localised (*gummata*), very cellular and catarrhal-like, fibroid and cicatricial or ulcerative. Very many of these lesions possess a structure indistinguishable from tubercular granulation tissue, and Fox indeed was of opinion that many were cases of tubercular change in a syphilitic subject; but similarity to tubercular tissue is no criterion, as giant, large and small round cells are common to the chronic pneumonias generally. Perhaps the most characteristic lesions are the peri-bronchial and the peri-arterial fibroses which are not uncommon in infants; endarteritis, however, in these cases appears not to be laid stress upon, nor have I in the few cases which I have examined, come across it in any marked degree. In several instances epithelial proliferation has been a prominent feature, Ziegler, Lorain and Robin, Greenfield and others recording examples.

Collapse or atelectasis.—Collapse of larger or smaller areas of air cells very frequently accompanies pneumonic and other pathological processes. The chief cause appears to be blocking of an air passage,

but very frequently this is combined with pressure on the alveoli from the surrounding tissue; pressure alone as in the case of a pleuritic effusion suffices, however. When encountered in old standing cases, as often seen on a small scale in chronic pneumonia, the alveoli are atrophied and the walls thickened (collapse induration). The fibrosis increases with the age of the atelectasis and there is usually a considerable amount of *pigmentation* due to inhaled material; this latter point is worthy of note as it serves to distinguish this form from a long standing congenital collapse. In the acute forms of atelectasis the air cells are at first capable of inflation, there is usually considerable engorgement of the vessels and signs of acute inflammation. In congenital atelectasis the lungs either fail to expand at birth and can be readily inflated, or an early fœtal atresia of a large or small bronchus may have brought about an atrophy and fibrosis of corresponding segments of lung tissue.

Bronchiectasis, emphysema and cysts.—*Bronchiectasis* may be congenital, and be associated with lung tissue which has failed to develop. Further, in congenital cases, simple and multilocular cysts lined by ciliated epithelium may be found free or in connection with the bronchi. *Bronchial dilatation* is very common in the severe forms of chronic fibrosis, the process is gradual and usually increases as the air cells become compressed and invaded by the chronic inflammatory processes. Increased work thrown upon the weakened bronchi seems to be one of the main causes. *Emphysema* or dilatation of the alveoli occurs very early in pneumonia (p. 53) and is due to the air pressure acting on the weakened walls. It is very common in the lungs of old people, and is associated with fibrosis

and atrophy. In many conditions owing to increased pressure in the alveoli, there is a very general emphysema, which makes itself felt even in the thoracic wall. The appearance of the dilated alveoli is well represented in **Figs. 19, 22, 111** and **112**; in the first three figures the emphysema is associated with chronic inflammation; in the fourth case (fig. 112), there is a slight fibrosis, and the distension of the alveoli has reached an advanced stage, *cystic* dilatation as at 2 being common; many of the air cysts measure from $\frac{1}{2}$ inch to 1 inch in diameter, and their walls are very thin, distinctly compressed and fibroid; very many of the capillaries are obliterated, and many of the larger vessels appear compressed and drawn out; there is considerable dilatation of the bronchioles. The favourite seats of emphysema are the apices and the margins of the lungs.

Compensatory hypertrophy must be carefully distinguished from the above condition, and especially from the so-called vicarious emphysema which is depicted in figures 19, 21, 22 and 111.

Embolism and Infarction.—The lung is a very favourite seat of embolism. Reference has already been made to *fat embolism* after fractures (p. 212, **Fig. 83**), and to the hæmorrhagic exudation which so frequently accompanies it, whilst on page 111 a nematode embolism is described. Thrombi formed in the right side of the heart and in the systemic veins frequently become detached and lodge in the branches of the pulmonary artery; thus a large femoral thrombus may be found rolled up in the pulmonary artery; the latter condition leads to immediate death. Smaller emboli produce wedge-shaped hæmorrhagic infarcts at the

periphery, or more diffuse hæmorrhagic foci in the interior of the lungs. If the emboli are infective, as they frequently are, wedge-shaped and focal areas of acute inflammation, and later of suppuration or gangrene result. It is, however, doubtful whether all the inflammatory and suppurating wedge-shaped areas are produced by embolism. Malignant embolism is frequent, and sometimes the emboli develop and ramify in the branches of the pulmonary artery.*

Tumours.—The records of the tumours of the lungs are not satisfactory. We have already called attention to the connective tissue and glandular hyperplasia (adenoma, adeno-sarcoma, &c.), so frequently met with in chronic pneumonias. As a rule, these hyperplasias, owing to their uniform distribution throughout the inflammatory tissue of the lung, are not recognised by the naked eye; cases, however, do occur in which the growths are more nodular, and which have in consequence been regarded as primary sarcomata or epitheliomata; in two examples of the latter type which I had an opportunity of examining, I could not separate the epithelial growth from hyperplasia. There is no doubt, however, that true glandular cancer, both diffuse and nodular, does occur in the lung, and that a frequent source is the epithelium of the bronchioles; in the case of the diffuse tumours, infiltration may occur around the bronchi or vessels. Several authors describe in the cancers, alveoli filled with cells, but it is not in all cases clear whether these are cancer alveoli in the interstitial tissue or air cells filled with epithe-

* It is perhaps worthy of note that Schmorl demonstrated giant cells and other cell forms in the lung vessels in a case of eclampsia; he considered that the former originated in the placenta.

lium; the same difficulty is also to be noted in those cases which have been recorded as secondary or even as primary squamous epitheliomata, and in which imbricating epithelial nests are found.*

Cases of *miliary lymphomata* are described which to the naked eye closely resemble miliary tuberculosis. We have already drawn attention to the *muscular hyperplasia* and the *bone formation* which may occur in chronic inflammation. Cohn has described a very interesting case of the latter and has collected others; he regards the change in his cases as an osseous metaplasia in the new perivascular tissue, and not an ossification starting from the cartilages of the bronchi, which are sources in some cases; small osseous plates may occur beneath the pleura, and isolated osteomata and chondromata are described.

Scattered references have been made to the *mediastinal tumours*, which include lymphomata (thymus), glandular tumours, complex teratomata and simple dermoid tumours. The possible origin of tumours of the hilus, bronchial glands and mediastinum from rests (which may possibly include rests of thyroid tissue) is not to be forgotten. On page 205 reference is made to hair spitting.

Tumours of the pleura occur as diffuse growths over a large extent of surface, or in a multiple form. Of the latter variety I have had an opportunity of

* See Bibliography for cases. The question has been discussed whether squamous epithelioma could originate from epithelial cells inspired in operations for cancer of the tongue. This, however, would be a very doubtful example of the already doubtful cases of *cancer by contact* (epithelial inoculation) where growths are observed on opposite sides of the larynx (Semon), and on other opposed situations.

examining two specimens, the one of Sir W. Jenner's, the other of Dr. Walsh's (Museum, U. C. L.), in both of which the pleuræ are covered with mushroom-like growths. In one case the growths appear to the naked eye to be confined to the pleura, and the history states that in addition to the pleura pulmonalis, both the parietal and mediastinal pleuræ of the same side and the *parietal of the opposite side* were affected. The growths consist of ramifying narrow solid gland acini and are found in addition around the small bronchi. In the other case the lung as well as the pleura is the seat of numerous growths consisting of encephaloid cancer. In the first case the evidence is strongly in favour of a primary growth either starting around the small bronchi or *in the pleura*;* in the second case there were growths in the brain, and lack of evidence to the contrary points to the lung tumours as the primary growths.

* It is just possible that a rest of mammary gland tissue may account for primary glandular pleural growths in some instances.

Chapter XVIII.

GENITAL ORGANS AND BREAST.

Prostate.—Thompson thus classifies the enlargements of the prostate chiefly met with in elderly men. (1) *True hypertrophy.* (2) *Fibrous* or *fibro-muscular hyperplasia:* these are the most common forms, and some gland tissue can usually be found. (3) *Glandular hyperplasia:* this variety probably corresponds to the adenoma of the prostate. (4) *Simple tumours* and *outgrowths:* this last is a very interesting group, as they very clearly resemble the interstitial and polypoid tumours of the uterus. The interstitial forms are encapsuled, readily enucleated, often multiple, and are most frequently found in an hypertrophied prostate; they may consist of all the elements of prostatic tissue or of fibrous tissue alone. Together with the polypoid formations may be classed the accessory prostates or prostatic rests occasionally found (Rokitansky, Paget) in the vicinity of the main mass. According to Thompson, gland tissue can usually be discovered in the polypi in addition to the other elements.

Cystic (marked) dilatation of the gland crypts is doubted, but Englisch states that a cyst may form in the remains of Müller's duct. Malignant adenoma (Ziegler), schirroid, encephaloid and colloid (Museum, U. C. L., Boyd's case) cancers are forms of malignant disease occasionally encountered primarily in the prostate.

Prostatic concretions—the corpora amylacea—have

been carefully described by Thompson and Stilling. They appear to be formed either by hyaline transformation of desquamated epithelial cells, or by the secretion of a hyaline substance around epithelial cells. The ubiquitous giant cell is described around them in many cases by Stilling. They may be very abundant—"snuff grains"—and may form the starting point of calcification and the formation of calculi. *Prostatic calculi* are often very numerous, and in their growth distend the follicles in which they are formed, and cause the atrophy and disappearance of intervening septa.

Chronic prostatitis may remain from an acute attack or be due to tubercular disease. In old people and in chronic inflammation, a hyaline transformation may take place around the ducts (*myxangioitis hyalinosa*, Recklinghausen and Stilling); it appears akin to the peculiar hyaline and myxomatous changes which we have had and will have occasion to observe around atrophied gland acini.

COWPER'S GLANDS, like the prostatic, are appendages of the sexual apparatus, and appear to be influenced equally with them. Cystic dilatation is recorded.

PENIS AND URETHRA.—At the seat of a *stricture*, small round celled infiltration, formation of dense fibrous tissue, epithelial hyperplasia, stratification and cornification (p. 158 and Neelsen, Posner, Dittel), may all be observed. In connection with the prepuce, there have been described, cholesteatomata (p. 166), stones (p. 96), sebaceous cysts and adenomata. The hard and soft sores have already been dealt with. Niehus describes in what appeared to be chronic inflammation of the glans, a small round celled infiltration, connective

tissue hyperplasia and contraction, and a spreading epithelioma; the glans was indurated, the cavernous spaces atrophied or obliterated, and the meatus almost closed. The epithelioma is worthy of note as apparently an example of an *atrophic* squamous cancer. Cavernous endotheliomata have been described (*see* ref., p. 169).

Testis.—On pages 183 and 184 a short account of testicular cysts is given and references made to the origin of testicular dermoids. With regard to spermatic cysts it may be added that Roth traces them to the retention of fluid in congenital vasa aberrantia. Silcock describes a progressive cystic dilatation of the tubules. Eve has examined a large number of cysts, including cysto-fibromata (adeno-fibroma), sarcomata, myxomata and carcinomata; they were lined by columnar, stratified or ciliated epithelium; some were papillomatous, and cartilage and smooth muscular fibres were occasionally present in the stroma. The adeno-myxomata were characterised by slit-like tubes or solid rods of gland tissue surrounded by a zone of transparent tissue, and the author compares them to similar tumours in the breast (*see* Breast). The malignant tumours are chiefly encephaloid and scirrhoid; in a case of epithelioma of the testis, Ziegler records an associated cystic proliferation and cartilage formation in the epididymis. Lympho-sarcomata are described. Both *cartilage* and *striated muscular* fibres have been often recorded in the testis, and a rhabdomyoma may reach a very large size (*see* pp. 201 and myomata of vagina, &c.).

Both *orchitis* and *epididymitis* are common, and the chronic inflammation frequently leads to induration

and atrophy. A hyaline transformation may take place around the atrophied tubules.

Reference has already been made to tubercle and syphilis of the testicle, in both conditions there is a very complete destruction of the glandular tissue of the testis, and I have not observed glandular hyperplasia. In tubercle, giant cells or rather giant cell formations may be encountered in the cavities of the tubules, and they often attain great lengths (Taylor, myself) ; similar formations are recorded by Arnold in other gland tubules in chronic inflammatory states. In a cystic tumour of the testis, I had occasion to observe numerous giant cell forms and irregularly laminated concentric bodies.

Ovary.—Reference has been made on pp. 182 and 183 to various cysts of the ovary, on p. 205 to ovarian dermoids, and on pp. 183, 184 and 200 to ovarian rests. Accessory ovaries like the majority of accessory prostates appear rarely to be completely separated from the main mass. In addition to follicular dropsy (cystic dilatation), Ziegler applies the term follicular hypertrophy when an ovary is enlarged through hypertrophy of the follicles; the term may thus include the so-called "ovary in excessive growth" (*see* p. 182 and Bibliography).*

Amongst the other solid tumours of the ovary may be mentioned fibromata, sarcomata, myxomata, leiomata, epitheliomata and papillomata.

* Doran describes a case of "hyperplasia of the entire embryonic tissue of the oophoron," rudamentary follicles and cysts being present. The tumours appear analogous to the myosarcomata of the uterus and vagina and might therefore be described as oosarcomata.

Between the fibrous and sarcomatous tumours (chiefly spindle-celled) there is no line, and the two forms may affect both ovaries; smooth muscular fibres and myxomatous changes are frequently present. The myomata and fibromyomata are not limited to the ovary but are also found in the ligaments of the ovary and uterus. In marked contrast to the testis the presence of cartilage or of striated muscle tumours appears very rare.*

Under the somewhat misleading name of *corpora fibrosa*, Patenko describes a very interesting hyaline transformation† which in the case of small follicles is limited to their *membrana propria* (covered by lymphatic-like endothelium), but in the case of ripe follicles also occurs in the new connective tissue around the follicle. The process is associated with a quite similar hyaline transformation in the intima of the vessels which leads to their complete occlusion. The change is different from that seen in the normal scar of a follicle in that in the latter case absorption takes place, whilst in the former the hyaline material remains.

Papillomata and *carcinomata* may affect the ovaries and tubes together; the carcinomata may be quite atypical; on the other hand typical hollow gland-like epitheliomata are described with sarcomatous or myxomatous stroma, and from which to the more gland-like cystic tumours of the ovary there appears no gap. "Brain sand" like *concretions* has been described in carcinomata (ref. alg. Path., Ziegler's), and hard

* At least I have been unable to collect much literature on the subject. Virchow describes a striated tumour.

† Interesting because we have reason to believe that the change is a very general one.

brown wax-like concretions in an otherwise normal ovary.

In the Fallopian tubes various forms of *salpingitis* have been described (catarrhal, follicular, purulent, hydrosalpynx, &c.). In the catarrhal form small round celled infiltration, connective tissue, sometimes muscular and glandular hyperplasia occurs. The folds of the mucous membrane may fuse and lead to the formation of cysts (Orthmann). Muscular hypertrophy from partial stenosis is recorded.

Uterus and vagina.—As in the case of other mucous surfaces there are several varieties of *endometritis* or inflammation of the uterine mucous membrane. Amongst the severer forms may be mentioned the croupous and diphtheritic (with superficial and deep necrosis), also the formation of sloughs and extensive ulceration. Frequently the inflammatory reaction spreads into the uterine wall along the perivascular lymphatics, and a very extensive small round-celled or purulent interfascicular infiltration results; the inflammation may even spread to the serous surface.

As we have had occasion to emphasize over and over again, great attention must be given to the chronic inflammatory processes owing to their close relationship to the malignant tumours. There are various forms of *chronic endometritis*, viz., *catarrhal*, *follicular*, *villous*, *fungoid*, *polypoid*, *exfoliative* and *ulcerative*, terms which are sufficient to indicate that hyperplasia plays no inconsiderable part. Commonly there is a muco-purulent discharge and a small portion of curetted membrane might be found swollen and infiltrated with small round cells; the surface epithelium, and that lining the glands might also show evidence of pro-

liferation and desquamation, whilst a few of the glands might be cystic. In other cases the covering epithelium may disappear and expose a very vascular and corpuscular granulation tissue. Or the surface may be beset with vascular villous projections covered by gland epithelium, whilst deep in the wall of the uterus the gland acini may show signs of proliferation; some of the acini may be cystic. This last described condition is often spoken of as an adenoma or adeno-papilloma, and may spread from the interior of the cervix on to the portio vaginalis where it appears to replace the squamous epithelium; in some cases, however, it is probable that the superficial layers of the flattened epithelium desquamate and expose the layer of columnar cells. An extending chronic inflammatory process on the cervix like the preceding or like any of the forms mentioned under endometritis is called a cervical *erosion*.

As noted on page 157 under *psoriasis* of mucous membranes, there are cases in which the mucous membrane of the vagina and uterus assumes a horny dermoid character. John Williams and Küstner have observed stratification of uterine polypi (compare nasal and other polypi);* the former observer also describes stratification in glandular erosions. Later, Zeller has described stratification of the mucous membrane of the interior of the uterus, and occasionally a membrane composed of one or more layers of polygonal cells is shed.

Hyperplasia may result in the formation of polypoid, papillomatous and wart-like tumours of considerable

* Owing to the kindness of Dr. Williams, I have been able to observe these conditions (*see* note, p. 167).

size, which may consist in great part of gland tissue, cysts, connective tissue or muscle fibres; there is also evidence, however, of the formation of papillomata, adenomata and myomata quite apart from any chronic inflammatory process.

Cancer of the uterus.—Epitheliomata may arise from the stratified epithelium of the portio-vaginalis or from the glandular lining of the cervix or body of the uterus, and between the resulting growths in both cases there is a striking histological resemblance. This is readily explained, for an examination of the cancers arising from the glands shows that the first process in the growth of the tumours is in very many cases indeed a *stratification* of portion of the gland walls or surface columnar epithelium; this point is beautifully illustrated in many of John Williams' specimens (*see* "Cancer of the Uterus") and in **Fig. 66.** Further, as the glands throughout an increasing area are affected by this malignant hyperplasia, and as the process may even start at different points of the mucous surface (Williams), so numerous solid acinar masses ramify and penetrate deeply into the stroma and may even fuse. In section such a tumour may present the appearance seen in **Fig. 67,** although usually the alveoli are more cellular. When a malignant hyperplasia commences in the portio-vaginalis, large epithelial lobes and papillæ grow down from the stratified surface, and a large epithelial mass like that depicted in the very low power illustration, **Fig. 62,** results. A quite similar non-acinar tumour is formed when a portion of *columnar epithelium* free from glands becomes malignant; superficial stratification occurs, and large epithelial lobes and papillæ penetrate into the stroma

(Williams, polypus). In the tumours arising from the stratified portio, nest-like formations are occasionally encountered, and the growths sometimes assume the cauliflower form; otherwise, as mentioned above, there is a great similarity between the tumours arising either from glands or stratified membrane.

The forms of cancer which have just been described are those which we have held to be characteristic of the adult or acquired growths (*see* alimentary tract, &c.). There is, however, a typical *adenoma destruens*, **Fig. 74**, and for such a growth I would maintain a *congenital* origin. Uterine cancers may also assume the very atypical scirrhoid and encephaloid types and a tumour consisting of proliferating gland acini which partly preserve their lumen is sometimes met with. In all this there is but a repetition of what has been observed in other glandular organs.

As regards diagnosis, a small piece of curetted gland tissue which shows signs of stratification as above described, and as seen in **Fig. 66**, should be regarded as malignant. Moreover, this form of malignant proliferation must, just as in the case of psoriasis linguæ, be separated from those hyperplastic changes which end in cornification (*see* p. 161, the malignant transformation).

The *myofibromata* have been described on page 129, **Figs. 48** and **49**. Very noteworthy in figure 48 is the pale colour of the uterine stroma in comparison with that of the myoma; this is due to the muscular atrophy and the fibrosis of the uterine wall, a phenomenon frequently observed in the case of fibroids and malignant disease. With the fibro-myomata must be associated the very interesting *myosarcomata* of both the

uterus and vagina, and which may here be described together.* These latter infiltrate, recur and often assume a grape-like or polypoid form. As their name implies they consist of numerous cell-forms, of which a large spindle shape appears common to all; very characteristic and a point of great histological interest is *cross-striation* of a large proportion of the spindles and other cell forms. In seeking an explanation of the rhabdomyoma of the uterus, Pernice made sections of a five weeks fœtus and found that very many of the muscular fibres were cross-striated, and that there was in fact considerable resemblance between the cells in both cases. I am of opinion that these are typical congenital tumours developed from rests, and that they are not reversions of adult tissue to an early embryonic† type as so frequently assumed in similar cases; and I think further we can say that there are two forms of rhabdomyomata (sarcoma type as seen in the kidney, testis, uterus, vagina), one derived from rests of embryonic *involuntary tissue*, the other from rests of *voluntary fibres;* in the two cases there is evidence to show that the resulting tumours differ (just as much as embryonic voluntary and involuntary tissue), in the former case spindles are found, in the latter, very long cylindrical shaped cells. Thus we are forced to believe that these tumours are more readily explained by a *vitium primæ formationis* (Cohnheim), than on the hypothesis of a metaplasia.‡

* *See* Bibliography.

† This expression has been purposely avoided throughout the text.

Cross-striation appears very early in the animal kingdom.

‡ Against the congenital view, might be argued that chondro-

Cysts of the vagina may arise from Gärtner's ducts (p. 183), or from glands occasionally present in the mucous membrane. Psoriasis, papillomata, warts, epitheliomata and the rhabdomyomata described above may be included amongst the important pathological changes.

Vulva.—A scirrhoid type of squamous epithelioma seems not of very rare occurrence, the condition is seen in **Fig. 63.**

MAMMA.—The following remarks are intended to serve as outlines of a basis of classification of tumours generally; they are introduced here because the examples whereby they are illustrated have now increased, and because the breast affords numerous further striking illustrations.

Already on pages 135 and 136, and again on pages 173 and 174, reference has been made to the numerous varieties of mammary tumours, to wit, the fibro-adenoma, cystic fibroma, intra-cystic tumours, intra-canalicular fibro-adenoma, fibro-myxoma, myxo-adenoma and adeno-sarcoma; finally to the acinous, tubular, intra-cystic glandular and other malignant epitheliomata. From these references it may be gathered that there are three categories, one in which there are marked stroma changes, another in which the stroma and gland changes appear equally divided, and a third in which the epithelial changes are distinctly the most important. In reviewing these three

sarcomata are described in the cervix (Thiede and Rein, ref. Pernice). On the other hand, Kolessnikow describes a *pigmented rhabdomyoma* in the horse which might have been vaginal in origin (compare case of melanotic sarcoma in anal region of horse, by B. Sutton, "Pathology").

divisions we must bring into consideration certain facts, and the deductions from these facts, which have from time to time appeared in the course of this work. For instance, the importance of accessory gland and other structures (rests) has been insisted upon on pages 159, 173, 198, &c.; also the fact that in very many tumours the stroma and the gland element develop hand in hand, and that the *peri-acinous tissue* is in effect highly specialised, and should always be considered with the epithelial elements. This latter point was emphasized in the case of dermoid cysts, where it was pointed out that quite as much importance was to be attached to the connective tissue as to the epithelial lining. In making a large number of sections of diseased acinous glands, one cannot fail to be struck with the clearness with which the periacinous tissue frequently becomes differentiated from the surrounding connective tissue of the body (the skeletal tissue); this will be rendered clearer further on. We have suggested that it may be possible to divide tumours into those of a congenital and those of an acquired type. For we have not failed to notice how tumours which arise from accessory structures (rests) possess characters of their own, such for instance as a stroma which is quite different from an inflammatory connective tissue hyperplasia, does *not tend to contract*, and in its rapidly growing form is spoken of as sarcomatous; and epithelial structures, which, to take the case of acini, are regular, bear a definite relationship to the stroma and are not like acini the seat of inflammatory hyperplasia. The close relationship of epithelial hyperplasia (inflammatory) to certain types of cancer, and

of both conditions to "irritative" processes, has been over and over again referred to in the text, and sufficient evidence has accumulated to show that such growths are acquired. The hyperplasia, it will have been noted, appeared in many instances to be an adaptation to altered circumstances (implied in the "irritation"); of such a nature it has been argued may be the stratification and cornification of an epithelial surface and the formation of scar tissue. The dermoid metamorphosis it will also have been observed occurred quite irrespective of an ecto-, endo- or mesodermic origin.* It was seen how the epithelial hyperplasia in many instances appeared to alter its nature, taking on certain characters termed malignant (p. 161) and no longer serving any useful purpose. The common types of cancer which we have held characteristic of this origin are figured in numbers 63, 65, 66, 67, 70, 71, 72 and 73, and the terms which have been chiefly used to designate them have been acinous, scirrhoid and encephaloid. If it has thus been possible to trace epithelial hyperplasia to malignancy, it is probable that the same may be done in the case of connective tissue or indeed of other tissues. Connective tissue hyperplasia is a very common phenomenon, and usually ends in contraction and sclerosis (compare cornification); moreover it is regarded as the change especially due to chronic irritative lesions, it is an acquired change and a reaction in adult tissue. But

* Naturally a normally stratified surface (*i.e.*, the skin) will in hyperplasia show more marked stratification, cornification and differentiation generally, than a membrane normally covered by serous or columnar epithelium. This metamorphosis implies no metaplasia.

there appears to be very strong evidence of hyperplasia, in long standing cases of chronic inflammation, assuming something more than a mere protective reaction, in fact of becoming malignant (note the papillo-sarcomata of the lung, granuloma fungoides, &c.). The resulting growth would be termed a sarcoma, an acquired sarcoma we will provisionally call it, for a large number of the sarcomata as will be shown appear to be truly congenital.

There are benign cellular fibroid growths which do not resemble the tissue of an inflammatory hyperplasia* and exhibit no tendency to contract; moreover, the stroma passes in many instances imperceptibly into the sarcomatous, and evidence has been brought forward in the text to connect them with congenital rests. We may then perhaps be justified if for the latter we employ the terms congenital or embryonic, and for the former acquired or adult.

In the chapter on Tumours we insisted upon a difference between congenital and acquired epithelial warts and other structures. To take the congenital warts: one may very often observe a *striking* difference between the epithelial and the fibrous elements of the wart and those of the surrounding epithelium and connective tissue; note, for example, *pigmentation*, *formation of hairs*, abundant *formation of horny nests*, and a *very cellular stroma* (not of the nature of a small round-celled infiltration). The acquired warts, in the production of which chronic irritative processes play such an

* Although their growth undoubtedly may be influenced by "irritation," there are other very important exciting causes of the nature of those which operate say at puberty or the menopause, &c.

important part, differ entirely from these.* There is an equally striking difference between benign congenital and acquired glandular growths; in the former case, as stated above, the glands tend to be regular, and are usually lined by a secreting epithelium which has very often a definite character of its own, (presence of cilia, presence of a secretion); in the case of hyperplasia the epithelial growth is often irregular and the character of the epithelium altered, but never in the sense that it might acquire cilia.† Moreover we direct especial attention to the fact that just as in the case of the congenital wart, the *stroma in the benign gland tumour possesses characters of its own*, which in numerous instances sharply separate it from the skeletal tissue. In the acquired benign growths this differentiation of the sub-epithelial or periacinous tissue comes out by no means so strongly.

Corresponding to the adult and embryonic benign epithelial growths are adult and embryonic malignant epithelial tumours. Concerning the malignant embryonic tumours;—in the commencement of my investigation of morbid growths I was struck by the fact that there were certain squamous epitheliomata which possessed an epithelium and stroma of their own; in the epithelium an absence perhaps of the prickle processes and an abundant development of peculiar horny nests, in the stroma an *encapsulation* from the general

* Note, for example, the formation of exaggerated prickles and of *cellular* nests.

† Although curiously enough, it is in these cases that the expression "reversion to an embryonic type" is spoken of. The contrary is the case, witness, for example, increased development of prickles and cornification.

connective tissue. Such a tumour appeared to spring from one minute point, and I often failed to demonstrate any connection between it and the surface epithelium. In the enamel germ tumours I was equally impressed with the differentiation of the *stroma* and the epithelium; the former in many cases could as readily be distinguished from the general connective tissue as the epithelium—they were *encapsuled*.*

Another fact may also be noted, namely the imperceptible transition between the benign and malignant forms, just as in the case of the benign and malignant embryonic connective tissue tumours.

We have mentioned that in some tumours the gland and stroma tissue may develop hand in hand, that the periacinous tissue may become sharply defined from the general fibrous tissue, and that these differences are most marked in those tumours which we had every reason to believe develop from accessory structures. Figures 52 and 77 will serve to illustrate this variety, the former is from the breast, the latter from the ovary; it is a very common form of tumour, and may be termed the embryonic or *congenital fibro-adenoma*. Between these tumours and embryonic adeno-sarcomata and the so-called typical columnar epitheliomata (malignant adenomata) there is no sharp line. And just as in certain multiple neuromata, all transitions are observed from the encapsuled to the diffuse spreading condition, known as elephantiasis neuromatosa, so in the sarcomatous varieties of the above a diffuse form may, in the breast for example, produce an elephantiasis (Virchow); similarly the

* I have up to the present unfortunately been unable to obtain any specimen of branchiogenous carcinoma.

stroma of an ovarian tumour may spread diffusely into the pedicle and involve surrounding structures. The stroma of the congenital tumours may thus grow in excess of the epithelial element Further, we have referred to the congenital epithelial wart, but we might also have referred to certain fibromata and sarcomata developing from moles, which possess characters of their own and are often *pigmented*. In the breast certain fibromata and sarcomata are found, which, if we can trust microscopical appearances are similar in structure to the periacinous fibroid and sarcomatous tissue in the case of the mixed tumours.* On the other hand, the gland increase may be very striking. It assumes several forms, of which we consider one to be of the type of the malignant adenoma represented in figure 74, taken from the uterus; further examples occur in the ovary, breasts, and in other glands; the acini may be solid, but as far as my researches lead me at present the type of a gland is closely preserved; for their identification I would in addition lay great stress upon the appearance of the periacinous tissue.

To turn to the acquired or adult tumours, we learn that one of the most striking features about them is the prominence of the epithelial changes; so much so is this the case that it is usual to lay little stress upon the stroma changes. We have, however, repeatedly directed attention in the case of epithelial hyperplasias

* This question of the differentiation of the peri-glandular tissue and the formation of peri-glandular fibromata with an increasing disappearance of the glandular element opens up the question of the nature of a very large number of connective tissue tumours, amongst which may be even included the fibro-myomata of the uterus.

to the granulation tissue appearance of the stroma, and we have mentioned that the connective tissue increase may assume considerable dimensions (certain polypi). Great stress must now be laid on the fact that apart from any very marked small round celled infiltration which may be present, and some usually is, no sharp encapsulation exists, and the tissue of the neoplasm, be it sub-epidermic or periacinous, does not strike us as differing very greatly from the general fibrous tissue; it may be found dense and hyaline. In the malignant varieties and especially in the slow growing forms as scirrhus, certain squamous epitheliomata, &c., a very pronounced contraction and often hyaline transformation of the stroma follows upon the small round celled proliferation or even takes place imperceptibly without any noticeable increase in small round cells. This formation of scar tissue, sclerosis or hyaline change, we know to be a common property of any adult connective tissue, and further, that the production of these conditions appears greatly influenced by all those causes which are classed under irritation and senile decay. At the present it seems possible only in a limited number of instances to separate the connective tissue changes which start in the periacinous from those occurring in the common fibrous tissue around, they appear to pass imperceptibly from the one to the other. There is as fundamental a difference between the periacinous tissue of the acquired growth and that of the embryonic as there exists between the epithelial elements in the two instances. A wide difference in their time of production will, we think, account for these peculiarities.

There are benign gland tumours, the microscopic

appearances of which do not warrant us in assuming an early congenital origin, and in the history of which prolonged irritation has not been signaled. The connectitive tissue is often coarsely fibrous, and cystic and intracystic growths may be present. It is quite possible that in some cases the connection of an acinous or lobule with the rest of the gland may have become severed, and that the isolated portion has then given rise to a tumour. The process may perhaps be illustrated in the case of the amputation neuroma. Many of them are simple hyperplasias.

From time to time attention has been called to hyaline changes in the tissue surrounding gland acini. In making a series of sections of acinous glands, and especially of the breast, one cannot fail to be struck, that as the result of atrophy or senile decay, the peri-acinous tissue may become more strongly differentiated from the skeletal fibrous tissue, it appears more refractive and is very often hyaline. On several occasions in the breast I have had an opportunity of observing a most complete *peri-canalicular hyaline transformation*, the acini appearing converted into branching and lobed thick hyaline cylinders, whilst the vessel walls were often similarly affected. The change appeared in some cases to commence in the ground-substance immediately adjacent to the epithelial lining. This observation reminds us of those of Patenko concerning the corpora fibrosa of the ovary (p. 346) and those of Jüngst who describes an intra-canalicular myxoma of the breast, in which there were most marked hyaline changes and the vessels were also affected. Neumann and others also describe periacinous hyaline changes in the breast, and it seems highly probable that the

cylindromata generally must be reckoned in this group. Further, the hyaline adenomata appear to have strong affinities with the *myxomatous* tumours (Jüngst's case), and these as we know form some of the most typical pericanalicular growths. Still more important is the relationship which they bear to the remarkable *colloid* tumours in which the periglandular stroma is the seat of the metamorphosis. A striking fact in the hyaloid, myxomatous and colloid tumours is that very frequently the epithelial changes are only slight, in many cases there is exceedingly little epithelium.

The above remarkable ground tissue changes are not only to be observed in periglandular tissue, we have mentioned that the vessel walls may be converted into hyaline cylinders. The hyaline transformation of the intima is an old observation, but there are cases in which what appears to be an allied metamorphosis is carried to great lengths ; thus, on more than one occasion in the text, we have referred to the colloid tumours which have been found associated with vascular growths, and in addition, cylindromatous and mucoid angio-sarcomata have also been described. Lastly, we may mention that gentian violet now and then gives a slight rosy reaction with the hyaline material, so that a relationship to amyloid is not an extravagant view. Of the same nature as the preceding hyaline changes, is probably the hyaline transformation which has already been noted immediately beneath the endothelium of Bowman's capsules in the kidney and in the glomerulus itself.

What we desire to emphasize in the preceding paragraph is that periacinous or perivascular* tissue in

* In this term we include the vessel wall.

cases of atrophy, senile decay, cachexia (including the cases accompanied by suppuration), but especially in neoplasms, may be the seat of the remarkable changes described as myxomatous, hyaline, amyloid and colloid.

Stress has been laid upon the periacinous tissue as distinct from the supporting skeletal tissue. As seen elsewhere in the text it is not unusual for osseous metaplasia to occur in the *skeletal tissue* under certain circumstances, as for instance, in chronic inflammation when the vascular supply is increased. We are therefore of opinion that in the cases of ossification of the breast and other organs, it is this skeletal tissue and not the periacinous which is the seat of the metaplasia.

In accordance with the views put forward in the preceding pages we may state that there are at least three or four recognisable types of mammary tumours, viz.:—

1. *Embryonic or congenital.*—Periacinous tissue histologically distinguishable from the surrounding skeletal tissue, encapsuled. Gland acini composed of slit-like, hollow or solid branching cylinders. Cystic dilatation in some cases. Tumours sometimes multiple; often appear at a comparatively early age and may for a long period remain stationary and then commence a rapid growth. They appear in very many cases free from the gland, *e.g.*, certain adeno-fibromata, myxo-fibromata, adeno-sarcomata and cystic sarcomata, melanotic tumours,* fibromata, sarcomata (elephantiasis), peri-canalicular and intra-canalicular fibromata.†

2. *Acquired or adult.*—Connective tissue not sharply

* These are probably dermato-fibromata and derived from the areola.

† In the intra-canalicular fibromata the glandular epithelium merely takes the place of an epithelial investment comparable to the endothelium of the peritoneum.

differentiated, very frequently infiltrated with small round cells; and tending to contract. Epithelial proliferation, stratification, formation of cysts and intracystic papillomata. Changes associated with chronic inflammatory processes, *e.g.*, *hyperplasias*, which may occur in the form of diffuse or fairly circumscribed indurations. These pass to the *malignant epithelial tumours*, in which the fibrous tissue very often exhibits a marked tendency to contract, and is infiltrated, whilst solid epithelial acini or irregular epithelial alveoli, consisting of very few or very many cells are formed, *e.g.*, acinous cancer, figures 70 and 71, scirrhoid, figure 72, and encephaloid, figure 73.

In a sub-division of the acquired tumours may be placed those in which there is no evidence histologically or otherwise of chronic irritation. For some of these we have already assumed (*see* above) an accidental origin such as the blocking of a duct; many appear to be simple hyperplasias.

3. Tumours in which the connective tissue is the seat of progressive *hyaline*, *mucoid* or *colloid* changes.

4. Tumours arising in the extra-acinous tissues, namely, fatty, vascular, osseous, cartilaginous and muscular. These may be congenital or acquired.

According to Billroth's and Schmidt's analyses of mammary tumours, 82 per cent. are carcinomata, and the majority of observers are agreed that in the production of this extremely large percentage of cancer, *mastitis* has a most important influence, (thus Schmidt and Schulthess in their very large analyses). The nature of the precancerous changes has engaged the attention of Mr. Raymond Johnson, and recently and

independently that of Mr. Beadles.* Both describe stratification of the large ducts and connective tissue induration in chronic mastitis, and in cases of cancer associated epithelial proliferative, atrophic and cystic changes in other portions of the mammary gland. Agreeing with this the malignant change may occur at more than one spot. In conjunction with these observations may be taken those of Paget, who has described cancer following upon irritative psoriatic and malignant epithelial changes of the nipple and areola ("Paget's Disease of the Nipple").†

Of 3,329 cases of mammary carcinomata analysed by Schulthess, 47 only occurred in men. The common type is scirrhus.

Schuchardt has brought together some 406 cases of tumours of the male breast. Amongst these there are numerous cases of fibromata and cystic and adeno-fibromata; in many cases the tumours appeared about puberty. In connection with this last point may be mentioned that there are very numerous cases of mastitis in the male at the age of puberty (mastitis pubescentium virilis).

* The conclusions of both these gentlemen are in process of publication. I am greatly indebted for the kindness with which both have communicated to me their results and shown me their numerous specimens.

† In the case of mammary tumours, a secretion from the nipple has long been recognised (Richard, "Mémoire sur un symptome négligé de certaines tumeurs du sein," *Journal de Malgaine*, 1852), but has been considered by different observers to be diagnostic of cystic or malignant states respectively.

Kocher in V.A., 73, 1878, describes a very interesting "*mastitis carcinomatosa*," with eczema of the nipple, &c. A secondary growth was found in an axillary gland before the malignant nature of the chronic mastitis became pronounced.

Chapter XIX.

MUSCULAR AND NERVOUS SYSTEMS.

Muscular System.

As numerous references have already been made to this system, a summary will here suffice.

Regeneration of muscle fibres occurs in wounds of striated, unstriated and cardiac fibres. In Chap. V., in connection with the subject of wounds of muscle, two forms of giant cells were described, the one probably phagocytic, the other, muscle cell monstrosities. The outgrowths described by Neumann on regenerating muscle fibres, and which consisted in the first place of unstriated multi-nucleated protoplasm, later of striated, may have been of the nature of either of the above forms.

Inflammatory hyperplasia, especially of the smooth muscular fibres, is common, and has been described on several occasions (*see* Lung, p. 330); in certain instances (uterus) polypi may be formed. In the voluntary and cardiac muscles, proliferation of the muscle nuclei may readily be observed.

In the horse, Pütz describes a very interesting case of fibroid pseudo-hypertrophy induced by the irritation of psorospermial tubes (Miescher's tubes, Rainey's corpuscles) within the muscle fibres; trichinæ may also cause a small round celled proliferation and subsequent fibrosis.

Hypertrophy and *hyperplasia* may be brought about

by increased function. In the case of hollow organs (alimentary canal, ureters, bladder, tubes, &c.), partial obstruction may lead to a very pronounced annular, diffuse or even *one-sided* hypertrophy and hyperplasia. In this connection may be taken the hypertrophy of the heart and vessels already referred to. Congenital hypertrophy of both voluntary and involuntary muscles occurs. In Thomsen's disease (Erb), hypertrophy of the muscle fibres is described in addition to other changes (*see* below). In some cases of hypertrophy (Auerbach) the size of the fibres may be increased two- or three-fold.

Atrophy and *degeneration*.—Atrophy both of striated and unstriated muscular fibres is a striking phenomenon. It has been referred to under the heart (**Fig. 85**), and under the vessels (figs. 87 and 88). Disuse is a frequent cause (*e.g.*, the intestine in cases of artificial anus); it also occurs as a senile change. Pressure atrophy is observed in cases of complete obstruction of all hollow muscular viscera; it is also seen in cases of invading tumours of all kinds, or when the stroma of the muscle is the seat of connective tissue, fatty or bony overgrowth. Division of the tendon (disuse) leads according to Krauss and others to atrophy of the muscular fibres, increase of the muscle nuclei, hyaline degeneration and connective tissue overgrowth. Division of the muscle nerve (Vulpian, Krauss and numerous others) leads to similar degenerative changes, and as we know, a large number of muscular atrophies are bound up with lesions, either of the peripheral nerves or nerve centres (lead, alcoholic, diphtheritic and other neurites, progressive muscular atrophy, anterior polio-myelitis,

syringomyelia, glosso-labial laryngeal paralysis, &c.). In these so-called neuropathic atrophies, the muscular fibres atrophy, may become longitudinally striated, and may show hyaline, granular or fatty changes ; rows of proliferating muscle nuclei are somewhat characteristic, a fact to which attention has already been drawn. There is a progressive fibrosis and occasionally an excessive overgrowth of the interstitial fatty tissue, as in pseudo-hypertrophic paralysis. This last named disease is usually regarded as a myopathic atrophy,* and has for its chief characteristic an abundant overgrowth of fat. Some observers (Schultze, Gowers, &c.) lay stress on a difference between the atrophy of the muscular fibres in this disease and in the previously mentioned group. Thus there is an absence of the chains of muscle nuclei and of any marked degeneration — apart from atrophy — in the fibre. Gowers compares the appearance to that of a myolipoma, and it may be added that it also resembles the myolipomatous tissue which replaces the normal muscle tissue in certain fœtal monstrosities, and which, moreover, is sometimes associated with malformation of the cord. There is a great deal in favour of a congenital origin. The fatty overgrowth may be very marked, and this has given rise to the term, lipomatosis luxurians ; indeed in some cases it

* Authorities are not agreed over the division into neuro- and myopathic, as in some cases of what appeared to be pseudo-hypertrophic paralysis, there were changes in the central nervous system. Dähnhardt, Bramwell, Eulenberg, Barth and others describe cases in which nerve changes were either proved or strongly suspected. On the other hand, Charcot says that fatty overgrowth may take place in cases of progressive muscular atrophies.

seems possible to regard the condition as a congenital fatty neoplasm.

Apart from the subject of atrophy, the degenerations of the muscle substance have been made the subject of numerous investigations of which those of Zenker on the granular and hyaline changes in cases of typhoid early attracted attention. Hyaline metamorphosis both of striated and unstriated (Benecke) fibres is as we now know common in wounds, severe fevers and senile states. Fatty degeneration (fig. 28), and increased pigmentation has already been described. We would especially here draw attention to the large quantity of *glycogen* and the *melanin* which is to be found in many of the congenital myomata. In Thomsen's disease vacuolation and irregularities of the fibres are described. Both hyaline (Klebs) and amyloid degeneration (Ziegler) have been observed in the stroma causing atrophy of muscle fibres.

Osseous metaplasia is a very striking change which may occur in the inter-muscular tissue; it has been referred to under "exercise bones" and myositis ossificans.* *Fatty hyperplasia* results in the lower animals from overfeeding and the irritation of parasites. It is seen in the cardiac muscle and as above described in muscular atrophies.

The *tumours* of muscles must be divided into those which arise from the muscle and the peri-muscular tissue (the perimysium), and those which arise in the latter and in the general skeletal tissue which penetrates into the muscle; to the latter category belong

* Thus bone formation occurs in the periosteum, tendons, inter-muscular septa, aponeuroses, and the skeletal fibrous tissue generally.

osteomata, fibromata, sarcomata, myxomata, lipomata, and nævoid growths; to the former the rhabdo- and leiomyomata. A very large proportion are congenital growths, the hyperplasias (inflammatory) appearing to be the chief representatives of the acquired forms. Congenital polypoid myomata occur in the alimentary canal, bile duct, pelvis and ureter, and in the vagina and uterus: myomata likewise occur in the kidney, ovary, testis, skin (dermatomyomata), and in vascular and lymphatic tumours; in these situations as already discussed (p. 351), they may be striated or unstriated, and may remain circumscribed (myofibromata) or spread rapidly (myosarcomata).

Nervous System.

Perhaps no system so clearly demonstrates, as does the nervous, the utility of a proper appreciation of tissue development. The history of syringomyelia will serve as one small instance of this, and other equally striking examples will be brought forward in the text. For this appreciation of tissue development it is not necessary to go back to the time when the embryo consisted of its three or four germinal layers, and still less to the remote period when in a primitive ancestor the neural canal might have served as a digestive sac. Nevertheless this has been and is still done, and diseases and neoplasms are sometimes referred to the epiblast, mesoblast, or hypoblast, and comparisons have actually been drawn between the tumours of the neural canal and those of the alimentary tract. On the contrary, the evidence which has been adduced in the preceding chapters directs our attention to those periods

in the life of the individual at which a differentiation of tissue occurs for a definite purpose or *function*. The most important period, and that with which we are mostly concerned at present, is probably that at which the individuality and immutability of say the sarcoblast, neuroblast or hepatoblast asserted itself. It was at this period, as Cohnheim stated, that the "fault" or "irregularity" would be found which gave rise to the subsequent tumour. It should, however, be borne in mind that in a general consideration of ætiological factors, attention should not be limited to the embryonic period only; for it is quite possible that "faults" and "irregularities" may happen in those tissue systems which, in the fœtus, at birth, or at puberty, undergo further change.*

At first the neural canal consists of a solid wall of epithelial cells; at a later period differentiation occurs into a supporting meshwork (myelospongium), consisting of branched *spongioblasts*;† the myelospongium represents the neuroglia and spider cells of the adult nerve tissue. The cells immediately lining the canal become columnar and later ciliated. Whilst this differ-

* For the terms "faults" and "irregularities" the word *failure* may be momentarily substituted. We may then consider failures of the sarcoblasts to form muscle fibres, and of neuroblasts to produce nerve cells, and of their remaining as *rests* till some force calls them to activity, when a rhabdomyoma or neuroma results. Similarly we may regard the involution of certain *organs* (rests), such as the thymus, pituitary body and pineal gland, certain male sexual organs in the female and female organs in the male, as likewise *failures* which later may be called into neoplastic activity.

† It will be observed that this branching of epithelial cells is not an isolated peculiarity, but may also be seen in the enamel organs and enamel germ tumours.

entiation of a supporting framework is taking place, the essential elements or *neuroblasts* make their appearance. These appear to be actively growing cells whose progenitors at least, the so-called germinal cells of His, exhibit the phenomenon of *karyokinesis*. For reasons which will be soon brought forward, Balfour's descriptions and figures will be followed in regarding the peripheral nerves as formed by neuroblastic cell outgrowths from the central system.

A differentiation of neuroblasts occurs throughout the nervous system into ganglion and conducting cells. Both these cell forms are characterised by the formation of processes which fuse with one another. The conducting cells acquire sheaths of greater or less thickness, and are known as the medullated and non-medullated fibres.*

Whilst the above changes are taking place, two important events occur: one is that the nerve tissue (cord and brain) becomes invaded by vessels; the other that the connective tissue around the central nervous system and the peripheral nerves becomes specialised into the tissue which forms the nerve sheaths—dura mater, arachnoid, pia mater, epi-, peri- and endoneurium. As His has pointed out the vascular invasion marks an epoch in the history of the nervous system, whilst in the Paccinian and some tactile corpuscles the differentiation of the connective tissue attains its height. In the peripheral nerves the connective tissue (endoneurium) surrounds each individual nerve fibre, but this is not the case in the cord or brain; in these the supporting connective tissue is supplanted by the

* The ganglion cells of the post roots it will be remembered also possess a sheath.

neuroglia. Processes of pia mater are, however, carried in with the vessels, but both the vessels and the sheaths of pia mater, where present, appear marked off from the nerve tissue ;* the differentiation is well seen in the case of the perivascular sheaths. In addition to processes of the pia mater, it is highly probable that foreign tissue elements, like fat, may be carried in.

It is still very difficult with the reagents at our disposal to accurately study the pathological changes in the nervous system.† To demonstrate nerve tract degeneration it is customary to employ blue black, osmic acid, carmine, indigo-carmine, Weigert's and Pal's methods; but inasmuch as the colour reactions of these reagents differ so widely from that of hæmatoxylin, we would strongly urge upon the necessity of also staining with the latter; sections stained respectively with blue black and hæmatoxylin are very different in appearance. It is further advisable to use chemical tests, such as acetic acid, in order when possible to differentiate connective tissue from neuroglia.

Changes in the Peripheral Nerve Fibres after Section.

Owing to recent researches it is necessary to supplement the account of nerve degeneration and repair given on p. 68. Thus there appears very much in favour of the views of Büngner, who re-

* Ranvier teaches that the processes of the pia mater and the vessels are surrounded by a sheath of neuroglia. It is very difficult, however, to say where the connective tissue ends and the neuroglia commences.

† But *see* Weigert in the "Anatomischer Anzeiger," 1890.

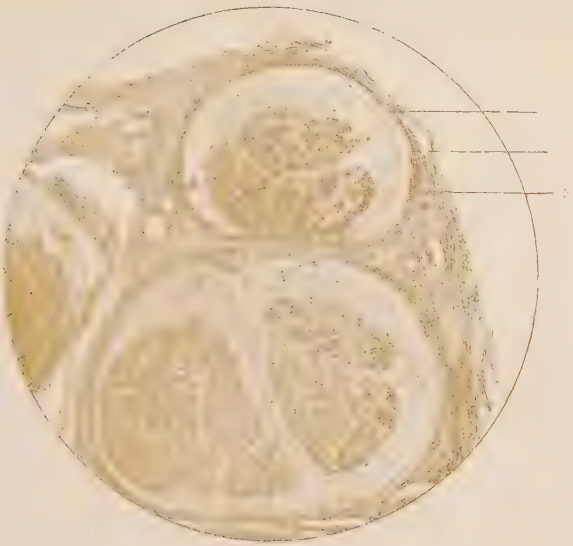

Fig. 113. NEURITIS (ALCOHOLIC).
(Anterior tibial nerve).

1. Epineurium. 2 Perineurium. 3. Endoneurium.
There is marked atrophy of the nerve fibres and overgrowth of the peri- and endoneural tissue.

Obj. 1½ in., without eyepiece. (Osmic acid).

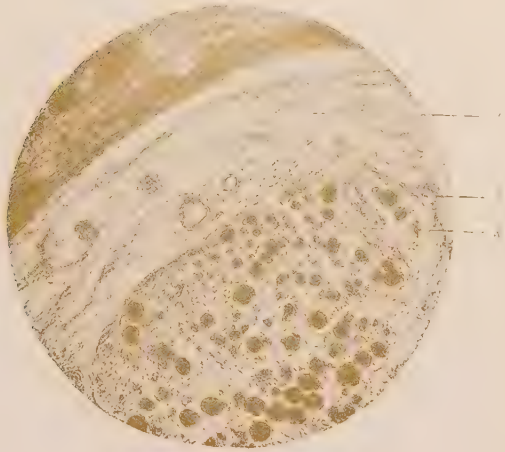

Fig. 114. PART OF 113 MORE HIGHLY MAGNIFIED

1 and 3. The overgrown peri- or endoneurium.
2. A medullated fibre, of which there are very few, most having undergone atrophy or being swollen.

Obj. ⅛ in., without eyepiece.

gards the nuclei and protoplasm of the sheaths of Schwann as *neuroblasts*. His results may be thus summarised. After section, degeneration occurs in the central end, in the portion nearest the wound and in all the peripheral ends, diminishing in intensity however towards the periphery. The medullary sheath breaks up in consequence of the shrinking and changes in the fibres, but it does not undergo fatty degeneration, being afterwards utilised in the formation of new sheaths. Regeneration commences about the third day and is marked by karyomitosis of the nuclei of the sheath of Schwann and by increase of protoplasm; the proliferating nuclei arrange themselves longitudinally, the protoplasm around them increases and fibrillates and fuses with that of adjacent segments; in this manner long axis cylinders are formed. The axis cylinders are at first rich in nuclei, later one nucleus remains for each internode; several fibres may be formed in one sheath, and the size of the new fibres varies very greatly. About the third week the medullary sheath begins to be formed. When a portion of nerve is excised, transplanted living nerve, a piece of an artery, ligature or of decalcified bone may all serve to conduct the perineural and neural cells from the one end to the other. If these views are correct, there is a striking similarity of the above changes to those recently described by Robert in wounds of muscle. Moreover, a more rational explanation is furnished of the amputation neuroma, and of those cases where in addition to a bulbous end, the nerve is enlarged for a very considerable distance (case of Hayem and Gilbert, ulnar nerve*);

* The median (central end) was in this case atrophied. On p. 69, fig. 25, it will be seen that the *distal end* of the median appears

the enlargement being due to an abundant formation of small myelinic fibres; the same may also be said for those cases of neuritis (Westphal), where numerous small fibres are present or the nuclei of the sheath of Schwann are increased (Eichorst, and *see* later). The neuroblast theory will also be found of the greatest service in the case of the neuro-fibromata.

Degeneration of Nerve Tracts in the Cords.

Secondary degeneration.—Degeneration of a tract may result from destruction or removal of the centre in the cortex, or from lesions which interrupt the tract in its course, or from division of the roots.* **Fig. 118** gives a very accurate idea of the appearance presented by a degenerated pyramidal tract, the result of partial removal of the corresponding motor area in the cortex.† The degenerated tract is more deeply stained by the blue black, this is due to an increase of the interstitial neuroglia and also to a very slight extent of the connective tissue. Under a high power it is usual to find swelling (beading) and atrophy of axis cylinders, swelling, breaking up and disappearance of the sheaths of Schwann, increase of the interstitial neuroglia and spider cells and occasionally hyaline

almost normal. Nerves like other tissues (compare muscles after division of the nerve or tendon), when *prevented from functioning* degenerate; in the case of sensory nerves the central end, and in the case of motor nerves the peripheral end, degenerates the most.

* These are spoken of as *secondary degenerations*, as opposed to *primary* when part or the whole of a nerve tract degenerates but not as a result of interruption.

† Section kindly lent me by Mr. Francis (cord taken from a case of Prof. Schäfer's, *see* "Phil. Trans.," 1888-1889).

changes. The nearer to the seat of lesion the more marked is the degeneration. It is not our intention to state here what tracts degenerate in cases of hemisection of the cord, section of posterior columns, section of posterior roots, &c., but some references will be found in the bibliography. In hemisection of the cord, the wound may be the seat of a very abundant dense connective tissue growth, apparently derived from the pia mater, which may extend for a considerable distance into the degenerating tracts.

Changes in the cord after amputation.—Various conditions have been described by different observers, such as uniform unilateral diminution of one half the cord, atrophy of posterior root zone and of the spinal ganglia, changes in Clarke's column, atrophy of anterior horn, together with the nerve cells, &c.

ATROPHY, PIGMENTATION, FATTY DEGENERATION, ETC. —*Atrophy* of the ganglion cells of the brain, spinal cord, and sympathetic, is observed under a great variety of circumstances. It may be congenital, due to pressure or disuse, or it may follow after an acute inflammation. In paralysis of the insane, the cells may show a *hyaline* atrophy (Mendel); in progressive bulbar paralysis and in chronic poliomyelitis the nerve cells may atrophy and disappear. In hydrocephalus and in hydromyelia the nerve tissue as a whole may be reduced to a very thin layer; in the former case there may be complete atrophy of the grey matter where most exposed to pressure.

Pigmentation is said to frequently accompany atrophy, and indeed pigmentation is usually regarded as indicating disuse and involution of nerve cells;* these

* Hale White regards the pigmentation of the Gasserian, len-

statements are, however, called in question. An accentuated pigmentation is normal in certain portions of the central nervous system (Obersteiner), such for example as in the substantia nigra and ferruginea. Extensive pigmentation of the arachnoid, both spinal and cerebral, has been observed occasionally in dark races (Mohnike, Virchow). Apart from colour, a very extensive *melanosis of the arachnoid* and sheaths of certain nerves, amounting almost to a *sarcomatosis*, is recorded by Virchow; and Erlitzky describes a very abundant melanosis of the spinal cord in a case of progressive paralysis. The pigment was in the latter case either free or contained in cells resembling granular corpuscles, and was most abundant in the sclerosed parts and around the vessels. This form of melanosis must be distinguished from the fatty and pigmentary degeneration of ganglion cells described by Meschede and Mendel in paralyses of the insane. Pigmentation of the nerve cells is described in the acute myelitis of hydrophobia. Lastly Tschisch states that pigmentation of nerve matter may be artificially produced in the course of hardening and preparation.

Swelling, vacuolation and fatty degeneration.—Swelling and vacuolation of nerve cells is observed in various forms of acute myelitis and in the pyramidal cells of the cortex in some cases of epilepsy (Bullen). Fatty degeneration is frequently associated with pigmentation (see above). The administration of alcohol (Afanassiew) may lead to a marked fatty degeneration of the pyramidal cells. Calcification is less frequently observed.

ticular, spinal and cardiac ganglia, as evidence that these are degenerate structures. On p. 238 reference is made to abnormal pigmentation of the semilunar ganglia.

In the medullated fibres of the brain, spinal cord, retina and peripheral nerves, degeneration is commonly marked by what has been variously termed a varicose, rosary or beaded appearance. This is due to swelling of the axis cylinder, and in transverse sections the swellings give rise to the appearance of the so-called hyaline and colloid bodies; they may also be the seat of fatty degeneration.*

Corpora amylacea.—These bodies seem of very little pathological significance. They stain blue with iodine and sulphuric acid, and have been variously derived from glia cells (Redlich), blood and connective tissue corpuscles (Woodhead), myelin (Ceci), and axis cylinders.

Acute Myelitis and Softening.

Results of compression, &c.—The effects of compression on nerve tissue have been investigated by numerous observers. The spinal cord has been subjected to pressure from outside the dura mater in order to thus eliminate irritation and inflammatory reaction. For this purpose Kahler used wax; Blumenthal, laminaria; Rosenbach, pieces of silver; and Dean, in the case of the brain, glass discs applied directly to the cortex. The results appear uniform and of the nature of a *parenchymatous myelitis*, limited for the most part to the seat of pressure. In spite of the compression of the part there is œdema or softening; the nerve fibres swell, become varicose, and ultimately disintegrate; the nerve cells swell and become vacuolated; the

* For further information see Woodhead's "Practical Pathology," and Bibliography.

meshes of the neuroglia widen, the spider cells are destroyed; some of the blood-vessels may be engorged, and there may be a small round celled infiltration; in the case of the cord, marked dilatation of the neural canal as well as small cavities, chiefly in the grey matter, have been observed by Rosenbach and others. Schmaus, in a very large analysis of *compression myelitis* in caries and of *concussion myelitis*, describes changes similar to the above. Secondary degeneration of the nerve tracts starts from the lesion, and the latter eventually becomes sclerosed owing to connective tissue and neuroglia cell overgrowth.*

Acute myelitis and encephalitis.—Under this heading are included acute inflammatory reactions, both in the spinal cord and brain, in which vascular and perivascular changes are prominent. Like in so many other instances where the latter phenomena are marked, micro-organisms or their products appear to play a considerable part. Thus acute myelitis is sometimes observed in the acute general infective processes, or as the result of spreading inflammations of the meninges; it is also seen in *hydrophobia*. In the cord, myelitis is usually spoken of as transverse, focal, diffuse or disseminated; there is also a special form which affects the anterior horns of the grey matter and is in consequence termed a *polio-myelitis*.

Fig. 120 represents under the low power the appearance of the cord in a case of *acute disseminated myelitis*, the cause of which was unknown. The affected areas stain more deeply than the surrounding parts. Under the high power the vessels are engorged and their walls

* For illustration of a case of compression myelitis (caries), see Gowers', "Spinal Cord and Nerves," p. 247.

hyaline ; there is some perivascular small round celled infiltration, the nerve fibres are degenerating and the interstitial neuroglia is swollen. The degenerative changes are in fact similar to those described above under compression myelitis, and the neural canal may be even dilated and new cavities may be formed. Proliferation of the perivascular and endothelial elements appears to take place very early and there is also enlargement and apparent increase in the number of spider cells (Dreschfeld, Gowers, myself). Spider-cell hyperplasia is likewise described by Friedmann in acute encephalitis.* Granular or Gluge's corpuscles are usually present in cases of softening, they are most probably lymphoid corpuscles. The terms "red" and "yellow softening" have been long used to designate the blood-stained appearance of the affected areas both in the brain and cord. The acute inflammatory foci as in the case of compression myelitis may eventually give place to a connective tissue and neuroglia overgrowth. Gowers further thinks that there is some evidence in favour of a new formation of nerve fibres.

A section of the cord from a case of *acute polio-myelitis* is represented in **Fig. 121,** and the appearance is highly characteristic. Both anterior horns and columns have softened and collapsed and a spreading myelitis has involved the lateral columns. The polio-myelitis may be most marked in the cervical or lumbar enlargements, or it may extend for considerable distances ; both horns may be equally affected or one in excess of the other. Vascular changes, as in acute myelitis, are prominent

* Proliferative changes are prominent phenomena in acute myelitis.

in the very early stages, congestion alone being recorded. The vessels are dilated, there is considerable leucocytic, "plasmatic" and sometimes hæmorrhagic exudation. The nerve cells and fibres swell and completely disintegrate, and the anterior horns become occupied by granular débris, plasmatic exudate,* leucocytes, large epithelioid cells and proliferating endothelial and connective tissue corpuscles.

Fig. 119 represents another special type of myelitis, namely that observed in *hydrophobia*. The most striking change is the dilatation of the vessels and the perivascular small round celled infiltration. The inflammatory reaction may be widespread. It may, corresponding with the paralysis, be most marked in the cervical or lumbar enlargements, but the medulla is in the majority of cases the seat of pronounced changes. In the brain the frontal and paracentral lobes are said to be more often affected than the other lobes. According to Schaffer, Popoff and many others, the parenchymatous changes may be very marked. These consist in swelling, vacuolation and pigmentation of the nerve cells and varicose degeneration of the axis cylinders. In some cases, as in the figure, the small round celled infiltration is extreme, at other times much less marked but with greater softening of the nerve tissue.

* The plasmatic exudate is common in all acute myelites. In poliomyelitis I have found very marked connective tissue and endothelial proliferation and an abundance of very large faintly staining epithelioid cells.

Fig. 115. SCLEROSIS OF POSTERIOR ROOT ZONES.

Obj. 4 in. (Carmine).

Fig. 116. SCLEROSIS OF GOLL'S COLUMNS
(Tabes dorsalis).

Obj. 4 in. (Carmine).

The various Sclerotic Processes in the Brain and Spinal Cord.

We have learnt from the preceding sections, that division of a nerve tract results in a secondary degeneration of the nerve fibres and in a slight increase of the ground nerve tissue (the neuroglia), as well as of the connective tissue elements. It was seen that when nerve tissue was carefully compressed, that there was a rapid necrosis of the nerve elements and complete disturbance of the ground tissue, as manifested by the œdema; that if healing occurred there was a very great overgrowth of connective tissue, together with some neuroglia increase. In clean incised and punctured wounds, there is a slight fibroblastic and endothelial growth and usually a considerable spider cell proliferation. But if in any of the above examples irritation be kept up by micro-organisms, or by other means, then there is a still greater connective tissue and vascular reaction as well as neuroglia increase, but the former predominates. From the above examples, therefore, it may be gathered, there may be a progressive series of reactions, in the mildest form a slight neuroglia hyperplasia,* in the severest a very manifest connective tissue overgrowth. Both these degrees of sclerosis will be encountered in the conditions now about to be described, and evidence will be brought forward to show that in some cases the two forms may differ ætiologically. But further there

* Whether there is a proliferation of *nerve fibres*, has at present only been surmised by a few; as will be seen further on, proliferation of nerve cell nuclei is described.

seems much in favour of a third variety of "sclerosis," a form which has been almost overlooked and is probably of the nature of a neoplastic growth.

Amongst essentially primary sclerotic processes must be placed the changes encountered in certain forms of epilepsy and paralysis of the insane. Reference has already been made to the parenchymatous degenerative changes, such as vacuolation, atrophy, pigmentary and fatty degeneration of the nerve cells encountered in these conditions; similarly it may be mentioned that the nerve fibres may show degenerative reactions, such as varicosities and atrophy. But of most interest are the proliferative changes which are associated with the involution of the essential nerve elements—the so-called curious "atrophic proliferation" to which attention has so often been directed in the preceding chapters. Thus in *dementia paralytica*, Mendel (1890) confirms the fact of the great increase of the spider cells* in the cortex; so great in fact that owing to the meshwork produced, the cortex may be stripped from the white matter. Further, Tigges, Meynert, Hoffman and others describe a proliferation of the ganglion cell nuclei in similar and allied conditions. In addition colloid bodies may be found, and the vessels may be the seat of hyaline and endarteritic changes. It is clear, however, that the condition is not of vascular origin, and that other causes, probably congenital, must be sought for.

The ordinary histological changes encountered in *disseminated sclerosis*, *tabes dorsalis* and *Friedreich's disease*, are also examples of primary sclerosis. The three

* In sections from epileptics, kindly furnished by Drs. Mott and Bevan Lewis, there is great spider cell hyperplasia.

Fig. 117. SCLEROSIS OF POSTERIOR COLUMNS.
(Tabes dorsalis).

Obj. 4 in. (Aniline blue-black).

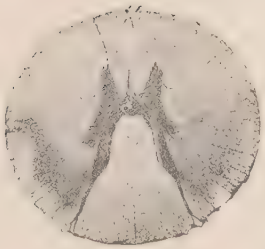

Fig. 118. DEGENERATION OF PYRAMIDAL TRACT
(Dorsal region).

After extirpation of the motor cortex in monkey

Obj. 4 in. (Aniline blue-black)

diseases have been made the subject of the most searching and voluminous investigations, and naturally there is a great disparity of opinion concerning the interpretation and the causation of the changes found.*

In *disseminated sclerosis* Charcot and Vulpian very early showed that although there appeared to be a complete interruption of the nerve fibres in the sclerosed areas, yet numerous axis cylinders could be made out, probably connected above and below with the medullated fibres; an explanation was thus offered, why in certain cases of disseminated sclerosis, with apparent interruption of the nerve fibres, there was no secondary ascending or descending degeneration.† Later Babinski demonstrated that there was often a large number of amyelinic fibres in the diseased areas. In other cases, however, the majority of the fibres may disappear or pass into various stages of degeneration; there may then be a very considerable connective tissue and endothelial overgrowth, proliferation of the corpuscles of the central canal,‡ chronic meningitis and secondary degenerations. In view of the connective tissue and vascular proliferative changes, a large number of authorities regard these as primarily vascular, and either starting in an acute myelitis (interstitial) or spreading from a meningitis. There is also evidence, however, in favour of a primary parenchymatous origin. Further that the change may in a few instances be neoplastic will be rendered more obvious later on; in

* Consult references in the Bibliography.

† This phenomenon may be compared with the disseminated neuritis of Pitres (see later).

‡ A very common phenomenon whenever there are hyperplastic changes in the cord.

the meantime it may be borne in mind that a case of disseminated fibromata has been recorded in the cord (Charcot *ref.* Blocq).

Locomotor ataxy or *tabes dorsalis* is regarded by the great majority of observers as a *system sclerosis.** In advanced cases, and therefore in those usually encountered, there is a very evident sclerosis of the posterior columns, **Fig. 117,** usually most marked in the lumbar region; higher up the process may be confined to Goll's column, **Fig. 116,** taken from the cervical region of another case; or limited portions only of the postero-median and postero-lateral columns may be affected. The lateral columns are much less frequently than is the case in hereditary ataxy, the seat of a simultaneous sclerosis, but there may be degeneration of the posterior roots and of the peripheral nerves and in some cases of the grey matter and Clarke's columns. In studying the histological process, one is struck by the differences of the appearance of the sclerosis in certain cases. Thus in fig. 117, where the whole of the posterior column is affected, and where in addition there is considerable distortion of the cord, perivascular fibrosis and general connective tissue overgrowth is very marked; whilst in fig. 116, where Goll's columns are neatly mapped out,

* Flechsig has in a recent paper (1890), on the appearance of the cord in *early* cases of Tabes, drawn comparisons between the distribution of the sclerosis in the posterior columns with certain tracts in these columns, which like the lateral tracts are late to become medullated (*see* figs. in "Neurolog. Centr.," 1890). He further emphasizes the *morphological* rather than the functional significance of a "system." The degenerated tracts in question are found in the middle root zone and in the median zone; this appears in accord with what has been figured and described by Leyden, Charcot, Strümpell and others.

there is comparatively little increase of the interstitial tissue. From this it may be gathered, that just as in the case of disseminated sclerosis, there are those who regard the changes as either primarily parenchymatous or interstitial. If, however, the early distribution of the sclerosis is as Flechsig and others show, and if tabes is a system disease, then the evidence is in favour of a primary parenchymatous change and of a congenital or hereditary proneness to degeneration, a point which is more strikingly brought out in the next disease.

Friedreich's disease or hereditary ataxy.—The distribution of the sclerosis appears much the same as in tabes (advanced cases only appear as yet to have been examined). Rütimeyer, in his well known paper (V.A., 110)* gives extensive degeneration of the posterior columns, especially marked in the tracts of Goll; systematic degeneration of the pyramidal and cerebellar tracts; degeneration of Clarke's column; atrophic degeneration of the posterior roots. In one of his cases the median and sacral nerves showed very distinct atrophy of the fibres and connective tissue substitution, and in some parts considerable connective tissue proliferation. This observer regards hereditary ataxy as a *combined* system sclerosis. The use of the term combined has, however, been strongly objected to by Déjèrine, who points out that just as in the case of tabes dorsalis, the sclerotic process as often as not passes the boundary of the pyramidal and cerebellar tracts, and that the sclerosis in the antero-lateral columns much more closely resembles a meningo-mye-

* Friedreich's original and classical description will be found in V.A., 68 and 70.

litis.* Amongst other remarkable gross anatomical changes, which may be present, may be mentioned diminution in size of the medulla and malformations of the neural canal. For us, however, the greatest interest centres around the histological changes, and to Déjèrine and Letulle belong the merit of first having laid stress upon them.† These observers describe and figure in the posterior columns, of a remarkable case of hereditary ataxy, interlacing bundles of extremely long, wavy and delicate fibres, with comparatively few nuclei; here and there a few medullated fibres are found in the bundles, following their numerous windings; there is no increase in thickness of the processes of the pia mater and the walls of the vessels appear normal. But curiously the appearances in the lateral tracts are different, here the pia mater and processes are thickened and there is perivascular fibrosis. They regard the condition in the posterior columns as a *pure neuroglia sclerosis*, in which connective tissue elements do not enter; they consider the fine fibrils as belonging to the neuroglia cells and therefore to the supporting nerve stroma. The change is for them a congenital neuroglia hyperplasia, and certainly a glance at their figures with the peculiar appearance of the central region of the cord and of other portions, leaves no room for doubt but that what they are describing is congeni-

* "Du rôle joué par la meningite spinale postérieure des tabétiques dans la pathojénie des scléroses combinées," *Archiv. de Phys.*, 1884.

† "La maladie de Friedreich—sclérose névroglique pure des cordons postérieurs," *Médicine moderne*, 1890. I may here take the opportunity of expressing my thanks to M. Déjèrine, for his kindness in showing me his preparations of this and other diseases.

tal.* I will, however, venture on a different interpretation of the histological changes. In the first place their figures strongly remind one of the *neuro-fibromata* of the peripheral nerves; in these, as will have been gathered in the chapter on tumours, the relative proportion of myelinic, amyelinic and connective tissue fibres respectively varies very greatly; further, the growths are sometimes disseminated, sometimes diffuse, and lead to the uniform thickening of a nerve. I moreover regard the neuro-fibromata as the result of the growth of neuroblasts and fibroblasts,† and due, in the large proportion of cases, to some congenital "fault" or "irregularity." But in the central nervous system there seems no very strong reason why there should not be analogous tumour formations, and if this is so, then perhaps the condition described by Déjèrine and Letulle in the posterior columns is of the nature of a *neuroma*, a neuroblastic growth due to some congenital "fault" or "irregularity."‡ Rütimeyer states that in his cases there was a fibrillated very corpuscular con-

* They state that the changes appear similar to those described by Chaslin ("Comptes Rendus Soc. de Biologie," 1889) in essential epilepsy; but as far as I can see, Chaslin described very little more than the neuroglia increase described on p. 382. In a more recent communication ("Archiv. de Méd. Exp.," &c., 1891) he, however, figures in addition to neuroglia cells, bundles of long fibrils which run in different directions. He regards them as belonging to the neuroglia. Weigert ("Cent. f. Path. Anat.," 1890) regards Friedreich's as similar to other forms of sclerosis.

† I have been enabled to take this view more especially since the recent researches of Büngner on nerve section (see above).

‡ I am very far from stating that all cases of Friedreich's disease are examples of neuroblastic growths, or that neuroblastic growths are only found in hereditary ataxy.

nective tissue, amongst which spindle cells were scattered; there was no change in the vessels and the pia mater was not thickened. In his cases therefore the change might or might not have been of the nature of a connective tissue overgrowth, but if the former then it must have been of a special type. As a matter of fact fibromata and spindle celled growths are recorded in the central nervous system, which have every appearance of being congenital.*

Apart from the question of either a neuroglia or neuroblastic overgrowth, there exists in some cases of tabes dorsalis, and hereditary ataxy, considerable thickening of the pia mater and of the perivascular connective tissue. But why are certain tracts picked out by the perivascular fibrosis before others? Presumably we must suppose that these tracts are more prone to involution, and that from some cause they do atrophy and that the place of the atrophied fibres is then taken by connective tissue. Whether these tracts fall under a morphological system (Flechsig) remains to be seen.† A premature involution may take place at any time; in the case of parenchymatous organs, very early congenital atrophy of the parenchyma of the

* A multiple case of fibromata in the cord figured by Blocq (Atlas) and one extending down the centre of the cord by Gowers ("Spinal Cord and Nerves," p. 422). It is clear that if the same difficulty exists in the central system of distinguishing connective tissue fibrillæ from nervous, as is the case in the peripheral, the two may often be confounded. Déjèrine and Letulle in their case applied Malassez's tests (acetic acid and caustic potash) and obtained no connective tissue reaction.

† Charcot supposes that in tabes an irritation starting from the nerve fibres, calls forth a vascular and connective tissue reaction. Babinski points out that tabes is very often much less systematic than a secondary degeneration.

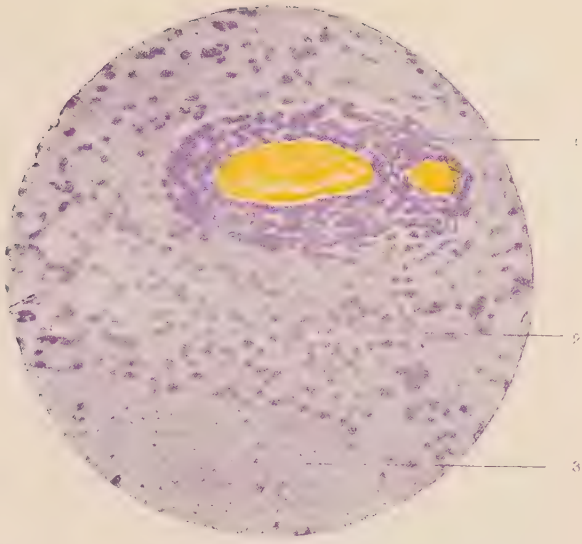

Fig. 119. CONGESTION OF THE CORD (HYDROPHOBIA)
(Cervical region).

1. Perivascular lymphatic infiltration. 2. Grey matter
3. White matter.

Obj. $\frac{1}{8}$ in. (Logwood).

Fig. 120. ACUTE MYELITIS

Obj. 4 in. (Methylene blue)

liver or kidney may occur, and an equally early connective tissue invasion is the consequence. There is evidence of ataxy in very young subjects.*

Meningitis, Tubercle, Syphilis and Diseases of Vessels.

Meningitis or inflammation of the membranes of the brain and spinal cord. A division is made into *leptomeningitis* when the pia mater and arachnoid are chiefly affected, and *pachymeningitis* when the dura mater is the seat of the more marked changes. In the acute forms the inflammation is widespread, usually involving the membranes of the brain and spinal cord. The inflammation is comparable to that observed in the pleura and peritoneum and may be dry, "serous," "fibrinous," purulent or hæmorrhagic. In some forms the leucocytic element is very abundant both in the fluids and in the œdematous membranes. There may be softening of the adjacent nerve tissue and considerable perivascular small round celled infiltration. As causes, micro-organisms are probably prominent; diplococci, streptococci and bacilli having

* The most striking examples of fœtal parenchymatous involution are those which are embraced under the wide term of *hereditary* syphilis. In these cases attention may be directed to the difference of the appearance of the connective tissue to that which is seen, when in after life an organ is either prematurely made to undergo atrophy or does so naturally. The explanation of the difference will probably be found as in the case of neoplasms (*see* preceding chapter) in the difference in time of the connective tissue substitution. Perhaps therefore the difference in the appearance of the sclerosis in certain cases of tabes may be due to the difference in time of the connective tissue reaction.

been found in various epidemics of *acute cerebro-spinal meningitis* (*see* Bonome, Adenot, Weichselbaum and others).

In chronic meningitis, the inflammatory reaction tends to be confined to one spot, and the necessity for a division into lepto- and pachymeningitis becomes more obvious. In those forms which are excited by micro-organisms the inflammation is more widespread. Thus in *tubercular meningitis*,* grey, translucent or opaque miliary granulomata are freely scattered over the meninges, and in the case of the brain penetrate between the sulci and spread into the lateral ventricles. They form in the perivascular sheath of the vessels, small lymphoid aggregations, in which giant cells are usually absent; there is, however, a remarkable proneness to necrosis. Sometimes the granulomata penetrate into the nerve tissue for a considerable distance. The serous cavities are not often occupied by a turbid or purulent fluid, the pia mater is usually dry, but it may be swollen, gelatinous and glairy looking, and the vessels much engorged.

There are other forms of meningitis which are much more chronic than the above, and which lead to great overgrowth and matting of the membranes, atrophy of the nerve roots and compression myelitis. *Syphilis* is regarded as a common cause of these. The lesions ascribed to it tend to be focal and consist in hypertrophic pachy-, and leptomeningitis; the plaques of sclerosis often assume a wedge or oval form and may press deeply into the brain or spinal cord. In the younger portions of such a growth, there is marked fibroblastic and endothelial (vascular and serous) pro-

* See also Eppinger's pseudo-tuberculosis cladothrica, p. 116.

liferation; new vessels are formed, whilst the walls of the larger are often enormously thickened—the peri- and endarteritis of syphilis. Perivascular hyperplasia usually extends for some considerable distance into the cortex. In the older portions of the hyperplasia, necrosis is very common.

Charcot and Joffroy describe in the cord a very interesting annular form of hypertrophic pachymeningitis; in which the connective tissue overgrowth produces atrophy of the nerve roots and compression myelitis, followed by secondary degenerations. The dura mater and its processes are sometimes the seat of diffuse or multiple thickenings; ossification may occur, and pigmentation as the result of an old extravasation. Caries of the skull or vertebræ may lead to a very pronounced hypertrophic pachymeningitis. In many atrophic forms of cerebral disease, as in dementia paralytica and allied conditions, the membranes, as well as the neuroglia, participate in the general hyperplasia.

In addition to causing meningitis, both tubercle and syphilis give rise in the central nervous system to inflammatory tumours, the so-called "*crude*" *tubercles* and *syphilomata* or *gummata*. The former are often found in the cerebellum and pons; they may be single or multiple, and may attain to a considerable size, giving rise to severe pressure effects. In microscopic sections one is often struck both by the scantiness of the proliferative changes and the great extent of the necrosis. The gummata may likewise be multiple and may vary in size; in structure they are usually more fibrous, and both peri- and endarteritis may be very marked; necrosis and the formation of hyaline areas occur. Much stress has been laid upon gummatous

arteritis and endarteritis syphilitica (p. 121); Baumgarten is of opinion that both conditions commence in the adventitia. The change is a very possible source of aneurism.

Neuritis.

Atrophy and degeneration.—In the peripheral nerves we need only concern ourselves on the one hand with the connective tissue and vessels, and on the other with the nerve fibres; the nuclei of the sheath of Schwann will, however, require attention, as they take no inconspicuous part in nerve changes.*

In the commencement of the chapter reference was made to the secondary degenerations and to Büngner's neuroblastic theory; we need therefore not concern ourselves again with the reactions—degenerative and proliferative—which result when a nerve is cut or wounded.

Effects of toxic agents on the peripheral nerves.—Lead, arsenic, mercury.—In the slow poisoning by these metals considerable histological changes have been found in the muscles, peripheral nerves and cord. The seat of the primary mischief has been much disputed. Friedländer, for instance, found in a case of lead palsy marked "atrophic proliferation" of the muscle fibres, and was inclined to regard the muscles as being primarily affected and that the changes in the nerves and cord were secondary. Leyden presumed that in poisoning by the three metals, the muscles and nerves

* With the view of rendering evident the nuclear changes, it is essential that if osmic acid be used, *the nuclei are counter-stained by carmine, saffranin, or other nuclear stain.*

were especially affected, but that the cord might be sometimes. Popow with large doses obtained acute myelitis, the peripheral nerves remaining unchanged under these circumstances. Eichhorst finally summed up by saying that in lead palsy, there is first a change in the nerves, secondly in the nerves and muscles, and thirdly, in the nerves, muscles and cord. The prolonged administration of lead as we shall now see is in favour of a primary peripheral neuritis. The early researches of Gombault (1880) were very instructive; he found a peripheral neuritis, but unlike a Wallerian degeneration, a nerve might be the seat of numerous lesions; microscopically these were characterised by breaking up of the medullary sheath and increase of nuclei, but the nerve fibres above and below the diseased patch appeared healthy. In regenerated portions, the new nerve fibres were remarkably small. The "segmental" character of the lesions is worthy of note; it is seen in other forms of neuritis. In 1889, Prevost and Binet made a series of observations which confirmed the above. They found that after a few months the nerves in some animals were more affected than in others (as shown by paralysis); that on withholding the lead the animals recovered. That when paralysis was present the nerve fibres were degenerated, but that on recovery there was a formation of a large number of small fibres and the presence of a large number of nuclei. In some cases degenerating and regenerating fibres were found together. The sciatics appeared more often affected than the brachial nerves; the roots were intact and contrary to Harnack's observations the muscles were unaffected. From these experiments we may perhaps be justified in concluding, that

proliferation of the nuclei of the sheath of Schwann—the neuroblasts—may occur together with a new formation of fibres. It is interesting to note that Eichorst describes, in a case of lead palsy, small scattered islets of nuclei confined to the sheath of Schwann; and that in a case of Westphal's there were numerous small fibres in the radial. Thickening of the vessels has been observed.

Diphtheritic neuritis.—As in lead palsy, so in the diphtheritic, uncertainty has existed as to whether the change is primarily one of the muscles, nerves or cord. There is no doubt that in diphtheria as in other severe infective processes, general parenchymatous changes are common and that the muscles and central nervous system very often do become deeply involved; but there is also no doubt that in cases of diphtheritic paralysis there exists a very severe neuritis, sometimes widespread, sometimes limited to a few nerves. The neuritis may extend along a nerve for a considerable distance, or it may be segmental as described above (Gombault, Meyer, Pitres and others). The lesions show the usual parenchymatous degeneration, side by side very often with proliferation of the nuclei of the sheath of Schwann. Meyer describes swellings on some of the finer nerve branches (neuritis nodosa); this appears due to œdema of the sheath, and it may be here mentioned that interstitial changes such as vascular extravasations and small round celled proliferation, sometimes occur.

Landry's paralysis, Beri-beri or *Kak-ke.*—In 1890 Centanni described, in an acute *progressive neuritis* which seemed in every way to correspond to Landry's paralysis, a very marked *bacillary* invasion of the

nerves. The nerves of the cauda appeared most affected and the inflammatory process had spread to the lower portion of the cord. The changes consisted in engorgement of the vessels and small round celled infiltration; the pia mater was congested and œdematous. The nerve fibres showed little change under the microscope although closely beset by bacilli.* Centanni regards the condition as a *neuro-mycosis*, in which profound nerve alterations are caused by the presence of micro-organisms in the neuro-lymph.

There is much in favour of *beri-beri* being an *infective multiple neuritis* (Scheube, Baelz). According to Scheube the changes consist in degeneration of the medullary sheaths, varicose degeneration or complete disappearance of axis cylinders, interstitial proliferative changes and perivascular small round celled infiltration. The lesion was most marked in the muscular branches, and the muscular fibres themselves were degenerated. In the cord there was hyperæmia of the membranes and increase of fluid. The large glandular organs were the seat of parenchymatous changes.

Neuritis may occur in *hydrophobia* and in other acute infective processes.

The *neuritis of leprosy*, owing to the long duration of the irritation and the consequent connective tissue overgrowth, furnishes a striking example of an interstitial neuritis. In the earlier stages bacilli are found in abundance in the nerves and even in the ganglia (Sudakewitsch). There is at first considerable connective tissue cell and endothelial proliferation, which later gives place to a dense fibrous tissue; the nerve fibres gradually undergo degeneration and atrophy,

* Stained by methylene blue.

their place being taken by the fibrous tissue, until finally a nerve bundle may be represented by a dense, usually concentrically laminated, fibrous mass. When the hyperplasia is considerable, large spindle shaped swellings are formed on the nerves.

Alcoholic neuritis.—**Figs. 113 and 114** represent the appearance of a small nerve in an advanced case. Conspicuous is the disappearance of the nerve fibres and the endoneural substitution. There is, however, no marked fibroid overgrowth ; but the latter according to Eichhorst may occur to a marked degree in the small inter-muscular nerves, and according to this observer there is an increase in the nuclei of the sheath of Schwann.

The neuritis which may sometimes occur in *diabetes*, *phthisis*, *rheumatism*, &c., is probably a more pronounced example of the "atrophic proliferation" encountered in many of the tissues in cachectic conditions. In *tabes dorsalis* an extensive degenerative neuritis has been described by a large number of observers.

Under *cutaneous neurites** (Leloir, Babinski) are grouped the nerve changes found in herpes, ichthyosis, pemphigus, perforating ulcer, &c. (*see* later).

Certain Malformations, Syringomyelia, Etc.

Heterotopia of nerve matter is observed both in the brain and spinal cord. Heterotopia of the grey matter, according to Otto, Simon, Meschede, Pfleger and others, appears a comparatively frequent condition in the cerebrum and cerebellum ; it is less common in the

* For much information on the subject of neuritis, consult Madame Déjèrine, "Thèse de Paris," 1882, Babinski, "Gaz. hebd.," 1890. Buzzard, "Lancet," 1885 and Bibliography.

cord. On the cortex, numerous small nodules, containing the various nerve elements are sometimes observed; heterotopia also occurs in the wall of the lateral ventricle and in numerous other situations. In the cord the grey matter may be very irregularly distributed, or a projection may be formed on the surface by grey and white matter.

Occasionally there is a partial doubling of the cord, usually most marked in the caudal extremity; in these cases two central cavities may exist and the distribution of the grey matter around each may be fairly symmetrical. The presence of one or more neural canals, or diverticula from the original central cavity has been recorded by several observers; they have been often found in cases of syringomyelia. A rosary like ectasia of the central canal has been sometimes met with, Virchow has observed it in a few cases of tabes dorsalis.

*Syringomyelia.**—A distinction between *hydromyelia* and *syringomyelia* was at one time made, some reserving the former term in cases where the central canal was enlarged, others when the condition was acquired. At the present time syringomyelia and cavity formation (when the latter is at all extensive) have become almost synonymous. In very many cases the cavity is of secondary importance when compared to the amount of the peculiar neuroglia changes around it; thus the relationship of *glioma* to syringomyelia has become very

* The literature upon this subject has enormously increased. Mlle. Bäumler, "Deut. Archiv. f. klin. Med.," 1887, collected 112 cases (including varieties). Bruhl, "Contrib. à l'étude de la Syringomyelie," Paris, 1890, has still further brought the literature together (some 150 references). K. Miura (Marchand's Lab.) has more recently, 1891, analysed other cases and made a critical survey of the subject (Ziegler's "Beiträge").

close and it may be said that there are three conditions in the cord which are either related to one another or may possess many features in common, viz., *glioma*, *cysto-glioma* (Bruhl) and *cystic dilatation* without marked gliomatous change.

A glance at the very numerous illustrations, descriptions and specimens, demonstrates that syringomyelia may arise in many different ways. Comparing Chiari (1888) with K. Miura (1891), they are found to agree in believing that the condition in question may arise from extensive myelitis or hæmorrhage, or that it may be an acquired or congenital condition, or be the result of softening in gliomatous tissue, which tissue may be of the nature of a neoplasm, inflammatory product or hypertrophy (K. Miura). The latter author goes so far as to state that the majority of syringomyelias arise from softening of a simple neuroglia overgrowth.

Joffroy and Achard describe a *myélite cavitaire*, and are of opinion that the cavities are due to chronic inflammatory disturbances. In compression myelitis it has been shown that the central canal may become dilated or that new cavities may form,* and many believe with Langhans that cases of syringomyelia arise in this way. Westphal and Simon regard the condition as a softening in a gliomatous tumour. On the other hand there can be no doubt, that as Virchow, Leyden, M. Miura and numerous others have emphasized, the condition may be congenital and due to dilatation of the central canal or persistence of other portions of the original neural canal (including diverticula and free secondary canals), together with persist-

* See compression myelitis, also a good case recorded by Silcock, "Path. Soc. Trans.," 1888.

ence of more or less neuroglia tissue. In these cases there are often associated congenital defects, such as asymmetrical doubling of the cord in the caudal region, hydrocephalus, arrest of development of brain tissue and other abnormalities.

If the cavity is of central origin, distension takes place backwards, and the larger the cavity, the smaller the amount, as a rule, of neuroglia tissue. There may be more than one cavity; the cavities may be quite free from the central canal, which need not be altered. The cavities are usually situated in the region of the grey matter and may be surrounded by very little neuroglia tissue. A cavity is often found posterior to the central canal, and sometimes a connection between the two can be found; occasionally several diverticula are given off from the central canal, or the cavities may be expanded unequally at different levels. They are not often completely lined by columnar epithelium, and indeed in the majority of cases there is none. It is not usual for the cord to be enlarged; when this is the case, it is due to the presence of a gliomatous tumour. The tissue which surrounds the cavity may be, as previously remarked, of the nature of a neoplasm, simple hypertrophy or inflammatory product; it may appear like the tissue found in sclerosis of the cord, or it may be gelatinous and almost structureless, or formed of a dense meshwork of exceedingly fine fibrillæ with few cell elements, or in the case of the gliomata there may be a large proportion of cells. In a case of Reisinger's and Marchand's there existed a spider cell tumour in one portion of the cord and a cavity surrounded by sclerotic tissue in another. In K. Miura's case the periphery of the growth was cellular, whilst the central

fibrillated portion appeared to undergo softening previous to cavity formation.

Secondary ascending and descending degenerations may be present; they are either due to invasion of the tracts by the gliomatous tissue or to pressure from the cavity; it is, however, probable that in some cases the degeneration is a primary atrophic condition.

Tumours of the Nerves, Spinal Cord and Brain.

Tumours of the nerves.—On pp. 128 and 136 reference has been made to the large group of neuro-fibromata. They may consist largely of amyelinic fibres or of the special perineural tissue and they may exist for long periods without interfering with the conductivity of the ordinary nerve fibres which pass through them. Their multiple or widespread origin and the usually characteristic and sarcomatous appearance of the perineural tissue, distinguishing it readily from the general connective tissue around, serve to demonstrate their embryonic origin;* they are comparable to the adeno-fibromata and adenosarcomata (*see* preceding chapter). On the other hand, the amputation neuroma is an acquired growth, made up of a hyperplasia of neural and perineural elements; the nerve fibres of which these are composed may be very small, with only a thin myelinic sheath, whilst it is probable that some have no sheath; the axis cylinders may present spindle shaped swellings (not degenerative); the new formed perineural tissue can be distinguished from the general skeletal tissue around, and there is a close relation-

* They owe their origin most probably to rests of neuroblasts and perineural cells.

ship preserved between the nerve and fibrous elements. Occasionally the peripheral neuromata undergo a myxomatous change.

Tumours of the cord and brain.—In dealing with the tumours of the cord and brain it is necessary to bear in mind the various tissue systems of the central nervous system, such as :—

1. The membranes—dura mater, arachnoid and choroid.

2. The special perineural tissue—the pia mater.

3. The perivascular tissue and vessels.

4. The nerve elements, including (*a*) the neuroglia, (*b*) the nerve fibres and nerve cells.

5. Special tissue elements like the anterior lobe of the hypophysis, which is a rest of a glandular organ that has become cut off from its external connections.

In connection with the last group (5) readers may be referred to pp. 180, 201 and 207, where references have been made to the tumours occasionally met with in the region of the hypophysis, pineal gland and elsewhere. They are examples of inclusions and embrace fatty, muscular, fibroid, cartilaginous, bony, cystic, dermoid, epitheliomatous and teratoid growths.* In the cord both Recklinghausen and Gowers have described myo-lipomata within the theca ; in the former observer's case there was a spina bifida. Lipomatous inclusions are much more frequent. Some are found inside the theca, others at the base of brain, region of hypophysis, pineal body, arachnoid, choroid, &c. The more interesting are found in the nerve substance ; in these cases it may be supposed that fat elements

* They are mostly found in connection with the dura mater arachnoid or choroid.

have been carried in with the perivascular tissue, or with prolongations of the arachnoid, or pia mater (Virchow).*

Ossification and the presence of cartilage is not infrequently observed in the dura mater, and Lancereaux and others have described fibroid and spindle celled growths. Papillomata and endotheliomata also occur. The arachnoid of the spinal cord has been found the seat of multiple osteomata (Zanda), and as mentioned above a large number of what are probably inclusions are associated with this membrane or the choroid. Tumours however, which appear proper to the arachnoid, are the melanotic (p. 375), cystic (often multiple), nævoid, angiosarcomatous, papillomatous and endotheliomatous. The vascular tumours often involve the pia mater as well as the arachnoid; they may be cavernous with very little stroma or cellular, and in the latter case the cells are often arranged concentrically around the vessels; the stroma may also be fibrous, and is prone to undergo marked hyaline changes† (*see* further examples below).

The tumours of the *nerve roots* and cauda equina are very frequently multiple; they are for the most part neurofibromata, but "fibromata," "sarcomata" and other tumours are described. By far the greatest interest, however, centres in the tumours proper of the

* In the cord two good cases have been described; one by Kronthal, the other by C. Turner. In the brain the fatty tumours may be multiple. Fat appears a not very abnormal element in the raphe of the corpus callosum.

† Ziegler figures a case of multiple hyaline nævi in the cauda, and I have examined two cases in the cord (involving roots), one precisely like Ziegler's, the other a *cylindroma*.

brain and spinal cord. They include the tissue systems 2, 3 and 4 (*see* above) and are :—

1. *Connective tissue* and *perivascular tumours*, viz., fibromata, sarcomata, angiosarcomata and lymphosarcomata.

2. *Neuromata*—amyelinic and ganglionic.

3. *Gliomata*—tumours of the neuroglia.

4. Mixed tumours as neurogliomata and neurofibromata, &c.

A characteristic feature of a large number of these tumours is their *multiple* or *widespread* origin, points in favour of their congenital nature ; this is especially striking in the case of fibromata, lymphosarcomata, neuromata and gliomata.

In the cord disseminated *fibromata* have been described (Charcot), and other cases of fibromata of the cord are figured in Blocq's "Atlas" and elsewhere. Gowers describes and figures one of considerable length which was situated in the centre of the cord. Spindle celled tumours appear more common in the brain.

Perivascular tumours are taken together comparatively frequent in the brain. In the angiosarcomata (perivascular endotheliomata), the cells are grouped around small vessels or very delicate capillaries, the walls in many cases being formed by the cells ; the latter vary in shape and size, sometimes they are flattened and arranged concentrically around a vessel, and the central vessels may calcify ; or the cells are round or large and epithelioid-like.* To this class of tumours

* This form of tumour which appears often to bear a strong resemblance to an epithelial or gland structure, has been several times recorded and I have also come across an example.

probably belong some of the *cholesteatomata*, *brain sand tumours* or *psammomata*, *angiolithic sarcomata* (Cornil and Ranvier) and *cylindromata*. The *lymphosarcomata* are infiltrating small round celled growths, which at first are limited to the perivascular sheaths, along which they extend for considerable distances.* Much has been written upon the *neuromata* and *gliomata* notably by Klebs. In this country "glioma" has come to mean any tumour in the nervous system of a small round celled or neuroglia type, quite irrespective of its tissue origin; it is here used, however, to designate a tumour of the neuroglia, whilst neuroglioma is used after Klebs for mixed tumours containing nerve and neuroglia elements. Hyperplasia of the nerve and glia cells and cells of the central canal has been referred to in the preceding pages. Neuromata, neurogliomata and ganglionic neuromata are described in the brain or in the roots of the nerves. The neuromata consist of long fibrillæ and do not give a connective tissue reaction. For special views upon a case of Friedreich's disease *see* p. 386. The gliomata are remarkable tumours, the most typical of which may be pictured as consisting of numerous spider cells and their meshwork. In some cases the cells are very scanty or they do not appear spider like, but there may be an abundant meshwork of fibrillæ and as K. Miura remarks the cells may be more abundant at the margin of the tumour.† They may be sharply circumscribed or they may infiltrate. They are usually either multi-

* I am indebted, through Mr. Horsley, to Dr. Gray of the Army Medical Department, Washington, for beautiful preparations and photographs.

† This observer has collected twelve striking cases.

tiple or have a very extensive origin, often in the neighbourhood of the central canal. In some gliomata large epithelioid cells have been described. Their relationship to syringomyelia has been mentioned.

This short survey of the tumours of the nervous system may be closed with the following remarks upon certain *gliomata of the orbit*,* which are partly based upon some observations of Eisenlohr. The vitreous is formed of mesoblast cells—special connective tissue cells—which with the matrix undergo a peculiar metamorphosis. Not all the cells, however, undergo this change, and under normal circumstances, some remain over at the periphery and along the walls of the vessels. It may be supposed, however, that owing to some "fault" or "irregularity," an abnormal number of the mesoblast cells fail to undergo the metamorphosis, and that they form rests from which a tumour may subsequently take its origin. As Eisenlohr remarks these tumours are remarkably prone to degeneration.

Tropho-neuroses.—A very large and very important series of tissue changes have been found associated with lesions of the cord and peripheral nerves. Sometimes the nerve lesion is accompanied by marked peripheral endarteritis, or the patient is the subject of severe cachexia.

Büngner found, when a portion of the sciatic was removed, that he obtained in the first instance hyperæmia of the skin and perhaps vesiculation; later atrophy, formation of ulcers, changes in the nail and even disappearance of the last phalanx as in Lepra mutilans; in

* The glioma of the orbit must be considered a connective tissue tumour. It frequently affects both eyes, and it occurs chiefly in young children, characters which indicate its congenital origin.

some cases there was slight joint swelling. O. Israel has figured a most interesting case of complete atrophy of the finger extremities which took place after a bullet wound of the brachial plexus, whereby the lower ends of the median and ulnar had atrophied. In acute myelitis, bed sores and œdema, and in locomotor ataxy and in other paralyses, disorganisation of the joints and bone atrophy, are common phenomena. As previously mentioned many skin eruptions and atrophic epithelial changes have been found associated with *cutaneous neuritis*. *Syringomyelia* affords numerous examples of trophic lesions, such as atrophy and vesiculation of the skin, changes in the nails, phlegmon (panaritium), perforating ulcers, and joint and bone lesions. *Morvan's disease*, if it differs at all, differs but slightly from the former (Charcot); and changes in the cord similar to many of those described under syringomyelia (*see ante*), in addition to peripheral changes, have been recorded (*see* Bibliography). It is characterised by a *panaris analgésique*—a phlegmonous or whitlow-like condition of the fingers, first attacking one hand, then the other. It has been confounded with some forms of lepra mutilans; the latter has also probably been confounded with syringomyelia.*

In *perforating ulcer*, *Raynaud's disease*, *sclerodermie* and *sclerodactyly*, cord or peripheral nerve changes have been shown. In sclerodermie there is atrophy and sclerosis of the skin, nail changes and disappearance of the terminal phalanges. According to Charcot

* That is to say, cases of "Lepra mutilans" have been described with cord (formation of cavities, &c.) and nerve changes (Steudner, Langhans); but whether these were specific nerve changes due to the selective action of the virus of leprosy does not transpire.

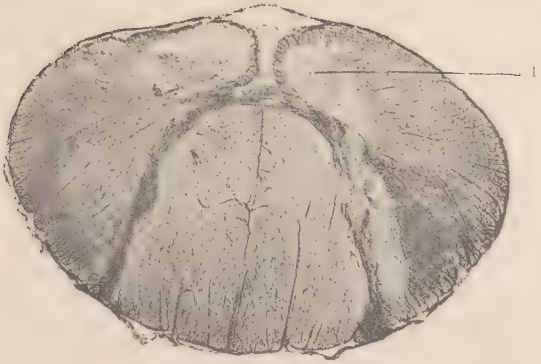

Fig. 121. ACUTE ANTERIOR POLIOMYELITIS.

1. Remains of anterior horn.

Obj. 4 in. (Aniline blue-black).



Fig. 122. ACARUS SCABIEI

Large female, and small male

Obj. ⅛ in.

sclerodactyly is a special variety of the latter which confines itself to the hands and face. In Raynaud's disease—symmetrical gangrene or local asphyxia—peripheral neuritis, endarteritis and other changes have been recorded. Hochenegg describes syringomelia-like changes in the cord. Lastly Mendel records a case which first showed the signs of Raynaud's disease, then of Morvan's and finally of sclerodermie. Of the changes in the cord which very often accompany the above "trophic" manifestations, most observers lay stress upon those occurring in the posterior horns and in Clarke's columns.

Note.—**Fig. 115** shows early degeneration of the posterior root zones. The condition was produced by the pressure of a tumour upon the nerve roots.

Chapter XX.

ANIMAL PARASITES.

In this short chapter attention will be directed to the tissue reactions excited by the parasites, rather than to their life history; information concerning the latter should be sought for in the works devoted to helminthology, notably those of Cobbold and Leuckart.

The animal parasites, from the point of view of the tissue changes to which they may give rise, have recently excited keener interest than heretofore. This has been especially the case with the psorosperm forms, which have been accredited with simple and malignant tumour-exciting properties. How far this opinion is justified, it will be our endeavour to show in the following pages.

In the preceding chapter considerable stress was attached to the embryonic or congenital neoplasms. In this chapter, on the contrary, the importance of *irritation* in producing hyperplastic changes will be again insisted upon. In studying the tissue changes produced by this irritation it will be found that the nature of the reaction varies remarkably; thus apparently the same parasite may in the same or in different species produce (1) remarkably little tissue change; (2) widespread hyperplasia, and (3) acute inflammation, suppuration, caseation, necrosis, &c.

The parasites dealt with fall under the groups:— *Arachnida*, *Cestodes*, *Nematodes*, *Trematodes*, *Coccidia* and *Psorosperms*.

Arachnida.

But two parasites of this numerous group (*see* Mégnin) require attention here, viz., *Acarus scabiei* and *Acarus* or *Demodex folliculorum*.

Acarus scabiei.—**Fig. 122** represents the male and female forms, and their difference in size, amongst other characters, may be readily observed. Its action upon the skin is very varied (p. 252). Its presence may be associated with vesiculation, pustulation, eczema and a chronic warty condition. In the last two cases there is considerable epithelial and small round celled proliferation, increased cornification and desquamation. Its irritant action is attributed, so it is said, to the secretion of a poison.

Demodex folliculorum.—This parasite is regarded as one of the most harmless, and there is no doubt that it can often be found in the matter which may be expressed from the sebaceous glands. Sparks, however, drew attention to a very severe inflammation of the skin which it may cause in the dog. In these cases the follicles were observed distended with broods of the parasite. In man a similar distension of sebaceous acini may be observed in early acne pustules; later the epithelium degenerates, some of the nuclei proliferate, there is an abundant periacinar small round celled infiltration, and finally an abscess is formed with the parasites in the centre. But there is yet another property, which I think demodex will be found to possess in common with the other parasites, namely, that of inducing marked *hyperplasia*. I have examined fourteen cases of acne rosacea ("Lipoma nasi"), of the warty

tumour-like type, and have in every instance detected numbers of the parasites in the acini (*see* fig. 68). In all these cases there was considerable hyperplasia of the parenchyma, and a varying amount of periacinous connective tissue overgrowth.*

Cestodes.

The heads of the two common tapeworms, *Tænia mediocanellata* and *Tænia solium*, are illustrated in **Figs. 123** and **124**; their differences are marked; the absence of hooklets is especially observable in mediocanellata. There is another variety the *Bothriocephalus latus*, the head of which differs considerably from the above, in that it has two grooves running vertically, one on each side of the oval oblong head. The tissue changes which they may excite in the intestine are unimportant. This is not the case, however, with the hydatid forms. In the pig the *Cysticercus cellulosæ*, the hydatid form of Tænia solium, and in man and other animals the hydatid forms of the *Tænia echinococcus* (found in the dog) and of other species, may give rise to well marked changes. The wall of the common hydatid cyst in man is represented in **Fig. 125**; its laminated elastic character renders fragments of it readily discoverable under the microscope. Free in the fluid of the cyst—the *hydatid fluid*—may be found

* Like so many other tissue changes, the hypertrophy of the sebaceous follicles has been attributed to alcohol. This does not, however, accord with what we have already learnt concerning alcohol in the chapters on the liver and kidney. Alcohol should be known by the fact of its being often associated with parenchymatous degeneration and "atrophic proliferation."

Fig. 123. TÆNIA MEDIOCANELLATA

Obj. ⅔ in.

Fig. 124. TÆNIA SOLIUM

Obj. ⅔ in. (Carmine)

the characteristic *scolices*, **Fig. 126**, or their *hooklets;* attached to the wall may be numerous scolices or daughter hydatid cysts. In the ordinary course of events the hydatid becomes surrounded by a connective tissue capsule. In the liver, for example, the presence of the cyst causes in its vicinity the degeneration and atrophy of the liver cells, and often in addition, the proliferation of their nuclei; there is considerable connective tissue hyperplasia, and this gradually takes the place of the liver cells and forms a firm wall to the cyst. Very often indeed, where the irritation is more marked, the small round celled infiltration is greater and giant cell forms are by no means uncommon. The cysticerci which are occasionally found in the eye have also been described surrounded by small round and giant cells. In the liver of the cow the disseminated cysts of echinococcus multilocularis have produced the appearance of large tubercular foci; thus in one case there was *caseation* and *granulation tissue*, and some of the smaller cysts were completely surrounded by giant cells. Echinococcus multilocularis may also, when abundant in the liver, produce an extensive cirrhosis.* (For some further information, *see* p. 113).

Nematodes.

The numerous species of this class produce some of the most important and widespread lesions to which the system is subject. For example, acute and chronic *pneu-*

* This parasite has been found (Waldstein) forming beautiful cystic chains on the surface and in the interior of the liver; it was also found in the same case in a portal gland. The hydatids also give rise to occasional large colloid-like tumours, which indeed have been mistaken for colloid cancer.

monia and *pseudo-tuberculosis*, *enteritis*, simple and diphtheritic, *hæmaturia*, *chyluria* and the changes described under *Egyptian chlorosis*, *trichinosis*, and other affections.

Pneumonia verminosa and *pseudo-tuberculosis*.—Much has been written about the verminous lung diseases, which although common in the lower animals have only been occasionally met with in man (and the records of the latter are old). Alois Koch (1883) and Mueller (1889) have collected together very many cases and the literature of the subject. The parasites, which are introduced into the lungs by the respiratory passage, usually lead to bronchiectasis and saccular dilatation, atelectasis, miliary and diffuse pneumonia. An epidemic of broncho-pneumonia in dogs has been well described by Osler. This observer also drew attention to the paralysis of the hind quarters which supervened in some cases, and this phenomenon has been also noted by others in verminous diseases. In a case of chronic pneumonia verminosa, Eberth has described marked tissue proliferation, the muscular hyperplasia being especially manifest.

The *pseudo-tuberculoses* or *zooparasitical granulomata* are very instructive. There is nothing to add to Laulanié's interesting case in the lung described on p. 111, except it be to emphasize the fact that the parent parasites apparently inhabited the pulmonary artery; more usually the infection is bronchial and of these forms Mueller has figured and recorded numerous examples.* Ebstein and Nicolaier have described

* The condition is comparatively common in sheep and for material of this animal I am indebted to the kindness of Mr. Pemberthy Hey. I also have to express my thanks to Dr. Adami for most interesting specimens of pseudo-tuberculosis in the horse.



Fig. 125. WALL OF HYDATID CYST.

Obj. ¼ in. (Logwood.



Fig. 126. SCOLICES FROM HYDATID CYST.

An isolated scolex (⅛ in. obj.) and a group from an hydatid cyst.

miliary granulomata in the kidney of the dog, and it appears that Patrick Manson in 1877 observed a similar condition due to Filaria immitis. Lastly the reader is referred to Miura's striking case of pseudo-tuberculosis of the peritoneum and to the other facts mentioned on p. 112 and 113. The structure of the granulomata varies, in addition to the small round cells, giant cells are very common, but only in a few cases do they contain the parasites, more commonly they are in the neighbourhood; caseation and calcification is sometimes very marked; occasionally, however, there is considerable tissue hyperplasia.

In the trachea (Rabe) and in the portal vessels (Bollinger), a warty condition has been occasioned by nematodes. Cases of endarteritis and aneurism have also been recorded.

Enteritis and *diphtheritis verminosa*.—The familiar round worm—*Ascaris lumbricoides* and the thread worm —*Oxyuris vermicularis*, may give rise to intestinal catarrh. The former is sometimes rendered dangerous owing to its migratory habits; thus Kartulis describes a case in which the bile ducts were extensively invaded, and in consequence dilated and surrounded by an inflammatory zone. *Anguillula stercoralis* is occasionally a cause of catarrh in man, and according to Willach a *sclerostoma* (*anchylostoma*) in monkeys produces a diphtheritis of the intestine.

Anchylostoma disease or Egyptian chlorosis.—The cause of this disease is the *Anchylostoma* or *Dochmius duodenalis* which fixes itself in the wall of the intestine and produces considerable loss of blood and anæmia.

Trichinosis.—This important disease is the result of the *Trichina spiralis*. The worms reach their adult

stage in the intestine and then give rise to embryos which migrate to the striped muscles, chiefly those of the back and neck and the diaphragm.

In the intestine they may produce very severe enteritis and during their migration very severe symptoms or even death; in the muscles when not in excessive numbers they appear to produce little harm. **Fig. 127** represents a trichina in the characteristic coiled form it assumes in muscle. A trichina embryo enters a muscular fibre and causes a granular or hyaline necrosis of the contents; by its subsequent growth it produces a spindle shaped swelling and at the same time forms a chitinous investment for itself; the muscular fibres around become displaced and compressed, and occasionally there is some connective tissue as well as muscle nuclear proliferation; calcification of the capsule frequently occurs.

The *Filariæ* are a remarkable group of parasites, but much information is still needed concerning the exact nature of the tissue changes which they excite. Filaria medinensis or dracunulus medinensis (Cobbold), the guinea worm, gives rise to a very severe local inflammation beneath the skin. The adult form of the Filaria sanguinis hominis (Lewis), the *Filaria Bancroftii* gives rise according to Manson and others to a very wide range of changes, the interpretation of which seems still very difficult. Lymphatic obstruction seems to be one of the chief causes of the elephantiasis of the scrotum and leg which is sometimes observed. The adult parasites, but more especially the young embryos —the filaria sanguinis—which make their way into the lymphatic and general circulation are the causes of certain forms of *chyluria* and *hæmaturia;* whether the

Fig. 127. TRICHINA SPIRALIS IN MUSCLE.

Obj. $\frac{1}{8}$ in.



Fig. 128. FILARIA SANGUINIS HOMINIS.

Specimen in the urine

Obj. $\frac{1}{8}$ in.

chyle and blood come from the kidneys or from the bladder has not, however, been decided. In a most interesting case of hæmochyluria recorded by Stephen Mackenzie ("Path. Soc. Trans.," 1882) there was very extensive dilatation of the abdominal lymphatics. **Fig. 128** is a specimen of the blood kindly furnished by Dr. Mackenzie, to the description of whose case and to Manson's paper in the "Path. Soc. Trans." of 1881 the student is referred for further information.

Trematodes.

The various species of *Distoma* (flukes) produce in very many instances such marked tissue hyperplasia that this property has been by some considered characteristic. Two diseases may be discribed *Distomatosis* and *Bilharzia disease.*

Distomatosis.—It is again in the lower animals in which the effects of the various species of Flukes are most marked. Reference has been made, p. 291, to the extensive zooparasitical cirrhosis and tissue hyperplasia described by Zwaardemaker and others. **Fig. 130** represents two flukes in section in a bile duct. The mucous membrane of the duct is the seat of catarrh; there is abundant small round celled and epithelial hyperplasia and the fundi of the glands are dilated; there is an extensive cirrhosis around the ducts. Shaper lays great stress upon the glandular hyperplasia, describing a diffuse adenoma of the bile ducts, with a tendency in places to become malignant. On the other hand necrosis, hæmorrhage and abscess formation may occur. Cachexia is sometimes very marked.

Bilharzia disease.—The changes encountered in this disease are produced by the presence of the adult worms in the branches of the portal, mesenteric and vesical vessels, but more especially by the abundance of the ova in the mucous membranes of the intestine, bladder, ureters and pelvis; occasionally they are found in other organs such as the liver and kidneys (Kartulis). There may be hæmaturia, enteritis and cachexia. The mucous membranes may be the seat of hæmorrhagic and purulent inflammation; very often there is considerable tissue hyperplasia, polypoid vegetations being formed in the intestine and bladder. **Fig. 129** represents what are probably the ova of this parasite in the mucous membrane of the intestine. The adult male is about half an inch long and is thicker but slightly shorter than the female; the latter is usually represented in the gynæcophoric canal of the former.

Coccidia, psorosperms, &c.—Coccidia, such as are met with in the liver of the rabbit and occasionally in man, are minute sharply defined oval bodies which can readily be distinguished with the 1 in. obj.; they possess a very distinct shell and granular contents. They are common in the liver of the rabbit, where they usually form small white points in connection with the bile ducts. The size and structure of the lesions produced by them, however, varies considerably, just as it does in the case of the majority of parasites described in the preceding pages. Their presence in the bile ducts may be associated with an extensive cirrhosis of the liver (p. 291); or the bile ducts are dilated and the seat of marked small round celled and epithelial hyperplasia; or the inflammatory reaction is accompanied by extensive necrosis and caseation. Very often, how-

Fig. 129. OVA OF BILHARZIA.

Obj. $\frac{1}{8}$ in. (Light Osmic).

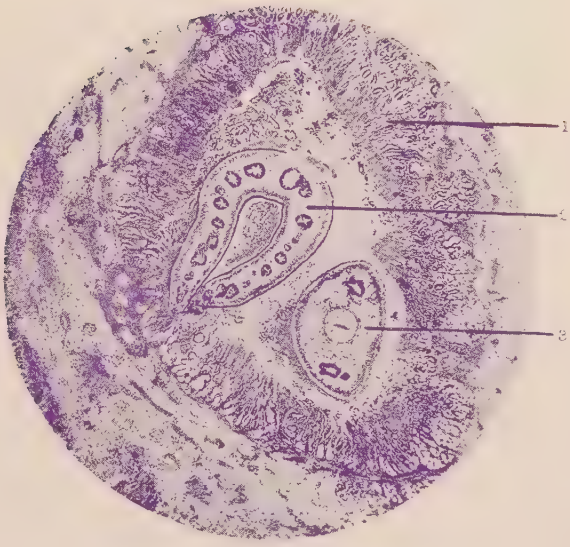

Fig. 130. BILE DUCT.

1 Glandular lining of bile duct infiltrated with small round cells
2 and 3. Sections of two Flukes.

Obj. $1\frac{1}{2}$ in., without eyepiece. (Lee wood).

ever, the parasites are found associated with beautiful cystic papillomatous changes in the ducts. In some of these cases the hyperplasia possesses very little of the character of an inflammatory reaction; moreover, coccidia can often be found in the epithelial cells lining the duct.*

Coccidia are not confined to the liver nor to the lower animals. We have incidentally referred to the *pulmonary gregarinosis* described by Baelz in man.

In 1888 Neisser described coccidia in *molluscum contagiosum*, but subsequent observations have not verified this statement. More importance, however, must be attached to the observations of Darier in 1889, who described under the heading of *cutaneous psorospermosis*, an acné sebacée concrète or acné cornée, in which the mouths of the sebaceous follicles were heaped up owing to epithelial and horny hyperplasia, whilst the fundi appeared normal.

In the proliferating epithelial cells of the mouth of the glands he found coccidia-like bodies, the presence of which was confirmed by Malassez and others. Recently Boeck has described a case of Darier's disease, in which he figures the parasites in question in the epithelial cells; they are of considerable size and cause distension of the cell, but they do not very closely resemble the familiar coccidia of the rabbit's liver. Shortly after his first observations, Darier described similar bodies in Paget's disease of the nipple, and later Wickham and Malassez examined five cases of the same disease with like results.

* It is worthy of note that the parasites, like the trichinæ and sarcosporidia (*see* later) which are capable of penetrating into the interior of the cells *excite remarkably little inflammatory reaction.*

As bearing upon the subject of the coccidia, it may be mentioned that the minute micro-, myxo-, sarco-sporidia and pseudo-navicellæ, which go to form Miescher's tubes or Rainey's corpuscles, are very common in the lower animals. They, like the trichinæ, enter the muscle fibres, where they as a rule produce only a very slight disturbance; occasionally, however, as Pütz has described (p. 365) there may be very considerable fatty and fibrous overgrowth, and cases accompanied by inflammatory reaction are also described by Siedamgrotzky and Leisering.

The results which may be safely deduced from the above observations on the coccidia, and with these may be included various other forms of sporozoa, are that psorosperms, possess in common with numerous other parasites, "irritative" properties, which sometimes lead to a necrotic inflammation, but more often to inflammatory hyperplasia. But endeavours have been made, stimulated by the above results of Darier and Malassez, to find a specific sporozoon for cancer, just as endeavours had been previously made to find a specific bacillus. In both cases rash statements have been made, without paying due regard to the fundamental differences which exist between the numerous varieties of tumours. But both the cultivation experiments, of Ballance and Shattock, of cancer on nutrient media, and the direct inoculation of cancer performed by Hanau, Klebs and others, argue against a specific organism. The sporozoa no doubt play their part in irritation, but there is no evidence to show that they are specific (comp. Shaper's observations on Distomatosis). We cannot yet dogmatise upon the nature of the irritation or other influences which seem so closely

bound up with tumours; nor can we yet interpret the meaning of the numerous bodies found in cancer cells.*

* The reader will find full information upon the latter in Steinhaus, "V.A.," B. 126, Dec. 1891, and Stroebe, "Path. Centrlb.," B. ii., 1891.

BIBLIOGRAPHY.

The following bibliographical notes will, it is hoped, encourage and enable the student to seek for further information.

The first great modern sifting and classification of pathological tissue changes was made by Virchow in his memorable "*Die Geschwülste*," and either the German or the French editions should be consulted. The same great pathologist founded the *Archiv für pathologische Anatomie*, which now numbers some 126 volumes. A separate index is published to the first 100 vols., and there are indexes in vols. 110 and 120. This work forms the most complete account of the progress of pathological morphology extant, all the greatest European pathologists having contributed. Progress was further marked last year (1891), by the leading representatives of pathology, in Virchow's *Festschrift*.

Text-books dealing with a wide range of subjects, and each having its own individuality, are those of Orth, Rindfleisch, Rokitansky, Broca, Billroth, Perls, Birch-Hirschfeld, Cornil and Ranvier, Stricker, Cohnheim, Paget, Klebs, and Ziegler. In 1889 and 1890 the completely remodelled Klebs and Ziegler appeared (German only) and the material and bibliography in them has reached encyclopædic proportions; both text-books will be found of the greatest service.

In 1868 the *Archives de Physiologie normale et pathologique* were founded by Brown-Séquard, Charcot, Vulpian, and later Joffroy. They represent the progress of pathology in France; two series have been issued and a third is in progress, an arrangement which leads to confusion; excellent indexes raisonnés are, however, published separately. In 1886 Ziegler founded, in conjunction with very many of the leading pathologists, the *Beiträge zur path. Anatomie*. In these the beautiful results of the various leading schools of pathology are fully detailed and illustrated. The index is in vol. x., heft 5. The well known *Transactions of the Pathological Society* have now reached 42 volumes, with separate indexes. They contain reports of an enormous amount of pathological material, but with few exceptions the articles are not sufficiently detailed or rich in literature. In the *Transactions of the Medico-Chirurgical Society*, 73 vols., there are several articles upon anatomical subjects, by the leading pathologists in England (index to first 50 vols). In

1889 the important *Archives de Médicine experimentale et de l'Anatomie pathologique*, and in 1890 the *Centralblatt f. allgemeine Pathologie u. path. Anatomie* appeared.

Of the greatest importance will be found the numerous papers on the pathological changes in disease, which are scattered throughout the numerous clinical journals; notably in the *Deutsche Archiv f. klinische Medicin*, *Zeitschrift f. klinische Med.*, *Zeitschrift für Heilkunde*, Langenbeck's *Archives*, Hutchinson's *Archives*, and the various surgical archives. Summaries are found in the *Centralblatt f. die med. Wissenchaft* and in the numerous *year books* (Virchow's and Hirsch's amongst others) and *quarter books*. In the *Archives f. exp. Pathologie und Pharmacologie* (29 vols.) the changes produced by toxic agents, &c., are recorded. In France the *Comptes Rendus* and *Transactions of the Academy* and of the *Biological*, *Anatomical* and other societies, and in England the *Proceedings of the Royal Society*, *Journal of Anatomy and Physiology*, *Quarterly Journal of Microscopical Science*, &c., may be consulted with advantage.

There exists a most detailed and special literature of the anatomical changes found in the great branches of Medicine. Thus for the nervous system, there are the *Archives f. Psychyatrie*, *Neurologisches Centralblatt*, Charcot's *Archives*, *Brain*, &c. For the skin both the French and German *Archives for Dermatology and Syphilis*, Leloir's and Unna's *works* and the English *Journal of Dermatology*. For the eye von Graefe's *Archives*. For the generative organs the *Zeitschr. f. Geburtsh. u. Gyn.*, *Archives f. Gyn.* and *Transactions of the Obstetrical Society*. There are still other periodical works upon the ear, larynx, urinary organs, &c. A large amount of material is deposited in the reports of the various London hospitals. Indices of pathological literature are found in the *Centralblatts*, in the *Index Medicus* and in Neale's *Medical Digest*. Long articles on most subjects are to be found in the encyclopædias, notably Eulenburg's, von Ziemssen's, the *Dict. encycl. des sciénces médicales*, in Volkmann's *Sammlung* and Reynold's *System of Medicine*.

The mycotic diseases have now for themselves the rich *Annales de l'Institut Pasteur*, the *Centralb f. Bakteriologie*, Baumgarten's *Yearbook* and C. Fränkel's and Pfeiffer's *Atlas*.

Diseases in the lower animals are represented by the *Archives f. wissen. u. prakt. Thierheilkunde* and *Deut. Zeit. f. Thiermedicin*.

Lastly the catalogues of the various London hospital museums, and notably those of the Royal College of Surgeons and of the Musée Dupuytren in Paris, will in very many instances be found of great use.

In the literature and notes which follow, and which are arranged according to the order of the chapters, an attempt is made to bring together only the more recent articles and works upon subjects of

anatomical interest. They may serve also, it is hoped, to indicate the nature of the work at present being done. With very few exceptions the author has had occasion to use them in the course of this work; at the same time they only represent a part of the material which it has been found necessary to go over. Records of isolated cases or of single pathological specimens, such for instance as primary tumours of the various organs, &c., have been purposely left out, as their literature is so great and so readily obtainable in the books and periodicals referred to above.

ABBREVIATIONS.

V. A. (Virchow's *Archiv*); P. S. (*Pathological Society's Transactions*); I. D. (Inaugural Dissertation, followed by name of University).

TECHNIQUE (p. 1-19).

Behrens, Kossel und Schiefferdecker, Das Mikroscop u. d. methoden der Mikroscop. untersuch., Braunschweig, 1889.

Fränkel, C. und Pfeiffer, Das Verfahren der photographischen Darstellung von Bakterienpräparaten, Berlin, 1889.

Israel, Practicum der Pathologischen histologie, Berlin, 1889.

Jakasch, Clinical Diagnosis: Bacteriological, Chemical, and Microscopical Evidence of disease, trans. by Cagney, London, 1890.

Krzywicki, Photograph. Abbild. Mikros. Schnitte, Zieg. *Beit.*, B. iii. See also **Roux,** *Ann. de l'Institut Past.*

Kahlden, Technik der histologischen Untersuchung path.-anat. Präparate, Jena, 1890.

Lee, Microtomist's Vade Mecum, London, Churchill, 1890.

Nauwerck, Sectionstechnik f. Studirende u. Aerzte, Jena, 1891.

Pringle, A., Practical Photo-Micrography, New York, 1890.

Riese, Technik der Golgi'schen Schwarzfärbung, &c., *Cent. f. Path. Anat.*, 1891.

Weigert, Bemerk. u. d. Neurogliagerüst des menschlichen Centralnervensystems, *Anat. Anz.*, 1890, No. 19.

INFLAMMATION (p. 20).

Bardenhauer, U. d. histolog. Vorgänge bei der durch Terpentin hervorgeruf. Entzündung, Zieg. *Beit.*, B. x.

Baumgarten, P., U. d. Herkunft der in Entzündungsherden auftretenden Lymphocyten, *Cent. f. path. Anat.*, 1890.

Cattani, U. d. Reaction der Gewebe auf specifische Reize, Zieg. *Beit.*, B. vii.

Coën, Path. Anat. Veränd der Haut nach Einwirkung von Jodtinctur, Zieg. *Beit.*, B. ii.

Dubler, Beitrag zur Lehre von der Eiterung, Basel, 1890.

Grawitz, Entzündung und Eiterung, &c., V. A., 108, 116, 118. *Deut. med. Woch.*, 1889.

Hohnfeldt, Histogen. der durch Staphylococcus hervorgeruf. Bindegewebs abscess, Zieg. *Beit.*, B. iii.

Janowski, U. d. ursachen der acuten Eiterung, Zieg. *Beit.*, B. vi.

Leber, Die Ensteh. der Entzünd. u. d. Wirkung der Entzündungserreg. Schädlichkeiten, Leipsig, 1891.

Neumann, Entzündungsbegriff, Zieg. *Beit.*, B. v.

Steinhaus, Die Ætiologie der acuten Eiterung, Leipsig, 1889.

Uskoff, Giebt es eine Eiterung unabhängig von niederen Organismen? V. A., 86.

Weigert, "Entzündung," *Real-Encyk.* v. Eulenburg.

Leucocytic Irritability, Phagocytosis and Immunity.

Ali-Cohen, La chemiotaxie comme adjuvant dans la rech. bact., *Ann. Inst. Past.*, 1890.

Baumgarten, U. d. Experimentum crucis der Phagocytenlehre, Zieg. *Beit.*, B. vii. and *Zeit. f. klin. Med.*, 1889. See also Buchner, *Münch. med. Woch.*, 1891 and Ribbert, *Deut. med. Woch.*, 1890.

Finger, Immunität u. Phagocytose beim Rotz, Zieg. *Beit.*, B. vi.

Gabritchewsky, Sur les propriétés chemiotactiques des leucocytes, *Ann. Inst. Past.*, 1890.

Massart et Bordet, La chemiotaxisme des leucocytes et l'infect. mycrob., *Ann. Inst. Past.*, 1891. Rech. sur l'irritabilité des leucocytes, *Ann. Inst. Past.*, 1890.

Metschnikoff, Etudes sur l'immunité, *Ann. Inst. Past.*, 1890 and 1891. U. d. Phagocytäre Rolle der Tuberkelriesenzellen, V. A., 113. *Ann. Inst. Past.*, 1887 and 1888. V. A., 113, 97, 109. Beit. zur vergleich. Path. der Entzündung, Virchow's *Festschrift*, 1891. **Hess,** V. A., 110.

Ruffer, Recherches sur la destruction des microbes par les cellules amiboides dans l'inflammation, *Ann. Inst. Past.*, 1889, and *Quar. Jour. Mic. Sc.*, 1890 and 1891.

Roux, L'immunité—immunité acquise et immunité naturelle, Hyg. Congress, London, 1891.

Tchistowitch, Sur les phénomènes de phagocytose dans les poumons, *Ann. Inst. Past.*, 1889. Pneumonie fibrineuse, 1890 and 1891.

Virchow, Der Kampf der Zellen u. der Bakterien, V. A., 101.

Ziegler, U. d. Ursuche u. das Wesen der Immunität des menschlichen Organismus gegen Infections-krankheiten, Zieg. *Beit.*, B. v.; and for further Literature see Ziegler's *Allg. Path.*, B. i.

INFLAMMATION AND REGENERATION.

1. Granulation Tissue and its Constituents (p. 38).

Kahlden. The share of the leucocytes in the new formation of tissue. Views of Ziegler, Marchand, Grawitz, Zahn and others, *Cent. f. path. Anat.*, 1890.

Nikiforoff, Bau u. Entwick. des Granulations-gewebes, Zieg. *Beit.*, B. viii. Fixed with Heidenhain's fluid, viz., Sat. Sol. of $HgCl_2$ in half per cent. Salt Solution, carefully washed, further hardened in alcohol and stained in Biondi's fluid (Grubler).

Ribbert, U. d. Betheiligung der Leucocyten an der Neubildung des Bindegewebes, *Cent. f. path. Anat.*, 1890.

Sherrington and Ballance, On formation of Scar Tissue, *Journal of Physiology*, vol. x., 1889.

The following are some of the phenomena associated with inflammation concerning which a few further remarks are necessary.

1. *Atrophic proliferation* (Flemming, Zahn, Heidelberg).—Proliferation, usually direct, of the nuclei, together with degeneration of the differentiated protoplasm of the special cell elements. This change may be observed in ordinary inflamed tissue, or when a tissue is rendered functionless (p. 336), or it may occur as a widespread process in cachectic and febrile conditions (typhoid, diphtheria, phthisis, &c.). Of this nature may be some cases of inflammatory leucocytosis and of increase of erythroblasts. It appears to be a reparative process.

2. *Reactive hyperplasia.*—The marked overgrowth, by direct and indirect division, of the tissue elements resulting from long continued irritation. The overgrowth may even assume a *malignant* character. Very numerous examples have been furnished in the text; the lymphadenoid hyperplasias in the intestine and of the lung are especially worthy of note. Some forms of leucocytosis may also fall in this group.

3. The phenomena which result from traumatic injury, or the temporary withdrawing of the blood supply, viz.:—The paralysis or death of the tissue corpuscles (*see* beautiful experiments of Lister on the early stages of inflammation, *Proc. Roy. Soc.*, 1857); the *dilatation of the vessels and the fluid and corpuscular exudation, and the other retrogressive tissue changes inseparably connected with the name of Cohnheim.*

4. The phenomena of infective inflammation. *Phagocytosis.*

5. The phenomena of *chemiotaxis* and *physiotaxis.*

6. The phenomena of *suppuration* and *caseation.*

7. The phenomena of *repair* and *absorption.*

Virchow regarded the cell increase in all inflammatory foci as a tissue reaction to a stimulus. And it is probable that this theory slightly modified includes most of the varieties of inflammation. It savours of a purposive reaction, rather than of the passive of Cohnheim, and as such brings itself nearer to the teachings of the Metschnikoff school. Of Virchow's pupils, Recklinghausen discovered the amœboid movements of some of the pus cells, whilst Grawitz maintains that suppuration depends upon the degree of inflammation, that pus corpuscles are also furnished by connective tissue cell elements and that it is not necessary to separate the retrogressive from the progressive tissue phenomena.

Cohnheim's teachings have been extensively adopted and his experiments repeated by a great number of observers, amongst them by Thoma. His pupil Ziegler attempted to prove by the well known experiments that the exuded leucocytes did perform a definite purpose, and that they built up new tissue. Weigert

maintained that the phenomena of karyokinesis which was observed in the inflammatory foci, indicated a new process, that of repair. He holds suppuration to be a special qualitative form of inflammation. Ziegler again set himself to work on the progressive phenomena of inflammation. The conclusions of his own work and that of his pupils Nikiforoff, Krafft, Podwzssozki, Coën and Fischer, were as stated at the Berlin Congress of 1890, that the leucocytes took no share in tissue forming. Sherrington and Ballance in the beautiful repetition of Ziegler's experiments came quite independently to similar conclusions; they would further separate the destructive and suppurative processes from the constructive and reproductive. Bardenheuer, of Marchand's laboratory, still more recently confirms the above results, but regards the progressive process as an integral part of inflammation, in that the changes succeed one another. The pus cells, moreover, according to this observer are exclusively furnished by the leucocytes. In the mean time observers, no doubt stimulated by Metschnikoff's results, began to lay considerable stress on the presence of Metschnikoff's makrophages (compare Sherrington and Ballance and Nikiforoff). Early in 1889 an interpretation of the large cells seen in fig. 5, whose presence had greatly puzzled me, was furnished by Ruffer's and Tchistowitch's observations on phagocytosis. A large number of observers regard these cells as derived from connective tissue corpuscles, others from the uninucleated leucocytes, and others again from both sources. Those who derive them from the connective tissue, say that they are capable of becoming fibroblasts. I have failed to convince myself of the latter, and incline to believe that they in common with the erythrophages, nekrophages, myophages and osteoclasts, represent a special cell element, perhaps the "plasma cell" (compare Sherrington and Ballance).

The subject of inflammation has been approached from a quite different standpoint by Metschnikoff, who, tracing step by step the process as it is seen in the various representatives of the animal kingdom and even in plants, shows how readily aggression becomes transformed into infection, defence and intracellular digestion into the phenomenon of phagocytosis. At the Hygiene Congress, London, 1891, he said, "the microbe by the aid of its toxine excites an inflammatory exudation and the arrival of a large number of leucocytes upon the battle-field, and the cells by the aid of their phagocytic properties eat the microbes." The pupils of Metschnikoff are exceedingly numerous and in this country include Ruffer. His doctrines, moreover, have been widely extended and have embraced the subject of immunity. They have, however, met with strong opposition notably by Baumgarten, Klein and Burdon Sanderson. The application and extension by Metsch-

nikoff and his pupils, of Pfeffer's experiments on chemiotaxis, have led to a most interesting series of observations, which try to explain the presence or absence of leucocytes in certain inflammations or their gravitation to dead tissue. There is no doubt that the results of both the Zoologist and the Botanist have thrown a new light upon the subject of inflammation.

The question of the origin of the various cell elements in the inflammatory focus, and of the phenomena of leucocytosis and erythroblastic changes, is an exceedingly difficult one, and sufficient data are not to hand to draw conclusions (*see* Ribbert and Baumgarten).

2. Absorption—Macrophages and Giant Cells.

Afanassiew, Path. der acuten u. chronic. Alcoholismus, Zeig. *Biet.*, B. viii., 1890 (describes the hepatophages of Podwyssozki).

Krauss, Riesenzellenbildung in epithelialen Gewebe, V.A., 95.

Litten, Resorpt. todter Muskelfasern, V. A. 80.

Langhans, Erythrophages, V. A., 49.

Lesser, Ueber das Verhalten des Catgut in Organismus u. ueber Heteroplastik, V. A., 95.

Marchand, Untersuch. ü. d. Einheilung von Fremdkörpern, Zieg. *Beit.*, B. iv., also M., V. A., 93.

Munk, Zur Lehre von der Resorption, Bildung u. Ablagerung der Fette in Thierkorper, V. A., 95.

Podwyssozki, Nekrophagismus u. Biophagismus, *Fortsch. der Med.*, 1889.

Pommer, U. die Ostoklastentheorie, V. A., 92.

Ribbert's Lab. 5 dissertations, Bonn, 1890: (1) Bleibtreu, Resorpt. von Blutextravasaten; (2) Kreuzberg, do. von zinnobar; (3) Mönkemöller, do. von Fett u. Gehirnmasse; (4) Mues, do. von Agar-Agar; (5) Siepen, Literaturübersicht u. zusammenfassung.

Sudakewitsch, Riesenzellen u. elastische Fasern, V. A., 115.

Ströbe, Kerntheilung u. Riesenzellenbildung im geschwülsten u. im Knochenmark, Zieg. *Beit.*, B. vii.

Senftleben. V. A., 79. Giant cells, &c.

Weiss, U. d. Bildung u. d. Bedeutung der Riesenzellen u. epithelartige Zellen, welche um Fremdkörper herum im Organismus sich bilden, V. A., 68. See also 65.

Zahn, Ueber das Schicksal der in den Organismus implantirten gewebe, V. A. 95.

3. Wounds and Repair (p. 60).

Leucocytes and Lymph Glands.

Arnold, Theilungsvorgänge an den Wanderzellen, ihre progressive u. regressive Metamorphosis, *Archiv f. mikr. Anat.*, 1887.

Eberth, Kern. u. Zellth. während der Entzündung u. Regenerat., Virchow's *Festschrift*, 1891.

Hansemann, Asymmetrische Zelltheilung in Epithelkrebsen u. deren biolog. Bedeutung, V. A., 119, 1890. Pathologische Mitosen, V. A., 123, 1891.

Hertwig, Ue. path. veränd. der Kerntheilungsprocesses in Folge exp. Eingriffe, Virchow's *Festschrift*, 1891.

Löwit, Neubild. u. Beschaffenheit der weissen Blutkörperchen, *Zieg. Beit.*, B. x. Also Reinke, Zieg. B. v.

Morburgo, Zellneubild. während der acuten Inanition des Organismus, *Zieg. Beit.*, B. iv.

Pfitzner, Ueber Theilungsvorgänge an den Leukocyten, ihre progressiven u. regressiven Metamorphosen, *Arch. f. mik. Anat.*, B. xxx., 1887.

Reinke, Exp. Untersuch. ü. d. Proliferat. u. Weiterentwik. der Leucocyten, *Zieg. Beit.*, 1889.

Ribbert, Regenerat. u. Entzündung der Lymphdrüsen, *Zieg. Beit.*, B. vi.

Vessels.

Apollonio, Mik. Untersuch. ü. d. Organisat. des Unterbindungsthrombus im den Arterien, *Zieg. Beit.*, B. iii.

Bonome, Heilung der aseptis. Herzwunden, *Zieg. Beit.*, B. v.

Ballance and Edmunds, Ligation of the larger Arteries, *Med. Chir.*, 1886.

Beneke, Die Ursache der Thrombusorganisation, *Zieg. Beit.*, B. vii.

Pekelharing, Endothelwucherung in Arterien, *Zieg. Beit.*, B. viii.

Thoma, Gefäss. u. Bindegewebsneubildung im der Arterienwand, *Zieg. Beit.*, B. x.

Bone.

Bonome, Knochenregeneration, V. A., 100.

Hertz, Repair of Enamel, V. A., 38.

Krafft, Histogenese des Periost. Callus, *Zieg. Beit.*, B. i.

Muscle.

Askanazy, Regenerat. der quergest. Muskelfasern, V. A., 125.

Robert, Versuche ü. d. Wiederbildung quergestr. Muskelfasern, *Zieg. Beit.*, B. x. 1891.

Viering, Regenerat. des Sehnengewebes, V. A., 125. Proliferation of the tendon corpuscles.

Nauwerck, Ue. Muskelregen. nach Verletzungen, Jena, 1890.

Nerve.

Büngner, Ue. d. Degenerations- u. Regenerationsvorgänge am Nerven, *Zeig. Beit.*, B. x.

Caporaso, Sulla regenerazione del midollo spinale della coda dei tritoni, *Zieg. Beit.*, B. v.

Coën, Die Heilung von Stichwunden des Gehirns, *Zieg. Beit.*, B. ii. See also Kahlden, *Cent. f. path. Anat.*, Sept., 1891.

Glands.

Meister, Regenerat. der Leberdrüse nach Entfernung ganzer Lappen, &c. *Cent. f. path. Anat.*, 1891, no. 23.

Martinotti, Hyperplasie u. Regenerat. der drüsigen Elemente in Beziehung auf ihre Functionsfähigkeit, *Cent. f. path. Anat.*, 1890.

Ribbert, Regenerat. des Schildrüsengewebes, V. A., 117.

Podwyssozki, Exp. Unter. über die Regenerat. der Drüsengewebe, *Zieg. Beit.*, B. ii.

Intestines.

Griffini u. Vassale, U. d. Reproduct. der Magenschleimhaut, Zieg. *Beit.*, B. iii.
Ritschl, Heilung von wunden des Magens, Darmkanals u. Uterus, V. A., 109.

DEGENERATIONS (p. 74).

Arnold, Die Geschicke des eingeathmeten Metallstaubes im Körper, Zieg. *Beit.*, B. viii.
Buchholz, Wachsartiger Degenerat. der Skeletmuskulatur, *Arch. f. Psych.*, 1891.
Burchardt, Eine neue amyloid färbung, V. A., 117.
Cornil, Note sur la dégéner. amyloide des organs étudiée au moyen de réactifs nouveaux, T. ii., 2nd series.
Eberth, Die amyloide Entartung, V. A., 80, and Kyber, V. A., 81.
Grawitz, Amyloide u. Hyaline Neubildung in der Nasenschleimhaut, V. A., 94.
Hindenlang, Pigmentinfilt. v. Lymphdrüsen, Leber u. anderen Organen in einem Fall v. Morbus mac. Werlhoffii, V. A., 79.
Klebs, Alg. Path., B. ii. Hyaline degenerations.
Langhans, Glycogen in path. Neubildungen, V. A., 120.
Marchand, Glycogen in striated muscle tumours and certain fœtal tissues, V. A., 100.
Mendelson, Guanin Gout in the Hog, *Int. Jour. of Med. Sci.*, 1888.
Neumann, Amyloiddegeneration des Fettgewebes, *Cent. f. path. Anat.*, 1890. Pathologische Pigmente, V. A., 111.
Raehlmann, U. hyaline u. amyloide Degenerat. der Conjunctiva, V. A. 87. See also Uhthoff, V. A., 86.
Skrzeczka, Pigmentbildung in Extravasaten, Zieg. *Beit.*, B. ii.
Stahel, Eisengehalt in Leber u. Milz nach versch. krankheiten, V. A., 85.
Stroebe, Neuere Arbeiten über Bildung freier Concremente und ihre organische Grundsubstanz, *Cent. f. path. Anat.*, 1890.
Variot, La mélanodermie congenit., *Arch. de Phys.*, 1887.
Vossius, Amyloide u. Hyaline degenerat. der Conjunctiva, Zieg. *Beit.*, B. iv. and v.
Weigert, Coagulationsnekrose, *Cent. f. path. Anat.*, Oct., 1891.
Ziegler, Amyloide Tumorbild. in der Zunge, V. A., 65.
See also other Systems.

MYCOTIC AFFECTIONS AND MALARIA (p. 98).

Textbooks.

Baumgarten, Lehrbuch der path. Myxologie, Jena, 1890.
Cornil et Babes, Les bactéries, &c., Paris, 1890.
Crookshank, Manual of Bacteriology, London, 1890.
Eisenberg, Bakteriologische Technik u. Diagnostik, Leipsig, 1891.
Fränkel, C., Grundriss der Bakterienkunde, Berlin, 1891.
Fränkel, C. and Pfeiffer, Mikrophotographischer Atlas der Bakterienkunde, Lieferungen in 1889, 1890, 1891.
Klein, Micro-organisms in Disease, London.
Kühne, Practical Guide to Demonstration of Bacteria in Tissues, Transl. V. D. Harris, London, 1890.

Macé, Traité pratique de Bacteriologie, Paris, 1889.
Flügge, New Syd. Soc., Watson Cheyne, 1890.
Watson Cheyne, New Sydenham Society, Essays on Microparasites in Disease.
Woodhead, Bacteria and their Products, London, 1891.

Microparasites and Fungi (*See also* Inflammation).

Alvarez, Le rhinosclérome, *Arch. de Phys.*, 1886.
Blanchard, Sur un nouv. type de dermatomycosis, *La Sem. Méd.*, 1890.
Bostroem, Untersuch. ü. d. Aktinomykose des Menschen, Zieg. *Beit.*, B. ix. Very complete lit., &c.
Dubreuilh, Les moisissures parasitaires de l'homme et des animaux, *Arch. de Méd. exp.*, T. iii., 1891.
Eisenlohr, Das Vaginae, Darm und Harnblasen-emphysem zurückgeführt auf Gasentwickelnde Bakterien, Zieg. *Beit.*, B. iii.
Eppinger, Ue. eine neue pathogene Cladothrix (Pseudo-tuberculosis), Zieg. *Beit.*, B. ix.
Fischer, Beit. z. Kennt. der Aktinomyk. Granulat, u. der Histolog. aktinomyk. Herde im Gehirn u. seinen Haüten, I.D., Tüb., 1887. Ref. Nauwerck, Zieg. *Beit.*, B. ii.
Grawitz, U. Schimmelvegetationen in thierschen Organisms, V. A., 81.
Langhans, Soor des Œsophagus, V. A., 109.
Paltauf, Mycosis mucorina, V. A., 102.
Rosenbach, U. Myocarditis diphtheritica, V. A., 70, plates.
Schemm, do. V. A., 121.
Rabot et Philippe, De la myocardite diphthéritique aigue, *Arch. de Méd. exp.*, T. iii., 1891.
Schubert, Zur Casuistik der Aspergillusmykosen, *Deut. Arch. f. klin. Med.*, 1885.
Schulthess, Rhinosklerom. *Deut. Arch. f. klin. Med.*, 1887.
Straus, Contrib. à l'anat. path. de la pustule maligne, *Ann. Inst. Past.*, 1887.
Verujski, Rech. sur la morph. et la biolog. du Trychophyton tonsurans et de l'Achorion Schoenleinii, *Ann. Inst. Past.*, 1887.
Wheaton, Aspergillus in Lung, P. S. 41, do. Bristowe, vol. 5.
Afanassiew, Beit. zur Path. der Malariainfect., V. A., 84. Pigment granules in the vessels.
Celli u. Marchiafava, Ue. d. Parasiten des rothen Blutkörperchens, Virchow's *Festschrift*, 1891.
Plehn, Malaria-Studien, Berlin 1890.

TUMOURS (p. 126).

Ætiology.

Beneke, Bemerkungen zur allg. Onkologie, Zieg. *Beit.*, B. ix.
Boegehold, Entwick. v. malignen Tumoren aus Narben, V. A., 88.
Franke, Beit. z. Geschwülstlehre, V. A., 121.
Friedländer, Ueber Epithelwucherung u. Krebs, Strassburg, 1877.
Hauser, in his Carcinom des Magens etc., 1890. Kritische Bemerkungen zur Aetiologie des Carcinoms, (1) Cohnheim's theory; (2) theory of infection; (3) Thiersch's hypothesis; (4) theory of irritation.
Heitter, Entwick. v. Krebs auf narbigen Graude im Magen u. in der Gallenblase. *Weiner med. Woch.* 1883.

Kuttner, Beziehung des Carcinoms zur Pachydermie, V. A., 121.
Leopold, Exp. Untersuch. ü. d. Aet. der Geschwulste, V. A., 85.
Stroebe, Neuere arbeiten uber histogenese u. Aetiologie des Carcinoms. *Cent. f. path. Anat.*, 1891. Good general summary.
Schleich, Infektion u. Geschwulstbildung, *Deut. med. Woch.*, 1891.
Virchow, Die Diagnose u. Prognose des Carcinom, V. A., 111.
Zenker, Der prim. Krebs der Gallenblase u. seine Beziehung zu Gallensteinen u. Gallenblasennarben, *Deut. Arch. f. klin. Med.*, B. 44.
Ziegler, Die neusten Arbeiten über vererbungs u. Abstammungslehre, &c., *Beit.*, B. iv., and Ue. d. ursachen der path. Gewebsneubildung, Virchow's *Festschrift*, 1891.
Schuchardt, Beit. z. Ensteh. der Carcinome aus chron. entzünd. Zuständen der Schleimhäute u. Hautdecken, Volkmann's *Sam.*, 1885.

Foreign Bodies in Tumours. Infectivity.

Carcinome et Sarcome ; critical review on the bacilli of, *Ann. Inst, Past.*, 1888.
Ackermann, Histogenese u. Histologie der Sarkome, Volkmann's *Sam.*, 1883.
Goldmann, Die künstliche Uberhäutung offener Krebse durch Hauttransplantationen nach Thiersch, *Cent. f. Path. Anat.*, 1890.
Klebs, Ueber das Wesen u. die Erkennung der Carcinombildung, *Deut. med. Woch.*, 1890, and *Centrb. f. Bak.*, B. ix., 1891.
Klein, Ue. d. Bezieh. der Russellschen Fuchsinkörperchen zu den Altmannischen Zellgranulis, Zieg. *Beit.*, B. xi.
Schütz, Ueber die Protozoen u. Coccidienartigen Mikroorganismen in Krebszellen, *Cent. f. Bak.*, ix., 91 (Frankfurt, 1890).
Siegenbech v. Heukelom, Ueber intercelluläre Gebilde in Carcinomen, *Cent. f. path. Anat.*, 1890.
Steinhaus, Carcinom-Einschlüsse, V. A., 126, Dec. 1891, illustrations, lit.
Stroebe, Zur Kenntniss versch. cellulärer vorgänge u. Erscheinungen in Geschwülsten, Ziegler's *Beit.*, B. xi. 91. Asymmetrical karyokinesis, phagocytosis, hyperchromatosis and parasites.
Volkmann, R., Ue. den prim. Krebs der Extremitaten, Volkmann's *Sam.*, 1889.

Congenital Tumours and Misformation.

Bruns, Branchiogene Carcinome ; *Mitth. u. d. Chir. Klinik. zu Tübingen*, I, 1884. Also Volkmann, *Cent. f. Chir.*. 1882.
Buttersack, Congenitale Knorpelreste am Halse, V. A., 106; and **Bidder,** V. A., 120.
Frobenius, U. einige angeborne Cystengeschwülste des Halses, Ziegler's *Beit.*, B. 6, 1889.
His, Offene Fragen der path. Embryologie, Virchow's *Festschrift*, 1891.
Israel, Angeb. Spalten des Ohrläppchens, V. A., 119.
Kostanecki and Mielecki, Die angeb. Kiemenfisteln des Menschen, V. A., 121.
Paget, Supernumerary Auricles and Persistent Ear Fistulæ, *Med. Chi.*, vol. 61.
Rehn, Beitrag z. Anat. der Halskeimenfisteln, V. A., 1875.
Ribbert, Eine verzweighte Halskeimenfistel, V. A., 90.
Samter, Keimengangsgeschwülste, V. A., 112.
Treves, Malignant cyst of the neck, P. S., 1887.

Coccygeal Region.

Buzzi, Angeb. Geschwülste der Sacrococcygealgegend, V. A., 109. Two good cases. Refers to Förster, Die Missbildungen des Menschen, Jena, 1861; Virchow, *Berl. klin. Woch.*, 1869; Ahlfield, *Archiv. f. Gynäk.*, B. VII and VIII; Braune, Geschw. der Sacrococcygealgegend Leipsig, 1862; Arnold, V. A., 50; Molk, Des tumeurs cong. de l'extremité inf. du tronc, Strassburg, 1868, &c.

Braune, Sacral tumours, V. A., 99, Lit. See also V. A., 58, Casuistik der Kreuzbeingeschwülste; Virchow, V. A., 100; also V. A., 101, &c.; Owen, P. S., 39, &c.

Freyer, Zur Casuistik der Kreuzbeingeschwülste, V. A., 58.

Jastreboff, Casuistik der angeb. Geschwülste u. der Gegend des Kreuzbeins, V. A., 99.

Middledorf, Congenital Sacral Tumours, V. A., 101.

Schmidt, U. d. Beziehungen der sogen. Steissdrüse zu den Steisstumoren, V. A., 112.

Various Regions.

Arnold, Behaarte polypen der Rachen Mundhole, &c., V. A., 111. See also **Hale White,** P. S., 43, and **Otto,** V. A., 115.

Bartels, Schwanzähnliche neubildung beim Menschen, V. A., 83; **Freund,** V. A., 104.

Bonnet, Die stummelschwänzigen Hunde im Hinblick auf die Vererbung erworbener Eigenschaften, Zieg. *Beit.*, B. iv.

Champneys, Supernumerary nipples, *Med. Chi.*, vol. 69.

Dinkler, Path. der sogen. schwarzen Haarzunge, V. A., 118.

Malassez, Le rôle des débris epithéliaux paradentaires, *Arch. de Phys.*, 1885.

Marc, Leiomyoma subcut. congenitum u. Notizen zur Statistik der Geschwülste bei Kindern, V. A., 125.

Neuner, Angebliche Chordareste in der Nasenscheidewand des Rindes, *Zeit. f. Thiermed.*, B. 12.

Vanlair, Granulome télangiectasique du corps vitré avec persistance de l'artère hyaloïdienne, *Arch. de Phys.*, T. vii., 2nd series.

Virchow, Teratoma myxomatodes mediastini, V. A., 88. Reference to striated muscle tumours, &c.

Teratology.

Chabry, Contrib. á l'embryologie norm. et térat. des ascidies simples, *Journal de l'anat. et phys.*, 1887.

Dareste, Production des Monstruosités, Paris, 1877.

Driesch, Entwicklungsmechanische Studien, *Zeit. f. Wiss. Zoolg.*, B. 53, 1891 (very interesting).

Gerlach, U. d. Entstehungsweise der vorderen Verdoppelung, *Deut. Arch. f. klin. Med.*, B. 42 and Doppelmissbildungen, Stuttgart, 1883.

Rauber, Die Theorien der excessiven Monstra, V. A., 71, 73 and 74. See also Roux, V. A., 104.

Panum, Path. bedeut. der angeb. Missbild., V. A., 72.

Ziegler, Alg. Path., B. I., 1890. **Ahlfeld,** Die Missbildungen, Leipsig, 1882. **Davaine,** *Dict. encycl. des sci. méd.* There are numerous large treatises.

Dermoid Tumours.

Böttlin, Zahnentwick. in Dermoiden, V. A., 115. An account of epithelial appendages. See also V. A., 108.
Doran, Abdominal Dermoids, *Med. Chi.*, vol. 68.
Godlee, Dermoid Cysts of the Chest, *Med. Chi.*, vol. 72.
Goldman, Eine ölhaltige Dermoid cyste mit Riesenzellen, Zieg. *Beit.*, B. vii.
Kolaczek, Peritoneale Metastasen eines Eierstockdermoids, &c., V. A., 75. See also Litten and Virchow.
Lannelongue, Sur les kystes dermoides intra-craniens, *Arch. de Phys.*, 1889.
Sutton, Dermoids, Lond., 1889.
Virchow, Auricular dermoid containing oil, V. A., 35.

Cystic Tumours.

Hosch, Exp. stud. über Iriscysten, V. A., 99.
Kruse, Entwick. cystischer Geschwülste im Unterkiefer, V. A., 124.
Lannelongue et Achard, Traité des Kystes congenitaux, Paris, 1886.

Lipomata.

Arnlold, Angb. Lipome der Zunge, V. A., 50.
Falkenstein, Aural lipomata, V. A., 71.
Sutton, B., Lipomata, *Med. Chir.*, vol. 68; and elsewhere.

Fibromata.

Hürthle, Beit. zur Kennt. des Fibroma molluscum u. der congenit. Elephantiasis, I. D. Tüb., 1886.
Jordan, Elephantiasis congenita, Zieg. *Beit.*, B. viii.
Lahmann, Die multip. Fibrome u. d. Neurofibrome, V. A., 101.
Recklinghausen, Die multiplen Fibrome der Haut, Berlin, 1882.
Westphalen, Multiple Fibrome der Haut u. d. Nerven mit Uebergang in sarcom u. Metastasenbildung, V. A., 110; and **Pomorski,** V. A., 111.

Myomata.

Christiani, Les tumeurs malignes des muscles striés, *Arch. de Phys.*, 1887.
Hess, Multiple dermatomyomata, V. A., 120; and **Judassohn,** V. A., 121.
Kolessnikow, Pigmented rhabdomyomata.
Lukasiewicz, Multiple Dermatomyomata, *Arch. f. Dermat. u. Syphilis*, 1891.
Prudden, Rhabdomyoma of the Parotid, *American Jour. of Med. Sc.*, 1883.
Rhabdomyomata. **Virchow,** myo-cysto-sarcoma of ovary, cystic hygroma; **Recklinghausen,** polypoid myoma of heart V. A., 35; **Virchow,** two cavernous myomata in heart, V. A., 30; **Buhl,** two rhabdomyomata of muscle; **Weber,** V. A., 39, in uterus; **Rudneff,** in vagina, V. A., 54.
Sokolow, Leiomyoma der Brustwarze, V. A., 58.

Granuloma Fungoides.

Donitz u. Lassar, Mycosis fungoides, V. A., 116. No metastasis.
Kaposi, Mycosis fungoides, *Wien. med. Woch.*, 1887 and 1888 (metastasis). Tumours of round and spindle cells, herpetiform spreading, spontaneous involution, mostly benign.
Ledermann, Mycosis fungoides, *Arch. f. Dermat. u. Syph.*, 1889.
Payne, Granuloma fungoides, P. S., 1886.

Tumours, various.

Balzer et Grandhomme, Les adénomes sébacés de la face, *Arch. de Phys.*, 1886.
Paget, S., Calcificat. of seb. adenomata, P. S., 41; Malherbe, *Arch. de Phys.*, T. viii., 2nd series; and Cystic Adenomata of Sebaceous Glands, V. A., 108; also V. A., 81. See also *Arch. de Phys.*, 1885.
Knauss, Eine Geschwulst der Schweissdrüsen, V. A., 120.
Eisenlohr, Beit. z. Kenn. des Glioms der Netzhaut, V. A., 123.
Glaeser, Cholesteatomata, V. A., 122.
Hutchinson, Acute Epithelial Cancer of Face, *Lancet*, 1889.
Israel, O., Epithelioma folliculare cutis, Langenbeck's *Archives*, 1892.
Kocher, Primares Achseldrüsencarc. nach chron. (carcinomatöser) Mastitis, V. A., 1878. Hyperplastic and carcinomatous mastitis with eczema.
Liborius, Casuistik der Mediastinaltumoren, V. A., 93.
Nélaton, D'une nouv. espèce de tumeurs benignes des os ou tumeurs à myéloplaxes, Paris, 1860.
Pilliet, Tumeurs mélaniques de la peau, du foie, de la dure mère, du cerveau, &c. *Arch. de Phys.*, 1887.
Recklinghausen, Ein Fall von Enchondrom mit ungewöhnlicher Multiplication, V. A., 118.
Rheinstein, Riesenzellensarcom des Endometrium, V. A., 124.
Rieke, Epibulbar tumours, *Arch. f. Augenheilk.*, B. xxii., 1890.

VASCULAR SYSTEM (p. 208).

Blood.

Foa, Neue Untersuch. ü. d. Bildung der Elemente des Blutes, Virchow's *Festschrift*, 1891.
Gostling, Increase of the number of White Corpuscles in Suppuration, *Med. Chir. Trans.*, 1886.
Hayem, Du Sang, Paris, 1889.
Joas, Ue. entzündliche Leukocytose, Zieg. *Beit.*, B. x.
Kelsch, Anat. path. des maladies palustres (enumerat. of blood corpuscles, &c.), *Arch. de Phys.*, T. iii., 2nd series.
Luzet, La régénération du sang après saignée chez les oiseau, *Arch. de Phys.*, 1891.
Muir, Contrib. to the Phys. and Path. of the Blood, *Journal of Anat. and Phys.* 1891.
Osler, Problems in Phys. of Blood Corpuscles, *Brit. Med. Jour.*, 1886.

Thrombosis.

Bizzozero, Ueber die Blutplättchen, Virchow's *Festschrift*, 1891.

Curschmann, Ueber ältere Thrombenbildungen im Herzen, *Deut. Arch. f. klin. Med.*, 1885.

Delépine, Polypi of the Ventricles and Cardioliths, P. S., 41, 90.

Eberth und Schimmelbush, Blutplättchen u. d. Blutgerinnung, V. A., 105 and 108.

Zahn, Ue. d. Rippenbildung an den freien oberflache der Thromben, Virchow's *Festschrift*, 1891.

Leukæmia and Leucocytosis.

Askanazy, Tuberculöse Lymphome, unter dem Bilde febriler Pseudoleukämie verlaufend, Zieg. *Beit.*, B. iii.

Eberth, Leukæmia in Mouse, V. A., 72, and **Bollinger,** in animals, V. A., 59.

Ebstein, U. d. acute Leukämie u. Pseudoleukämie, *Deut. Arch. f. klin. Med.*, 1889.

Gowers, Article, "Leukæmia," in Reynolds' *System of Medicine*. See also Fagge.

Limbeck, Einige neuere Arbeiten über Leukämie und Leukocytose, *Cent. f. path. Anat.*, Nov. 1891; *Zeit. f. Heilkunde*, 1889.

Mosler, Primary Lymphatic Leukæmia, V. A., 75. See also **Bizzozero,** V. A., 99; **Ponfick,** V. A., 67; **Böttcher,** V. A., 37, also vols. 78, 80, 83; and **Ribbert,** V. A., 102.

Vascular System generally.

Baumgarten, Gummoser arteritis cerebralis, V. A., 111. Change commences in the adventitia.

Beck, Zur Kennt. der Enst. der Herzruptur u. des chron. part. Herzaneurysmas, I. D. Tüb., 1886. Ref. von Ziegler in *Beit.*, B. ii.

Böttcher, Untersuch. ü. d. histolog. vorgänge u. das verhalten des Blutes in doppelt unterbundenen Gefässen, Zieg. *Beit.*, B. ii.

Bramwell, Diseases of the Heart, Edin., 1884.

Darier, Les vaisseaux des valvules du cœur chez l'homme à l'état normal et à l'état pathologique, *Arch. de Phys.*, 1888.

Eyrich, Verrucösen Aortitis, Zieg. *Beit.*, B. v.

Gull and Sutton, Changes in Vessels in Spinal Cord, P. S., 28; Arterio-capillary Fibrosis, *Med. Chi.*, vol. 55, &c.

Honegger, Beit. zur Kennt. der degenerat. u. entzünd. veränd. der Intima des Herzens und der grossen Gefässztamm, I. D. Zürich, 1882. Ref. von Zieg. seine *Beit.*, B. ii.

Johnson, Vessels in Bright's Disease, P. S., 33.

Latis, U. d. allgem. Alterationen an der Gefässen welche die Milzbrandinfection hervorbringt, *Cent. f. path. Anat.*, 1890.

Lewascheff, Exp. Untersuch. über die Bedeut. der Nervensyst. bei Gefässerkrankungen, V. A., 92. (L. after section of vascular nerves got connect. tissue overgrowth of the media, adventitia and intima, commencing first in the media).

Miura, Das prim. Riesenzellen sarcom der Aorta thoracica, Virchow's *Festschrift*, 1891.

Mögling, Ensteh. des hæmorrhag. Infarctus (historical), Zieg. *Beit.*, B. i.

Mott, On Cardio-vascular Nutrition, *Practitioner*, 1888.

Sack, Arteriosclerosis und phlebosclerosis, V. A., 112.

Thoma, Bindegewebsneubildung in der Arterien-intima, &c., V. A., 93, 104, 106; Compensatorische Endarteritis, V. A., 112; Untersuch. in Aneurysmen, V. A., 112 and 113.
Vogt, Aneurism, Eulenburg's *Real-Encyclop. d. ges. Heilk.* Change commences around the vasa vasorum.
Weichselbaum, Aet. u. path. Anat. der Endocarditis, Zieg. *Beit.*, B. iv.
Zahn, Untersuch. ü. Querrissen der Arterien-Intima u. Media, &c., V. A., 96.

Tumours of Vascular System.

Blumberg, Einen Krebsneubildungen in der vordern Hohlvenen in einen Kuh, *Zeit. f. Thiermed.*, B. 12.
Langhans, Cavernous Tumours, V. A., 75.
Paoli, Kennt. zur prim. Angiosarkome der Nière, Zieg. *Beit.*, B. viii.
Weil, Beit. z. Kennt. der Angiome, *Prager Vierteljahrsch.*, B. 133.

LYMPHATIC SYSTEM (p. 225).

Arnold, Kern u. Zellth. bei acuten Hyperp. der Lymphdrüsen im Milz, V. A., 75.
Hess, U. vermehrungs-u. Zerfallsvorgänge der grossen Zellen der acut. hyperp. Milz der weissen Maus, Zieg. *Beit.*, B. viii.
Martinotti, Acute Milzanschwellung bei Infectionskrankheiten, *Cent. f. path. Anat.*, 1890.
Coleman, Changes in the Lymphoid Tissue and Mesenteric Glands in Diphtheria, P. S., 1888.
Straus, Sur un cas d'ascite chyleux, *Arch. de Phys.*, 1886.
Murata, Chyluria, *Cent. f. d. med. Wissen.*, 1888.

Tumours of Lymphatic System.

Arnold, Cystic hygroma, &c., V. A., 33, Lit.
Baraban, Lymphangiomes et kystes séreux congénitaux, *Arch. de Méd. exp.*, 1889.
Hoggan, Lymphatiques de la peau dans l'infection cancéreuse, *Arch. de Phys.*, T. vii.
Kruse, Chylangioma cavernosum, V. A., 125.
Nieden, Lymphangiectasie mit Lymphorrhagie, V. A., 90.
Rasch, Chylous cysts of the mesentery, *Trans. Obst. Soc.*, vol. 31.
Richmond, Lymphatic obstruction, *Med. Chron.*, 1889.
Schmidt, Zur Kennt. der Lymphangiome, *Arch. f. Dermat. u. Syph.*, 1890.
Schuchardt, Sur Ensteh. d. subcut. Hygroma, V. A., 121.

PERNICIOUS ANÆMIA.

Rindfleisch, V. A., 121.
Geelmuyden, V. A., 105.
Cohnheim, V. A., 68.
Hunter, *Lancet*, 1888.
Mott, Iron in Liver of Pernicious Anæmia, P. S., 40, &c.

ADDISON'S DISEASE (p. 238).

Fleiner, Ue. den heutigen Stand der Lehre von der Addison'scher Krankheit, Volkmann's *Sam.*, 1892.

Kahlden, V. A., 114.

Leva, V. A., 125.

Lewin, Morb. Add. mit besonderer Berücksichtigung der eigenthümlichen Pigmentation der Haut, *Charité Annalen*, x.

Marchand, V. A., 81.

Roloff, Zieg. *Beit.*, B. ix.

Stilling, Quelques exp. nouv. sur la maladie d'Addison, Ref. in *Cent. f. path. Anat.*, 1891.

Supra-renal Bodies.

Alexander, Ue. d. Nebennieren u. ihre Beziehungen zum Nervensystem, Zieg. *Beit.*, B. xi.

Benecke, Zur Lehre von der Versprengung von Nebennierenkeimen in der Niere nebst Bemerkungen zur allgemeinen Onkologie, Zieg. *Beit.*, B. ix.

Marchand, Ue. d. access. Nebennieren im Lig. latum., V. A., 92; and Beit. zur Kennt. der normalen u. path. Anat. der glandula carotica u. der Nebennieren, Virchow's *Festschrift*, 1891.

May, Path. Anat. der Nebennieren, V. A., 108.

Rosenstein, Erkrankungen der Nebennieren, V. A., 84.

Schmorl, Zur Kennt. der access. Nebennieren, Zieg. *Beit.*, B. ix., and **Marchand,** V. A., 92.

Stilling, A., Compensat. Hypertrophie der Nebennieren, V. A., 118.

Tizzoni, Wirkungen der Extirp. der Nebennieren auf. Kaninchen, Ziegler's *Beit.*, B. 6, 1889.

Weichselbaum, Ganglionated Neuroma of Suprarenal, V. A., 85, 1881.

MYXŒDEMA (p. 239).

Bircher, Das Myxödem u. d. cretinische Degeneration, Volkmann's *Klin. Vort.*, No. 357, 1890.

Horsley, On the Function of the Thyroid Gland. A critical and historical review. Virchow's *Festschrift*, 1891.

Mosler, Ueber Myxœdema, Hahn's and Fürbinger's *Sammlung*, H. 14.

Myxœdema, *Report Clin. Soc. Trans.*, 1888. (**Ord, Horsley, Halliburton,** &c.).

Prudden, Myxœdema, Histology of, *Int. Jour. of. Med. Sc.*, 1888.

Thyroid.

Gley, The glandulæ parathyreoidæ (Sandström), *Arch. de Phys.*, 1892.

Hofmeister, Tissue changes after thyroidectomy, *Fortschritte der Medicin*, 1892.

Paltauf, Zur Kennt. der Schilddrüsentumoren im Innern des Kehlkopfs u. der Luftröhre, Zieg. *Beit.*, B. xi., 1891.

Recklinghausen, Bemerk. zu dem Aufsatz des H. Cohnheim's einfacher Gallertkropf mit metastasen, V. A., 70.

Rogowitsch, Veränd. der Hypophyse nach Entfernung der Schildrüse, Zieg. *Beit.*, B. iv.

Strekeisen, Morphologie der Schildrüsen, V. A., 103.

Stieeda, Ue. d. Verhalten der Hypophyse des Kaninchens nach Entfernung der Schildrüse, Zieg. *Beit.*, B. vii.

ACROMEGALY (p. 240).

Arnold, Acromegalie, Pachyacrie order Ostitis, Zieg. *Beit.*, B. x.
Erb, Acromegalie, *Deut. Arch. f. klin. Med.*, 1888.
Marie et Marinesco, Sur l'anat. path. de l'acromegalie, *Arch. de méd. exp.*, 1891. *Adenomatous Hypertrophy of the Anterior Lobe of Hypophysis.* Hypertrophy of the epithelium and epithelial appendages, vascular walls, nerve sheaths, &c.
Mosler, Ue. d. sogn. Acromegalie (Pachyacria), Virchow's *Festschrift*, 1891.
Recklinghausen, Ueber die Acromegalie, V. A., 119.
Souza-Leite, L'Acromegalie, Paris, 1890. Bibliography and allied bone diseases as Paget's, leontiasis, osteitis arthropathica, &c.

DISEASES OF BONE.

Rickets (p. 242).

Baginsky, Path. der Rachitis, V. A., 87.
Bode, Ue. die sogen. fötale Rachitis, V. A., 93.
Eberth, Die fötale Rachitis, Leipsig, 1878.
Goodhart, Hyperostosis, softening and rickety changes, P. S., 1883. See also Davies-Colley, P. S., 1884.
Kirchberg u. Marchand, U. d. sogen. fötale Rachitis (mikromelia chondromalacica), Zieg. *Beit.*, B. v.
Wilks, Rickets, P. S., 1881; Sutton, P. S., 34.

Osteomalacia (p. 244).

Hermann, Zur Frage der infantilen Osteomalacie, Zieg. *Beit.*, B. ii.
Hirschberg, Zur Kennt. der Osteomalacie u. ostitis malacissans, Zieg. *Beit.*, B. vi.
Langendorff und Mommsen, Osteomalacia, V. A., 69.
Ribbert, Senile Osteomalacia, V. A., 80.

Osteitis Deformans (p. 244).

Clutton, Osteitis deformans, P. S., 1888.
Lunn, A case of Osteitis Deformans, *St. Thom. Hosp. Reports*, vol. xiii.
Paget, Osteitis Deformans, *Med. Chir.*, v. 60.
Stilling, Osteogenesis imperfecta, V. A., 115; Osteitis deformans, V. A., 119.

Osteitis (p. 246.)

Cheyne, Tubercular Diseases of Bones and Joints, *Brit. Med. Jour.*, 1890.
Humphry, Senile Hypertrophy and Atrophy of Skull, *Med. Chi.*, 73.
Lane, Rheumatic Arthritis, P. S., 1886.
Sawtschenko, Osteitis u. Osteomyelitis leprosa, Zieg. *Beit.*, B. ix.
Schüller, M., Artificial Augmentation of Bone Growth, *Deut. med. Zeit.*, 1888.

Tumours, &c. (p. 248).

Bostroem, Ue. d. Ochronose der Knorpel, Virchow's *Festschrift*, 1891.
Fleischer, Knochenbildung in Bindegewebe, V. A., 80.
Paul, Calcification and Ossification of Vessels, P. S., 37; Cohn, V. A., 106.
Silcock, Ossification in Sinus Wall, P. S., 37.
Hagen, Z. Kennt. der Sternhölen-Osteome, *Tageblatt. der 62 Versam. deut. Naturforsche u. Aertze in Heidelberg.*
Gervais, De l'hyperostose chez l'homme et chez les animaux, *Jour. de Zool.*, 1875.
Multiple exostoses. Cohnheim, V. A., 38; Heuking, V. A., 77; Recklinghausen, V. A., 35. See also V. A., 88.
Pollard, Hypertrophied Callus or Osteosarcoma, P. S., 1885.
Roth, U. eine intracranielle Dental Exostose von einer Ziege, *Dis. Zürich*, 1888.
Nothnagel, Ue. eine eigenthüml. perniciöse Knochenerk.—Lymph. ossium, Virchow's *Festschrift*, 1891.

SKIN (p. 250).

Leloir et Vidal, Traité descriptif des maladies de la peau, liv. 1, 1889.
Crocker, Paget's Disease of Scrotum, P. S., 1889; and Diseases of the Skin, London, 1888.
Caspary, Ueber den Ort der Bildung des Haut-pigments, *Arch. f. Dermat. u. Syph.*, 1891. Also Halpern, do.
Elsenberg, Melanosis lenticularis progressiva, *Arch. f. Dermat. u. Syphilis*, 1890.
Harley, Atrophic Sclerema, *Med. Chi.*, 1877.
Kromayer, Ue. d. Deutung der von Herxheimer im Epithel beschriebenen Fasern, *Arch. f. Dermat. u. Syphil.*, 1890; and **Herxheimer,** 1889, do.; Path. Anat. der Psoriasis, *Arch. f. Dermat. u. Syphil.*, 1890.
Sutton, Congenital ichthyosis (a case), *Med. Chi.*, 1886.
Esoff, Beitrag z. Lehre v. der Ichthyosis u. v. den Epithelwücherungen bei derselben, &c., V. A., 69; Lupus erythematosus, *Arch. de Phys.*, 1890. In some cases hypertrophy of the sebaceous glands and cystic formation.
Pringle, Congenital Adenoma Sebaceum, *Brit. Jour. of Dermat.*, Jan., 1890.
Sangster, Molluscum contagiosum, *Med. Chi.*, vol. 63. See also Virchow, V. A., 33.
Stanziale, Anatomy and Experimental Researches in Molluscum Contagiosu *Giornale internaz. d. Scienze med.*, 1890. (Concludes is a new formation).
Thin, Multiple Warts, *Medico-Chir.*, vol. 64.
Pfeiffer, Die Verbreitung des Herpes Zoster, Jena, 1890. (Vascular and inf tive view); literature very full.
Weis, Ueber epidemischen Zoster, *Arch. f. Dermat. u. Syphilis*, 1890.

URINARY SYSTEM (p. 257).

Kidney.

Afanassiew, Path. anat. Veränd. in den Nieren u. in der Leber bei einigen mit hämoglobinuria oder Icterus verbund. Vergiftungen, V. A., 98.
Gayler, Histologie der Schrumpfniere nach chron. Bleivergiftung, I. D. Tüb., 1887, Nauwerck, Zieg. *Beit.*, B. ii.
Lesser, Act. of high temp., V. A., 93.

Litten, Path. Verkalkungen und Kalkmetastasen in den Nieren, V. A., 83.
Orth, Bilirubin in Kidney in Icterus neonatorum, V. A., 63.
Ligature of Ureters, **Charcot** and **Gombault,** *Arch. de Phys.*, 1881; **Strauss** and **Germont,** do. 1882; **Aufrecht,** *Cent. f. d. Med. Wiss.*, No. 19 and 35, 1878; **Popoff,** V. A., 82.
Cohnheim und Roy, Untersuch ü. d. Circulat. in den Nieren, V. A., 92.
Foa, Niereninfarcte (exp.) Zieg. *Beit.*, B. v.
Grawitz and Israel, Compression of renal Artery, V. A., 77.
Israel, O., Die anämische Nekrose der Nierenepithien, V. A., 123.

Nephritis.

Dunin, Anat. Untersuch. ue. Nierentzündung u. Morbus Brightii, V. A., 93, 1883. Much lit.
Ewald, Ue. d. Veränd. kleiner Gefässe bei Morb. Brightii, V. A., 71.
Greenfield, Diseases of Kidney, *New Syd. Soc. Atlas of Path.*
Held, Zur Kennt. ger glatten, weissen Schrumpfniere, Zieg. *Beit.*, B. vi.
Kahlden, Nephritis bei Phthisikern, *Cent. f. path. Anat.*, B. ii., 1891.
Langhans, Ue. d. enzünd. Veränd der glomeruli u. d. acute Nephritis, V. A., 99.
Nauwerck, Beit. z. Kenntniss des Morbus Brightii, Zieg. *Beit.*, B. i.
Sabourin, La cirrhose renale. Tumeurs du rein, *Archiv de Phys.*, T. ix., 2nde ser.
Thoma, Circulationsstorung in den Nieren bei chron. interst. Nephritis, V. A., 71.
Weigert, Die Bright'sche Nierenerkrankung, Volkmann's *Sammlung*, No. 162-163, 1879; Diphtheritic Nephritis, V. A., 91.
Stroebe, Histologie der congenit. Nieren-u. Lungensyphilis, *Cent. f. path. Anat.*, Dec. 1891. Recent lit.

Cysts and Tumours of Kidney.

Arnold, U. angeb. einseitige Nierenschrump. mit cystenbildung, Zieg. *Beit.*, B. viii.
Mackenzie, H. W., Cysts with Calcium Oxalate Stones, P. S., 1888.
Philipson, Renal cysts, V. A., 111.
Shattock, Cystic Disease, P. S., 1888: ditto **Murray.**
Williams, D., Changes in Hydronephrosis, P. S., 1888 (Dilatation of collecting tubules).
Beselin, Cholesteatomartige Desquamation im Nieren becken bei prim. Tub. derselben, V. A., 99.
Grawitz, Die sogen. Lipome der Niere, V. A., 93.
Ribbert, Myosarkom striocell. des Nerenbeckens u. des Ureters, V. A., 106.

Bladder, Ureters, etc.

Cahen, Casuistik der Blasentumoren, V. A., 113.
De Bary, Cyste in der Wand der weib. Harnröhre, V. A., 106.
Neelsen, Path. Anat. der Ureteren, Zieg. *Beit.*, B. iii.
Przewoski, Cystitis, Urethritis and Pyelitis Granulosa, follicularis or nodularis, V. A., 116.
Thompson, Tumours of the Bladder, London, 1884; Tumours of the Prostate, 1886.
Wutz, Ue. Urachus u. Urachussysten, V. A., 92.

DIABETES (p. 268).

Ebstein, U. Drusenepithelnekrosen mit besonderer Berucksichtigung des Diabete schen Comas, *Deut. Arch. f. klin. Med.*, B. 28.

Fichtner, Z. path. Anat. der Nieren beim Diabetes mellitus, V. A., 114; ditto **Pisenti,** *Cent. f. d. Med. wiss*, B. 23, and **Strauss,** *Arch. de Phys.*, 1887.

Pisenti et Acri, Rene diabetico, *Arch. de Med. exp.*, 1890.

Recklinghausen, Dwei Fälle von Diabetes mellitus, V. A., 30.

Straus, Les lésions hist. du rein dans le diabète sucré, *Arch. de Phys.*, 1887.

LIVER (p. 281).

Beloussow, Ue. d. Folgen der Unterbindung des Duct. choledochus, *Arch. f. exp. Path.*, B. 14.

Charcot et Gombault, Altération du foie par ligature du canal cholèd., T. iii, 2nd series.

Litten, Ligature of Bile Duct, *Charité Annalen*, vol. v.

Lomer, Ein Fall v. congenitaler partieller Oblit. der Gallengänge, V. A., 99.

Pick, Zur Kennt. der Leberveränd. nach Unterbindung des Ductus choled., *Zeitsch. f. Heilk.*, B. xi.

Legg, Wickham, Ligat. of Bile Duct, *St. Bart. Hosp. Reports*, 1873.

Osler, Oblit. of Portal Vein in Adult, *Jour. of Anat.*, vol. xvi.

Solowieff, Veränd. in der Leber unter dem einflusse Künstliche Verstopfung der Pfortader, V. A., 62.

Cohnheim u. Litten, Circulationstörungen in der Leber, V. A., 67.

Klebs, Multiple Leberzellen Thrombose, Zieg. *Beit.*, B. iii.

Birch-Hirschfeld, Icterus neonatorum, V. A., 87.

Halter und Lauterbacher, Lehre v. Icterus, Zieg. *Beit.*, B. x.; also **Lowit,** B. iv.

Stahel, Der Eisengehalt in Leber u. Milz nach verschied. Krankheiten, V. A., 85; (also Quincke, Nasse, Bistrow).

Butte, La fonction glycogénique du foie au moment de la mort dans quelques maladies, *Arch. de Phys.*, 1891.

Czerny, A., Rückbildungsvorgänge an der Leber, *Arch. f. mikr. Anat.*, B. 35.

HEPATITIS.

Ackermann, Die Histogenese u. Histologie der Lebercirrhose, V. A., 115; also V. A., 80.

Brissaud et Sabourin, Deux cas d'atrophie du lobe gauche du foie d'origine biliaire, *Arch. de Phys.*, 1884.

Brieger, Beit. z. Lehre von der fibrosen Hepatitis, V. A., 75.

Charcot et Gombault, Les differentes formes de la cirrhose du foie, *Arch. de Phys.*, 1876.

Dreschfeld, Histology of Cirrhosis of Liver, *Jour. of Anat.*, vol. xv.

Goodhart, Diseases of the Liver, *New Syd. Soc. Atlas*, 1883.

Klein, Acute Interstitial Hepatitis after Scarlatina, P. S., 28.

Kelsch et Wannebroucq, Cirrhose hypertrophique du foie, *Arch. de Phys.*, 1881.

Krönig, Die Genese der chron. interst. Phosphor-Hepatitis, V. A., 110.

Lewitski und Brodowski, Acute Yellow Atrophy, V. A., 70; also, **Waldeyer,** V. A., 43.

Luzet, La cirrhose hypertrophique graisseuse, *Arch. de Med. exp.*, 1890.
Moxon, Subacute and Acute Yellow Atrophy, P. S., 23; also Fagge, P. S., 20.
Nicati and Richaud, Biliary Cirrhosis in Rabbits, *Arch. de Phys.*, 1880.
Norman, H., Ein Fall v. deuter Leberatrophie, V. A., 91.
Raynaud and Sabourin, Obstruction and Peribiliary Cirrhosis, *Arch. de Phys.*, 1879.
Sabourin, La foie des tuberculeux, *Arch. de Phys.*, 1884; Variety of Hypertrophic Cirrhosis, *Arch. de Phys.*, 1881.
Wagner, Beiträge z. Path. u. Path. Anat. der Leber. *Deut. Arch. f. klin. Med.* 1884.

Tumours, etc.

Arnold, Zwei Fälle von primärem Angiosarkom der Leber, Zieg. *Beit.*, B. viii.
Gruber, Doppelte Nebenleber, V. A., 82; also Wagner, Accessory Livers, *Arch. der Heilk.*, 1861.
Jankowski, Veränd. in der Gallenblase bei vohandensein von Gallensteinen, Zieg. *Beit.*, B. x.
Payne, Vascular Tumours of Liver, Suprarenals and other Organs, P. S., 20.
Seigmund, Gallengangcystadenom, V. A., 115.
Zenker, Ue. prim. Krebs der Gallenblase u. seine Beziehung zu Gallensteinen u. gallenblasennarben, *Deut. Arch. f. klin. Med.*, 1889.

PANCREAS (p. 299).

Arnozan et Vaillard, Lésions provoquées par la ligature du canal de Wirsung, *Arch. de Phys.*, 1884. No glycosuria, dilatation of ducts, degeneration and final fibrosis.
Bowditch, Cancerous Disease of Pancreas and Liver, *Boston Med. and Surg. Jour.*, 1872.
Fitz, Acute Pancreatitis, *Bost. Med. and Surg. Jour.*, 1889.
Kesteven, Primary Carcinoma, P. S., 1889.
Langerhans, Pancreas Necrosis, *Cent. f. path. Anat.*, B. i., No. 16; also **Dittrich,** Eulenberg's *Vierteljahrssch.*, 1890; **Lancereaux,** *Bull. de l'Acad. de Méd.*, 1877; **Minkowsky and Mehring,** *Cent. f. klin. Med.*, 1890; **Otto Gerhardt,** V. A., 106.
Linnois et Lemoine, Contrib. à l'étude des lésions du pancréas dans le diabète, *Arch. de med. exp.*, T. III., 1891.
Martin, Ein Fall v. Pankreascyste, V. A., 120, with lit.
Senn, Volkmann's *Klin. Vorträge*, No. 313-314, 1888.
White, Hale, Primary Cancer of Pancreas, P. S., 1888.

PSORIATIC CONDITIONS OF MUCOUS MEMBRANES.

Butlin, Precancerous Conditions of the Tongue, *Brit. Med. Jour.*, 1889.
Hutchinson, Arsenic Keratosis followed by Cancer, P. S., 1888.
Kanthack, Schleimhaut des Neugb. kindes, &c., V. A., 120.
Leloir, Psoriasis Buccalis, *Arch. de Phys.*, 1887.
Posner, Pachydermia Mucosæ, V. A., 118.
Sangster, Psoriasis of the Tongue, P. S., 1882; Tables of Psoriasis of Tongue, P. S., 1882.

DISEASES OF THE ALIMENTARY TRACT (p. 305).

Mouth.

Esmarch, Ue. d. Aet. u. Diagnose der bösartigen Geschwülste, insbesondere derjenigen der Zunge u. der Lippen, Langenbeck's *Arch.*, B. 39.
Fränkel, E., Stomatitis Aphthosa, V. A., 113.
Kostanecki, Kennt. der Pharynxdivertikel, &c., V. A., 117.
Paget, S., Tumours of the Palate, P. S., 1877.
Treves, Vascular Tumours in Mouth and Tongue, P. S., 1888.

Stomach.

Chiari, Ueber Magen Syphilis, Virchow's *Festschrift*, 1891.
Fenwick, S., Wilson Fox and Handfield Jones, Diseases of the Stomach.
Ewald, C. A., Vorlesungen ù. d. Magenkrankheiten, 1888.
Fenwick, U. d. Zusammenhang einigen krankhaften Zustände des Magens mit anderen Organerkrankungen, V. A., 118.
Fränkel, E., Gastritis acuta emphysematosa, V. A., 118.
Fox, W., Contrib. to the Path. of the Glandular Structures of the Stomach, *Med. Chi. Trans.*, vol. 41.
Häberlin, Verbreitung u. Aetiologie des Magenkrebs, *Deut. arch. f. klin. Med.*, 1889.
Hauser, Das Cylinderepithel-Carcinom des Magens u. des Dickdarms, Jena, 1890.
Hanot et Gombault, La gastrite chronique, *Arch. de Phys.*, 1882.
Hudson, Hour-glass Constric. of Stomach, P. S., 1887, lit.
Langerhans, Gast. cat. chron. cystica proliferans, V. A., 116.
Lewy, Path. Anat. des Magens, Zieg. *Beit.*, B. iv.
Ménétrier, Des Polyadénomes gastriques et de leurs rapports avec le cancer de l'estomac, *Arch. de Phys.*, 1888.
Meyer, Zur Kenntniss der sogen. Magenatrophie, *Beit. f. klin. Med.*, 1889.
Openchowski, Z. path. Anat. der geschwürigen, Processe im Magendarmtractus, V. A., 117.
Roth, Exp. ue. d. Enstehung des runden Magengeschwürs, V. A., 45; also **H. Cripps,** P. S., 1882.
Schwalbe, Die Gastritis der Phthisiker, V. A., 117.
Smirnow, Gastritis membran. u. Diphtheritica, V. A., 113.
Wiktorowsky, Magengeschwür, V. A., 94.

Intestines.

Altmann, Hæmorrhagischer Infarcirung des Darmes, V. A., 117.
Boettcher, Darmmyome, V. A., 104.
Carbone, Adenomgewebe im Dünndarm, Zieg. *Beit.*, B. v.
Cripps, Adenoid Disease of the Rectum, P. S., 1881.
Edwards, Membranous Enteritis, *Int. Jour. of Med. Sc.*, 1888; **Goodhart,** P. S., 1872.
Kiener et Kelsch, La Dysenterie et Necroses, exp., *Arch. de Phys.*, 1884.
Luschka, Polypose vegatationen der gesamt. Dickdarmschleimhaut, V. A., 20; also **Handford,** P. S., 41, and **Bardenheuer,** Langenbeck's *Arch.*, B. 41.

Lubarsch, Ue. d. prim. Krebs des Ileum, V. A., 111.
Marchand, Zur Kennt. der Darmveränderung beim Typhus abdominalis, *Cent. f. path. Anat.*, 1890.
Ransom, Primary Carcinoma of the Ileum, *Lancet*, 1890.
Tauber, Veränd in Fälle von lange bestandenen Anus præternat, V. A., 89.
Treves, Tubercular ulcerat. in intestine, P. S., 88 (with stricture, &c.).

Salivary Glands.

Hanau, Ensteh. der eiterigen Entzündung der Speicheldrüsen, Zieg. *Beit.*, B. iv.

PERITONEUM.

Martin, Tuberculoses des séreuses et du poumon., *Arch. de Phys.*, 1880 (pseudo-tuberculosis exp.).
Payne, Fibrous Granulomata on Peritoneum like those of Liver and Spleen, P. S., 1870.
Pye-Smith, Cirrhosis of Liver with Chronic Peritonitis, P. S., 1882.
Rosenbach und Pawlowsky, Peritonitis, V. A., 117.

TOXIC DEGENERATIONS.

Alcohol.

Morbid Anatomy and Pathology of Chronic Alcoholism, P. S., 40.
Afanassiew, Z. Path. d. acuten u. chron. Alcoholismus, Zieg. *Beit.*, 1890, B. viii.
Dujardin-Beaumetz et Audigé, Rech. exp. sur l'alcoolisme chron., *Comp. Rend.*, 1883.
Schwalbe, U. d. narbenbildende, cirrhose, sclerose erzeugende Eigenschaft des Alcohols, V. A., 85.
Straus et Blocq, Etude exp. sur la cirrhose alcoolique du foie, *Arch. de Phys.*, 1887.

Lead, Mercury, etc.

Lead poisoning. See **Monakoff,** *Arch. f. Psych.*, B. x.; **Wyss,** V. A., 92; **Harnack,** *Arch. f. exp. Path.*, B. ix.; **Friedländer,** V. A., 75 (myopathic view); **Déjèrine,** *C. R. Soc. de Biolog.*, 1879.
Charcot et Gombault, L'Etude anat. de la néphrite saturnine exper., *Arch. de Phys.*, 1881.
Coën, The Microscopical Changes in the Tissues after Acute Lead Poisoning, *Cent. f. Path. Anat.*, B. ii., 1891 (scattered interst. and parench. changes); Sulle alterazioni istologiche dei reni, dei muscoli, dello stomacho, degl'intestini e del fegato nel avvelenamento cronico di plombo, Zieg. *Beit.*, B. xiii.
Déjèrine, Rech. du syst. nerv. dans la paralysie saturnine, *C. R. Soc. de Biolog.*, 1879.
Friedländer, Anat. Unters. eines Falles v. Bleilahmung, nebst Begrundung der myopath. Natur dieser Affection, V. A., 75 ("atrophic proliferation").
Gombault, Contrib. à l'hist. path. de l'atrophie musculaire saturnine, *Arch. de Phys.*, 1877.

Maier, Bleivergiftung. Magen u. Darm., V. A., 90.
Prevost et Binet, Rech. exp. sur l'intox. saturnine, *Rev. de Med. de la Suisse Romande*, 1889. In kidneys, granular atrophy, cysts and lime salts, peripheral neuritis, &c.
Fränkel, E., Toxische Enteritis in Folge der Sublimatwundbehandlung, V. A., 99.
Letulle, Rech. clin. et exp. sur les paralysies mercurielles, *Arch. de Phys.*, 1887.
Neuberger, Wirkung des Sublimats auf die Nieren b. Menschen u. beim Thiere, Zieg. *Beit.*, B. vi.
Prevost, Etude exp. relative à l'intox. par la mercure, *Rev. méd. de la Suisse Romande*, 1883.
Virchow, Mercuric Dysentery *Int. Jour.*, p. 213, 88.
Weichselbaum, Der gegenwärtige Stand unserer Kenntnisse ü. d. anat. Veränd. bei Quecksilbervergiftungen, *Cent. f. Path. Anat.*, 1891.

Silver.

Frommann, Ein Fall von Argyria mit Silberabscheidungen in Darm, Leber, Nieren u. Milz, V. A., 117.

Arsenic.

Filehne, Veränd. des Magens bei Arsenikvergiftung, V. A., 83.
Popow, U. d. Veränd. in Rüchenmark nach Vergift. mit Arsen. u. Blei, V. A., 93.

Phosphorus.

Ackermann, Phosphor. hepatitis, V. A., 115.
Ebstein, Changes in Phosphorus and Alcohol, V. A., 55 (exp.).
Roth, Sog. corrosive Gastritis bei acuter Phosph. u. Arsenikvergiftung, V. A., 45.
Wegner, Chronic Phosphorous Poisoning, &c., V. A., 55 (changes in bones, stomach and liver).
Ziegler und Oblonsky, Exp. Unt. ü. d. Wirkung des Arseniks u. Phosphors auf die Leber u. die Nieren, Zieg. *Beit.*, B. ii.

RESPIRATORY SYSTEM (p. 320).

Arnold, Untersuchungen u. Staubinhalation, Leipsig, 1885; Lung Anatomy, V. A., 80; Larynx, **Kanthack,** V. A., 117.
Cohnheim und Litten, Embolie der Lungenarterien, V. A., 65.
Cohn, Ein Fall von diffuser Knochen bildung in der Lunge, V. A., 101. See also **Luschka,** V. A., 10; **Förster,** V. A., 13; **Wagner,** *Arch. f. Phys. Heilk.*, B. iii.
Cox, Exp. Beitrag. zur path. Anat. der Lungenentzundung, Zieg. *Beit.*, B. v.
Chiari, U. einen neuen Typus von Missbildung der Trachea des Menschen, Zieg. *Beit.*, B. v.
Dorsch, Ein Fall von primären Lungenkrebs, &c., I. D., Tüb. 1881, ref. v. Nauwerck, Ziegler's *Beit.*, B. ii.
Eberth, U. Hyperplasie der Muskeln des Lungenparenchyms, V. A., 72; Zur Entwick des Epithelioms der Pia u. der Lunge, V. A.. 49.
Fleiner, Resorp. corpusculärer Elemente durch Lungen u. Pleura, V. A., 112.

Fraenkel, E., Rhinitis Chronica, V. A., 90.
Fränkel, Der Kehlkopfkrebs, seine Diagnose u. Behandlung., *Deut. Med. Woch.*, 1889.
Fischer, Feinern Veränd bei der Bronchitis u. Bronchiektasie, Zieg. *Beit.*, B. v., **Grawitz,** angeb. Bronchiectasie, V. A., 82.
Fox, Wilson, Atlas of Pathological Anatomy of Lungs, Lond. 1888; Diseases of Lungs, 1892.
Friedländer, Untersuch. u. Lungenentz, Berlin, 1873 (div. of vagi).
Hamburger, Ein diffuse verbreitetes Myxofibrom der knorpligen Nasenscheidewand, V. A., 117.
Hänermann, Pachydermie u. Geschwülstbildung auf dem Stimmbändern, Berlin, 1881.
Heidenhain, Beit. z. Frage nach den Ursachen der Pneumonie, V. A., 70.
Heymann, Epith. and Glands of Larynx in Health and Diseases, V. A., 118. See also **Posner,** do., **Kanthack,** V. A., 120.
Hanot et Gilbert, Bronchiectasis, *Arch. de Phys.*, 1884, and **Leroy,** 1887.
Grawitz, Congenital Bronchiectasis, V. A., 82.
Knauff, Das Pigment der Respirations organe, V. A., 39.
Kläsi, Anat. untersuch. u. d. Ensteh. des vesic. Emphysems, V. A., 104. Lit.
Kostanecki, Naso-pharyngeal Diverticula, V. A., 117.
Kromayer, Die sogn. Katarrhal-pneumonie nach Masern u. Keuchhusten, V. A., 117. Lit., &c.
Langhans, Primärer Krebs der Trachea u. Bronchien, V. A., 53; **Afanassiew,** V. A., 44.
Leroy, Nouv. rech. sur la path. des dilats. bronchiques, *Arch. de Phys.*, 1887.
Martin, Tuberculoses des séreuses et des poumons (exp.), *Arch. de Phys.*, T. vii. and viii., 2nd series.
Meyer, Congenital Cystic Formation in Lung, V. A., 16.
Perls, Zur Casuistik des Lungencarcinoms, V. A., 56.
Prudden, Relat. of Microbes to Pneumonia, *Int. Jour. of Med. Sc.*, 1889.
Recklinghausen, Fettresorption (Pleura), V. A., 26.
Ribbert, Lymphome der Lungen, V. A., 102.
Schuchardt, Hochgradige Atrophie der linken Lunge mit compensat. Hyp. der rechten, V. A., 101.
Simon, Angeborne Adenome der Luftröhrenschleimhaut beim Tiger, V. A., 57.
Weigert, Ausgedehnte umsch. mil. Tuberculose in grossen Lungenarterien, V. A., 104.
Weichselbaum, Papillary Adenosarcom. in Lung, V. A., 35.
Zahn, U. corpora amylacea der Lungen, V. A., 72.
Zenker, Staubinhalationskrankheiten der Lunge, *Deut. Arch. f. klin. Med.*, 1867.

GENITAL ORGANS AND BREAST (p. 342.)

Breast.

Altmann, Die Inactivitatsatrophie der weiblichen Brustdrüse, V. A., 111.
Brissaud, Anat. path. de la maladie kystique des mamelles, *Archiv. de Phys.* 1884.
Champneys, Supernumerary Mammæ, *Med. Chi.*, 1886.
Coën, Beit. z. norm. u. path. Anatomie der Milchdrüse, Zieg. *Beit.*, B. ii.
Jüngst, Myxoma mit hyaline degenerat., V. A., 95.
Labbé et Cöyne, Traité des tumeurs de la glande mammaire.

Langhans, Z. path. Hist. der weib. Brustdrüse, V. A., 58.
Leser, Beit. z. path. Anat. der Geschwülste der Brustdrüse. See also **Dreyfus,** V. A., 113.
Schmidt, Die Geschwülste der Brustdrüsen, *Beit. z. klin. Chir. v. Bruns.*, B. iv., 1889.
Schuchardt, Vergrösserung u. Tumoren der mannlichen Brustdrüsen, Lagenbeck's *Archives*, 1884 and 1885.
Schulthess, Stat. untersuch. u. d. æt. des Mammacarcinoms. *Beit. z. klin. Chir. v. Bruns.*, 1889.

Ovary.

Acconci, Hist. u. Histogenese der papillen. Kystome des Ovariums, *Cent. f. path. Anat.*, 1890.
Boettcher, Beob. u. d. Entwick. multiloculären Eiterstockcysten, V. A., 49.
Coblenz, Das Ovarialpapillom., V. A., 82.
Mackenzie, Ovarian Concretions, P. S., 40.
Malassez et de Sinéty, Sur la structure, l'origine et le dévelopment des kystes de l'ovaire, *Arch. de Phys.*, T. v.-viii., 2nd series.
Patenko, U. d. entwick. der Corpora fibrosa in Ovarien, V. A., 84.
Shattock, Columnar Epithelioma of Ovary, P. S., 1889.
Slavjansky, Z. norm. u. path. Hist. der Graaf'schen Bläschen des Menschen, V. A., 51.
Ribbert, Compensat. Hyp. der Geschlechtsdrüsen, V. A., 120.
Waldmeyer, Die epithel. Eierstockgeschwülste, insbes. die Kystome, *Arch. f. Gynäk.*, 1870.

Testis (p. 344).

Arnold, Ein Fall von glycogenhaltigem Myoma Striocellulare am Hoden, Zieg. *Beit.*, B. viii.
Jacobson, Z. path. Hist. der traumat. Hodenentzundung. exp. untersuch., V.A., 75.
Roth, Enstehung der Spermatocele, V.A., 68.
Terrillon et Schuchard, Sur la contusion du testicule, T. ix., 2nd series. See also T. vi., 2nd series.

Fallopian Tubes (p. 347).

Bandl, Die Krankheiten der Tuben, der Ligamente, &c., Stuttgart, 1886.
Fowler, Pyosalpinx in uterine cancer, *Med. Soc. Proc.*, London, vol. vii.
Kaltenbach, Stenose der Tuben mit consecutiver Muskelhypertrophie der Wand, *Cent. f. Gyn.*, 1885.
Doran, Papilloma of Fallopian Tubes and Ovaries, P. S. 1888 (references).
Martin, U. Tubenerkrankung, *Zeit. f. Geb. u. Gyn.*, 1887.
Orthmann, Beit. z. normalen Hist. u. zur Path. der Tuben, V. A., 108.

Uterus (p. 347).

Doran, Fibro-myomata of Ovarian Ligament, P. S., 38; Myoma and Fibromyomata of the Uterus and Allied Tumours of the Ovary, *Trans. Obst. Soc.*, vol. 29.

Krzywicki, Urogenitaltuberculose, Zieg. *Beit.*, B. iii.; also **Uhland,** B. ii.

Liebman, Ein Fall von Myocarcinom des Uterus, V. A., 117.

Ooblenz, Genese u. Entwick. von Cystomen der weib. Sexualorgane, V. A., 84.

Pernice, U. ein traubiges myosarcoma striocellulare uteri, V. A., 113. Lit.

Ruge u. Veit, Der Krebs der Gebärmutter, 1881.

Zeller, Stratification of Uterine Mucous Membrane, *Zeits. f. Geb. u. Gyn.*, 1888.

Williams, J., Cancer of the Uterus, London, 1888.

Vagina (p. 347).

Frick, Zwei Fälle von primären Scheidensarcom bei klinen Kindern, V. A., 117, and **Kolisko,** Das polypose Sarcom der Vagina im Kindesalter, *Wien. klin. Woch.*, 1889; **Hauser,** V. A., 88.

Jacob, Kystes vascularis du vagin, *Arch. de Phys.*, 1888.

Neumann, U. d. klin. u. hist. veränd. der krankten Vaginalschleimhaut, *Arch. f. Dermat.*, 1889.

Veith, Vaginalepithel u. Vaginaldrüsen, V. A., 117. Lit.

Urethra (p. 343).

Finger, Beiträg. z. path. Anat. der Blennorrhoë der männl. Sexualorgane., *Arch. f. Dermat. u. Syphilis*, 1891.

Neelsen, Histo. Veränd. in der chron. entzünd männlichen Urethra, *Wien*, 1888.

Niehus, Cavernitis Chronica, V. A., 118.

Heiberg, Die prim. Urogenitaltuber. des Mannes u. Weibes, Virchow's *Festschr.*, 1891.

Accessory Genital Glands (p. 342).

Coën, Adenom der Bartholin'scher Drüsen, Zieg. *Beit.*, B. viii.

Langerhans, U. d. accessorischen Drüsen der Geschlechtsorgane, V. A., 61.

Luschka, Das vordere Mittelstuck der Prostata u. d. Aberration derselben, V. A., 34.

Recklinghausen, U. d. Ranula, die Cyste der Bartholin'schen Drüse, u. d. Flimmercyste der Leber, V. A., 84; very detailed lit., &c.

Stilling, Beob. über d. Function der Prostata u. über die Entstehung der prostat. Concremente, V. A., 98.

Thompson, Diseases of the Prostate, Lond. 1886.

MUSCLE AND TENDON (Chap. XIX., p. 365).

Busachi, Hypertrophie u. Hyperp., Regenerat. u. Neoplasie von glatten Muskelgewebe, Zieg. *Beit.*, B. iv.

Robert, Versuche u. d. Wiederbildung quergestr. Muskelfasern, Ziegler's *Beit.*, B. x., 1891. Full lit. The following references;—Nuclear prolif. of fibres in neighbourhood of tumours (**Billroth, Sick, Waldeyer, Sokolow**); in certain infectious diseases (**Popoff**); in muscle atrophy (**Kölliker, Förster, Cohnheim**); in phthisis (**Fränkel**); pseudohyp. (**Eulenberg**); prog. mus. atrophy (**Friedreich**); nerve section (**Bizzozero and Golgi**); after tenotomy (**Schäffer, Kraus**).

Nauwerck, Muskelregenerat. nach Verletzungen, Jena, 1890.
Ginsberg, Entzündung u. Regenerat. der Sehnen, V. A., 88.
Krauss, Beit. z. Muskelpath. Histol. u. Chem. nach Tenotomie u. Neurotomie, V. A., 113.
Arnold, U. d. Vorkommon heller Muskeln beim Menschen, Heidelberg, 1886.

Degenerations.

Beneke, Wachsartige degenerat. der glatten Muskelfas., V. A., 99.
Popoff, Veränderungen des Muskelgewebes bei einigen Infectionskrankheiten, V. A., 69, History, &c.
Waldeyer, Veränd. d. quergest. Muskeln bei der Entzündung u. d. Typhusprocess, sowie u. d. regenerat. derselben nach substanzdefecten, V. A., 34 ("atrophic proliferation").
Zenker, U. d. Veränd der willkürlichen Muskeln in Typhus abd., Leipsig, 1864 (Virchow had previously described changes).

Atrophy, Hypertrophy, Lipomatosis.

Bernhardt, Muskelsteifigkeit u. Muskelhypertrophie ein selbständiger Symptomcomplex, V. A., 75.
Erb, Thomsen'sche Krankheit, Leipsig, 1886.
Eulenburg, Lipomatosis luxurians an den untern u. progress. Muskelat. an den obern Extrem., V. A., 49; also *Berl. med. Gesellschaft*, B. i., 1886.
Pütz, Fibroide Pseudohyp. vieler Skeletmusk. eines Pferdes bei Anwesenheit Miescher'schen Schläuche, V. A., 109; full lit.
Auerbach, Ein Fall von wahrer Muskelhypert. V. A., 53.
Barth, Beit. z, Kennt. d. Atrophia muscularis lipomatosis, *Arch. de Heilk.*, 1871.
Dähnhardt, Bemerk. z. Lehre von der Muskelatrophie, *Neurolog. Cent.*, 1890.
Schultze, U. Atrophia muscularis pseudohyp., V. A., 75. No nuclear prolif.
Fiedler, U. d. Kernwucherung in der Muskeln bei der Trichinenkrankheit, V. A., 30.
Fränkel, E., U. veränd. quergestr. Muskeln bei Phthisikern, V. A., 73.

NERVOUS SYSTEM (p. 369).

General.

Lewis, Bevan, Mental Diseases with Special Ref. to the Path. Aspects of Insanity, Lond., 1889.
Blocq et Londe, Anat. path. de la moelle épinière, Paris, 1891. Atlas with photogravеures.
Eichorst, Beit. z. Path. der Nerven u. Muskeln, V. A., 125.
Gowers, Diseases of Nervous System, Spinal Cord, vol. i., 1892.
Kesteven, Histology of Spinal Cord, *St. Bart. Hosp. Reports.*
Obersteiner, Anat. of Central Nervous System, trs. by Hill, London, 1891.
Weigert, Path. Hist. der Neurogliafasergerüsts, *Cent. f. path. Anat.*, 1890; Nerve Tissue Staining, *Anat. Anzeiger*, 1890, No. 19. Also *Cent. path. Anat.*, B. i., No. 3.

Congenital Formations, &c.

Achard, Duplicité part. du canal central, *Journ. des conn. Méd.*, 1889.
Kronthal, Doubling of the Cord, *Neurolog. Cent.*, 1890.
Fürstner und Zacher, Partial Doubling of Cord, *Arch. f. Psych.*, B. 12.
Pick, U. d. Enst. eines merfach. Centralkanals, *Arch. f. Psych.*, 1878.
Gaskell, The Origin of the Central Nervous System of Vertebrates, *Brain*, 1889.
His, Zur Geschichte des menschlichen Rückenmarkes u. der Norvenwurzeln, Leipsig, 1886; do. Die Neuroblasten, &c., Leipsig, 1889.
Sherrington, Outlying Nerve Cells in the Mammalian Spinal Cord, *Phil. Trans.*, vol. 181.

Pigmentation.

Erlitzky, Melanose de la moelle épinière dans la paralysie prog., *Arch. de Ph.*, 1881.
Mohnike, Pigment in the Spinal Arachnoid, V. A., 16.
Tschisch, Kunstliche Bildung v. Farbstoff im Nervengewebe, V. A., 97.
Virchow, Pigment u. diffuse Melanose der Arach., V. A., 16.

Degeneration and Regeneration.

Cramer, Faserschwund im Grosshirn, *Cent. f. path. Anat.*, 1890.
Eichorst, Regenerat. u. Degenerat., *Zeit. f. klin. Med.*, 1880.
Fürstner und Knoblauch, Faserschwund u. Kerntheilungsvörg. im Rüchenmark, &c., *Arch. f. Psych.*, B. 23.
Müller, H., Regenerat. d. Wirbelsäule u. des Rückenmarkes bei Tritonen u. Eidechsen. *Abh. der Senckbergischen naturf Gesell.*, 1864-65.
Pick, Cystöse Degenerat. des Gehirns, *Arch. f. Psych.*, 1890.
Roth, Varicöse Hyp. der Nervenfasern des Gehirns, V. A., 58; Zur Kennt. der varicösen Hypert. der Nervenfasern, V. A., 55. Lit. See also **Obermeier,** V. A., 58.
Redlich, Amyloidkorp. des Nervensyst., *Jahrb. f. Psych.*, B. 10.
Schultze, Kleinhirnschwund, V. A., 108.

Paralysis of the Insane, Changes in.

Dagonet, Dégènerescence hyaloide dans la Paralysie général progr., *C. R. Soc. Biolog.*, 1890.
Kronthral, Degenerat. d. Gefässcapillaren bei der progress. Paralyse der Irren, *Neurolog. Centr.*, 1890 (hyaline changes).
Meschede, U. d. fettig-pigmentose Degenerat. der Ganglienzellen des Gehirns in der paralytischen Geisteskrankheit, V. A., 56.
Mendel, Die path. Anat. der Dementia paralytica, *Neurolog. Cent.*, 1890. (Enceph. interstitialis diffusa mit ausgang in Hirnatrophie).
Tigges, Path. anat. Untersuch. z. Dementia paralytica, *Alg. Zeit. f. Psych.*, B. 20,

Changes after Nerve Division.

Barbacci, Die secundären, system. aufst. Degenerationen des Rüchenmarks, *Cent. f. path. Anat.*, B. ii., 1891.

Büngner, U. d. Degenerations-u. Regenerations-vorgänge am Nerven nach verletzungen, Zieg. *Beit.*, B. x., 1891. Lit. up to date.

Mott, Proc. Roy. Soc., 1892.

Otti und Rossi, Results of Sect. of Post. Roots, &c. (Ref.) *Cent. f. path. Anat.*, Dec. 1891.

Singer u. Münger, Beit. zur Anat. des Centralnervensystem (Results of Section of Roots, &c.), *Cent. f. path. Anat.*, 1891.

Tooth, Secondary Degeneration of Spinal Cord, London, 1889.

Amputations.

Dickinson, On the Changes of the Nervous System after Amputation, *Jour. Anat. and Phys.*, 1868.

Edinger, Changes in Nervous System in Congenital Absence of Limbs, V. A., 89. Lit.

Hayem et Gilbert, Note sur la modification du syst. nerveux chez un amputé, *Arch. de Phys.*, 1884.

Homen, Veränd. des Nervensyst. nach Amput., Zieg. *Beit.*, B. viii., 1890. Lit.

Myelitis.

Blumenthal, Rückenmarkscompression, *Phy. med. Gesellschaft an der Moskauer Univ.*, Dec. 1888.

Friedmann, Studien z. path. Anat. der acuten Encephalite, *Arch. f. Psych.*, xxi.

Joffroy et Achard, Cont. à l'anat. path. de la paralysie sp. aigue de l'enfance, *Arch. de med. exp.*, 1889.

Kahler, U. d. Veränd. in Rückenmark in Folge einer geringgradigen Comp., *Zeit. f. Heilk.*, B. iii., 1882.

Nauwerck, Rückenmarks Erweichung, Ziegler's *Beit.*, B. ii.

Rosenbach und Schtscherbach, Gewebesveränd in comp. myelitis, V. A., 122.

Schmaus, Beit. z. path. Anat. des Rückenmarkserschütterung, V. A., 122; die comp.-myelitis bei Caries der Werbelsäule, *Path. Anat. u. exps.*, Wiesbaden, 1890.

Scleroses.

Babinski, La sclérose on plaques et l'etude compar. des varietés des scleroses de la moelle, *Arch. de Phys.*, 1885.

Tuke, Batty, Miliary Sclerosis, &c., in Brain and Sp. Cord of the Insane, *Brit. and Foreign Med. Chi. Review*, 1873.

Buss, Beit. z. Aet. u. Path. der multiplen sclerose des Hirns u. Rückenmarkes, *Deut. Arch. f. klin. Med.*, B. 45 (vascular origin).

Chaslin, Scléroses nevrogliques, *C. R. Soc. de Biolog.*, 1889; and *Arch. de Méd. exp.*, 1891.

Déjèrine, Du rôle joué par la méningite post. des tabetiques dans la path. des scléroses combinées, *Arch. de Phys.*, 1884.

Tabes Dorsalis and Friedreich's Disease.

Ergotin Poisoning and Tabes. **Siemens,** *Arch. de Psych.*, B. xi., **Tuczek,** ditto, B. xiii. and xviii.

Adamkiewicz, Die feine veränd. u. der degenerirten hinterstrangen eines Tabeskranken, *Arch. f. Psych.*, B. x.

Bullen, Path. Anatomy of a case of Tabes, *Brain*, 1889.

Flechsig, Ist die Tabes dorsalis eine System Erkrankung? *Neurolog. Cent.*, 1890.

Hanot, Mal. perf. avec atax. locom., *Arch. de Phys.*, T. viii., 2nd ser. See also **Joffroy** (loss of nail), T. ix.

Krauss, Path. Anat. der Tabes dorsalis, *Arch. f. Psych.*, 1891.

Leyden, Tabes Dorsalis, *Real-Encyc.*, B. 13, good paper.

Nonne, Anat. Unters. von 10 Fällen von Tabes dorsalis, *Cent. f. path. Anat.*, 1891.

Oppenheim u. Siemerling, Path. der Tabes u. der periph. Nervenerkrank., *Arch. f. Psych.*, B. 18.

Pierret, Early Ataxy, *Arch. de Phys.*, 1871.

Pick, Zur Lehre von den Tabesformen des Kindesalters, *Zeit. f. Heilk.*, 1891.

Raymond, Contrib. à l'anat. path. du tabes dorsalis, *Rev. de Méd.*, Jan. 1891.

Strümpell, Path. Anat. der Tabes dorsalis, *Arch. f. Psych.*, xii.

Friedreich, Ueber Ataxie, &c., V. A., 68 and 70.

Déjèrine et Letulle, La maladie de Friedreich, *Médecine Moderne*, Av., 1890.

Pitt, Newton, Friedreich's disease, *Guy's Hosp. Rep.*, 1887.

Rütimeyer, U. heredit. Ataxie, V. A., 1887, very good.

Smith, E., Hereditary or Degenerative Ataxia, *Bost. Med. and Surg. Jour.*, 1885.

Hydrophobia and Certain Infective Processes.

Popoff, U. d. veränd der Nervenelemente des Centralnervensysts. bei der Hundswuth, V. A., 122, lit.

Popow, Veränd der Zellenkerne der Gehirnnerven am Boden des IV ventrikels, in einem Falle von Hundswuth, *Neurolog. Cent.*, 1890. Refers to **Benedikt,** V. A., 1875 and 1878; **Kolesnikow,** V. A., 85; **Wassilliew,** *Cent. f. d. med. Wiss.*, 1876; **Weller,** *Arch. f. Psych.*, 1879; **Pokotilow,** *Jahrb. des Chiurg. Vereins zu Moskaw*, 1875; **Schaffer,** *Archiv. f. Psych.*, 1888.

Schaffer, Path. u. path. Anat. du Lyssa, Zieg. *Beit.*, B. vii.; *Annales de l'institut Pasteur*, 1889.

Centanni, Ein Fall v. Landry'scher Paralyse, Ziegler's *Beit.*, B. 8, 1890.

Cramer, Path. Anat. der Landry'schen Paralyse, *Centrl. f. path. Anat.*, B. iii., 1891. Summary up to date.

Scheube, Weitere Beit. z. path. Anat. der Beri-beri (Kak-ke) V. A., 95.

Bierfreund, Beitrag. zur hered. Syphilis der Centralnervensystems, Zieg. *Beit.*, B. iii.

Gaupp, Casuist. Beit. z. path. Anat. des Rückenmarks u. seiner Häute, I. D., Tüb., 1889, ref. **Ziegler** in *Beit.*, B. ii.

Langhans, Myelitis der grauen com., Clarke'scher säule u. der Hinterh.; Lepra mutilans, &c., V. A., 64.

Möller, Zur Kennt. der Rückenmarksyphilis, *Arch. f. Dermat. u. Syph.*, 1891.

Adenot, Des méningites microbiennes, Paris, 1890.

Bonome, Z. Aet. der Meningitis cerebrosp. epid., Ziegler's *Beit.*, B. viii., 1890. Gives the various microbes which have been found.

Chorea and Paralysis Agitans.

Handford, Chorea, *Brain*, 1889.
Dana, Chorea, *Brain*, 1890. Table of cases, arterial sclerosis, parench. degen., hyaline bodies, &c.
Koller, Anatomie der Paralysis Agitans, V. A., 125.
Kroemer, Path. Anat. der Chorea, *Arch. f. Psych.*, 1891.

Neurites (*See also* Toxic Degenerations).

Adamkiewicz, U. d. Verhalten der Nervenkörperchen in kranken Nerven, *Arch. f. Psych.*, 1890.
Babinski, Anat. path. des nevrites péripheriques, *Gaz. heb. de Med. et de Ch.*, 1890.
Peripheral Neuritis, a Digest, *Brain*, 1889.
Bramwell, Peripheral Neuritis, Varieties, *Int. Jour. Med. Sc.*, 1888.
Achard et Joffroy, Névrite periph. d'origine vasculaire, *Arch. de méd. exp.*, 1887.
Déjèrine, Madame, *Thèse de Paris*, 1889. Literature of Neuritis, and cases, &c.
Gombault, Nevrite segment. periaxile, *Arch. de Neurolog.*, 1880-1; also **Pitres et Vaillard,** *Rev. de Méd.*, 1885-1888; **Pitres,** *Arch. de Neurolog.*, 1886.
Leloir, Cutaneous neurites, *Thèse de Paris*, 1882.
Diphtheritic Paralysis. See **Leyden,** V.A., 85; **Meyer,** V. A., 85 (all lit. very good).
Handford, Peripheral Neuritis in Enteric Fever, *Brain*, 1888.
Rosenheim, Z. Kennt. d. acuten infect. multip. Neuritis, *Arch. f. Psych.*, B. 18.
Auché, Des alterations des nerfs périphériques chez les diabétiques, *Arch. de méd. exp.*, 1890.
Wigglesworth, Peripheral Neuritis in Raynaud's Disease, P. S., 38.
Brazzola, Anat. path. Veränd. periph. Nervenend. bei Tabes dorsalis, *Cent. f. path. Anat.*, 1892; also 1891.
Pitres et Vaillard, Contr. à l'étude des Névrites périphériques chez les Tabetiques, *Rev. de Méd.*, 1886; do., Chez les tuberculeux, 1887.
Déjèrine, Contrib. à l'étude de la névrite alcoholique, *Arch. de Phys.*, 1887.
Eichorst, Alcoholneuritis, V. A., 112.
Sharkey, Alcoholic Neuritis, P. S., 1888.
Auerbach, U. d. Verhältniss des Diabetes mell. zu Affect. des Nervensystems, *Deut. Arch. f. klin. Med.*, 1887.
Senator, Acute u. subacute multiple Neuritis u. Myositis, *Zeit. f. klin. Med.*, 1889.
Eichhorst, Bleilähmung, V. A., 120. See also **Friedländer,** V. A., 75; **Erb,** *Arch. f. Psych.*, 1875; **Meyer,** *Gaz. méd. de Paris*, 1877.
Letulle, Rech. exp., &c., sur les paralysies mercurielles, *Arch. de Phys.*, 1887.
Moritz, S., Contributions to Anatomy of Lead Paralysis, *Jour. of Anat. and Phys.*, 1881.
Westphal, Bleilähmung, *Arch. f. Psych.*, 1874. See also **Robinson,** *Brain*, 1885; **Schultze,** *Arch. f. Psych.*, 1886; **Vierordt,** *Arch. f. Psych.*, 1887.

Tumours of Peripheral Nerves.

Chavasse, Multiple Neuromata, *Med. Ch.*, 1886.
Coupland and Pasteur, Diffuse Sarcoma of the Pia Mater, P. S., 1887. Very interesting.

Herczel, Fibrome u. Sarkome der peripheren Nerven, Zieg. *Beit.*. B. viii.; **Kriege,** V. A., 108.
Mott, Myxofibroma of a Nerve, P. S., 1887.
Payne, Multiple Neurofibromata and Fibroma Molluscum, P. S., 1887.
Smith, Pathological Diagnosis and Treatment of Neuroma, Dublin, 1849.

Tumours of Brain and Spinal Cord.

Tables of Intra-cranial Tumours, P. S., 1886.
Bernhard, Hirngeschwulste, Berlin, 1881.
Klebs, Die Geschwulste der nervösen Centralapparates, *Prag. Vierteljahreschrift,* B. 133, 1877. A very complete article.
Baumann, Beit. z. Kennt. der Gliome u. Neurogliome, I. D., Tüb., 1887, ref. Ziegler in *Beit.*, B. ii.
Buchholz, Beitrag. z. Kennt. der Hirngliome, *Arch. f. Psych.*, B. xxii.
Hochhaus, Zur Kenntniss des Rückenmarksglioms, *Deut. Archiv. f. klin. Med.*, 1891.
Volkmann, R., Beitrag. z. Lehre v. Gliom u. der sec. Degeneration, *Deut. Archiv. f. klin. Med.*, 1888.
Kronthal, Lipoma in Cord, *Neurolog. Cent.*, 1890.
Taubner, Z. Casuistik u. Entwick. der Hirnlipome, V. A., 110.
Eisenlohr, Leucæmia mit multip. Gehirnnervenlähmungen, V. A., 73. Very interesting case.
Falkson, Chondrocystosarcom im dritten Ventrikel, V. A., 75.
Glaser, Ein Fall v. cent. Angiosarcom des Rüchenmarks, *Arch. f. Psych.*, xvi., 1887.
Strassmann und Strecker, Teratom in rechten Seitenventrikel, V. A., 108.
Weigert, Teratom der Zirbeldrüse, V. A., 65.
Coats, Tumours of Pineal Gland, P. S., 1887.
Tumours of Pituitary, P. S., 35 and 36; V. A., 12, 24, 75, 90.
Breitner, Casuistik der Hypophysentumoren, V. A., 93.
Heusser, Beit. z. Casuistik der Hypophysistumoren, V. A., 110.
Otto, Hyperplasia der Hirnrinde, &c., V. A., 110; Heterotopia, **Semon,** V. A., 58; **Wiche,** *Deut. Klinik,* 1869; **Meschede,** V. A., 50 and 56; **Pfieger,** *Cent. f. med.*, Wiss., 1880; **Pick,** *Arch. f. Psych.*, B. viii., &c.

Spina Bifida.

Humphrey, Cases of Spina Bifida with Bony Projections from the Bodies of the Vertebræ, &c., *Jour. of Anat.*, vol. xx.
Report of Spina Befida Committee, Clin. Soc., Lond., 1885, very good.
Recklinghausen, Spina bifida, sacrolumbaler hypertrichose, Klumpfuss u. neurotischem Geschwür in Folge eines myo-fibromlipom am Rückenmark. Ueber die Art u. d. Enstehung der Sp. bifid., V. A., 105, very detailed.

Syringomyelia and Glioma.

Bäumler, Mlle., U. Hölenbildung im Rückenmark, *Archiv. f. klin. Med.*, B. 40, 1887.
Blocq, Syringomyelia, *Brain,* 1890.
Bruhl, Contrib. à l'étude de la syringomyélie, Paris, 1890. Very good, 160 refs.

Chiari, Die Pathogenese der sog. Syringom., *Zeit. f. Heilk.*, 1888.
Ira van Giesen, A Report of a Case of Syringomyelia, *Jour. of Nerv. and Men. Dis.*, 1889.
Joffroy et Achard, Myélite cavitaire, *Arch. de Phys.*, 1887; Syringomyélie non gliomateuse avec Basedow, *Arch. méd. exp.*, &c., 1891.
Holschewnikoff, Ein Fall von Syringomyelia mit eigenthümlicher Degeneration der peripherischen Nerven verbunden mit trophischer Störungen (Acromegalie), V. A., 119.
Kronthal, Path. der Hölenbild. im Ruckenmark, *Neurolog. Cent.*, 1889.
Langhans, Syringomyelie, V. A., 85.
Leyden, Hydromyelus u. Syringomyelie, V. A., 68; and **Waldeyer,** Entk. des. Centralkanals.
Miura, K., Ueber Gliom des Ruckenmarks u. Syringomyelia, Zieg. *Beit.*, B. xi. 91, lit. of important cases up to date.
Miura, M., Genese der Höhle im Rückenmark, V. A., 117.
Reisinger und Marchand, U. d. Gliom des Rückenmarks, V. A., 98.
Schaffer, Ueber Hydromyelie u. Syringomyelie, *Arch. f. Psych.*, 1891.
Schultze, Spalt- Holen- und Gliombildung im Rückenmark u. Med. obl., V. A., 87, and V. A., 102.
Syringomyelia, **Turner,** P. S., 1888; **Silcock,** ditto.

Certain Trophic Affections.

Hayem, Troubles trophiques, *Arch. de Phys.*, T. v., 2nd ser.
Bielschowsky, Beitrag. z. Lehre v. d. trophische Veränd. der Nagel bei multiplen Neuritis, *Neurolog. Cent.*, 1890.
Israel, O., Schussverletzung d. grossen Armen nerven mit nachfolgender Atrophie der Extremitaten, V. A., 85.
Charcot, Luxations pathologiques et fractures spontanées multiples chez une femme atteinte d'ataxie locomotrice, *Archiv. de Phys.*, T. I., 2nd ser., 1874.
Féré, Lesions osseuses des Ataxiques, *Archiv. de Neurolog.*, 1882.
Kahlden, Artropathy in Tabes, V. A., 109.
Savory and Butlin, Perforating Ulcers, *Med. Chi.*, v. 62, lit.
Pitres et Vaillard, Alt. des nerfs périph. dans deux cas de maux perf. plantaire, &c., *Arch. de Phys.*, 1885.
Bland Sutton, Perforating Ulcer and Changes in the Cord, P. S., vol. 37.
Dinkler, Zur Lehre von der Sklerodermie, *Neurolog. Cent.*, 1890 (endarteritis).
Eichoff, Aet. der Sclerodermie, *Arch. f. dermat. u. Syphilis*, 1890.
Mendel, Ein Fall v. Sklerodermie, *Deut. Med. Woch.*, 1890.
Affleck, Raynaud's Disease, *Brit. Med. Jour.*, 1888 (marked neuritis of plantar nerve).
Bernhard, Morvan'sche Krankheit, *Deut. med. Woch.*, 1891.
Charcot, La maladie de Morvan, *Prog. Méd.*, 1890.
Joffroy et Achard, La maladie de Morvan, syringomy., *Arch. de Méd. exp.* 1891.

ANIMAL PARASITES (Ch. XX., p. 408).

Cobbold, Parasites of Man and Animals, Lond., 1879.
Leuckart, Die Parasiten des Menschen, 2nd edit., Leipsig, 1886; The Parasites of Man, trs. Hoyle, Edin., 1886; Alg. Naturgesch. der Parasiten, 1886.

Friedberger u. Frohner, Lehrbuch der speciellen Path. u. Therap. der Hausthiere, Stuttgart, 1889.

Mégnin, Les parasites et les maladies parasitaires, Paris, 1880, chiefly arachnida.

Neumann, Traité des maladies parasitaires non microbiennes des animaux domestiques, Paris, 1888.

Sparks, Disease of Skin in Dogs produced by Acarus Folliculorum, *Med. Chi.*, 1874.

Hutchinson and Sangster, Lupus Lymphaticus (acari present) P. S., 31.

Baelz, *Cent. f. d. med. Wissen.*, 1880.

Boeck, Fier Fälle von Darier'scher Krankheit, *Arch. f. dermat. u. Syph.*, 1891.

Darier, Acné cornée, psorospermoses cutanées, *C. R. d. Soc. de Biolog.*, 1889.

Borrel, Sur la significat. des figures décrites comme coccidies dans les épitheliomes, *Arch. de méd. exp.*, 1890.

Delépine, Gregarinosis v. psorospermosis (liver), life history and bibliography, P. S., 41, 1890,

Hutchinson, jun., Psorosperms and Skin Diseases, *Jour. of Dermat.*, 1891, and P. S., 1890.

Kartulis, Einiges über d. Pathogenese der Dysentericamöben, *Cent. f. Bak.*, B. ix., 1891.

Malassez, Les nouvelles psorosperms chez l'homme, *Arch. de méd. exp.*, 1890.

Pfeiffer, Unsere heutige Kenntniss von den path. Protozoen, *Cent. f. Bak.*, 1890; Ueber einige neue Formen von Miescher'schen Schlaüchen mit Mikro- Myxo- u. Sarcossporidieninhalt, V. A., 122.

Pütz, Ueber fibroide Pseudohypertrophie vieler skeletmuskeln eines Pferdes bei Anwesenheit Miescher'schen Schlaüche, V. A., 109.

Podysoski, Studien ueber Coccidien, *Cent. f. path. Anat.*, B. i. 1890. In eggs.

Schweiger, Cystad. pap. in Kaninchenbeber (psorosperms), V. A., 113.

Vincent, Sur la presence d'éléments semblables aux psorospermies dans l'épithelioma pavimenteux, *Ann. de micrographie*, T. ii., 1890,

Wickham et Malassez, La maladie de Paget et les nouvelles psorosperms chez l'homme, *Arch. de Méd. exp., &c.*, 1890.

Zürn, Die hugel u. eiformige Psorospermien als Ursache von Krankheiten bei unsern Hausthieren, Liepsig, 1878.

Dolina, Zur path. Anat. des intraoculären Cysticercus, Zieg. *Beit.*, B. v.

Vierordt, Abhandlungen über den multiloculären Echinococcus, Freiburg, 1886.

Waldstein, Multiloc. Echinococcus der Leber, V. A., 83.

Bollinger, Endoph. verrucosa der Pfortader bei Pferde, V. A., 55; Die Kolik der Pferde u. das Wurmaneurysma (Endarteritis verminosa), München, 1870.

Ebstein und Nicolaier, Zooparasitical tuberculosis (kidney), V. A., 118.

Koch, A., Die Nematoden der Schaflunge, Wien, 1883.

Laulanié, Quelques affects. parasitaires du poumon et leur rapport avec la tuberculose, *Arch. de Phys.*, 1889.

Kartulis, U. einen Fall von Auswanderung einer grossen Zahl von Ascariden (in bile ducts), *Cent. f. Bak.* B. i., 1887.

Miura, Pseudotuberculosis of Peritoneum, V. A., 116.

Mueller, Die Nematoden der Saügethierlungen u. die Lungenwurmkrankheit, *Deut. Zeitsch. f. Thiermed.*, 1889, B. 15.

Osler, Verminous Bronchitis in Dogs, Montreal, 1877.

Rabe, Tracheitis verrucosa verminosa, *Deut. Zeit. f. Thiermed.*, 1883.

Willach, Sclerostoma apiostomum. Ein neuer gefähr. Parasit der Affen., *Arch. f. wissen. u. prakt. Thierheilk.*, 1891.

Cohnheim, Path. anat. der Trichinenkrankheit, V. A., 36.

Fiedler, U. d. Kernwucherung in der Muskeln bei der Trichinenkrankheit, V. A., 30.

Lewin, Path. anat. der Trichinose, *Deut. Arch. f. Klin. Med.*, B. 49, 1891.

Lichtheim, Ueber Muskelveränd. bei Trichinose, *Cent. f. path. Anat.*, B. ii., 91. No. 3.

Nonne u. Hœpfner, Klinisch u. anat. Beit. zur Path. der Trichinenerkrankung, *Zeit. f. klin. Med.*, B. xv. 1889. Very little changes.

Virchow, Beit. z. Kennt. der Trichinosis u. der Actinomycosis bei Schweinen, V. A., 95.

Mackenzie, A case of Filarial Hæmato-chyluria, P. S., 1882.

Manson, Lymph Scrotum showing Filaria *in situ*, P. S., 1881.

Kartulis, Vorkommen der Eier des Distomum hæmat. i. den Unterleibsorganen, V. A., 99; also Ueber Riesen-Amöben bei chron. Darmentzündung.

Shaper, Die Leberegelkrankheit der Haussaügethiere, *Ziet. f. Thiermed.*, B. 16, 1890. *Distomatosis.*

Virchow, Dist. hæmat. and polypi in bladder, *Deut. Med. Woch.*, 1891.

Zancarol, Bilharzia in Intestine producing Vegetations, P. S., 1882.

Zwaardemaker, Cirrhosis parasitaria, V.A., 120.

INDEX OF AUTHORS.

Achard, 398
Ackermann, 292
Adami, 412
Adenot, 390
Afanassiew, 260, 261, 292, 324
Afanassijew, 260
Albertini, 268
Altmann, 309
Arnold, 86, 151, 324, 345
Audigé, 292
Auerbach, 366
Aufrecht, 292

Babinski, 383, 388, 396
Ballance, 418, 425
Bardenheuer, 425
Barker, 197, 306
Baelz, 336, 395, 417
Balfour, 371
Barth, 367
Baumgarten, 392, 425, 426
Bäumler, 397
Beadles, 364
Beaumetz, 292
Beck, 104, 264, 266
Begbie, 324
Beloussow, 290
Benecke, 368
Bernard, Cl., 300
Bevan, Lewis, 382
Billroth, 363
Binet, 393
Birch-Hirschfeld, 291
Bird, Golding, 235
Bistrow, 282
Bizzozero, 235
Blauvelt, 290
Blocq, 292, 388, 403
Blumenthal, 377
Bochdalek, 193
Boeck, 417
Bollinger, 235, 298, 413
Bonome, 390
Boström, 114, 115
Bowditch, 299
Bramwell, 221, 224, 367
Brieger, 290, 295
Browicz, 260
Bruhl, 391
Buckwald, 262
Bullen, 376
Büngner, 372, 405
Burdon Sanderson, 324, 333
Buzzard, 396

Cavafy, 235
Ceci, 377
Centanni, 394
Chantemesse, 119, 124
Charcot, 222, 261, 264, 383, 391, 367, 403, 406
Chaslin, 387
Cheyne, Watson, 333
Christison, 324
Coats, 86
Cobbold, 113, 408, 414
Coën, 425
Cohn, 340
Cohnheim, 49, 78, 114, 138, 236, 279, 290, 351, 370
Cornil, 260, 404
Crocker, 165, 254

Dähnhardt, 367
Dareste, 206
Darier, 165, 253
Dean, 377
Defaucamberge, 240
Déjèrine, 385, 386, 396
Délapine, 4
Dittel, 343
Doran, 345
Dreschfeld, 379
Dujardin, 292
Dunin, 259

Eberth, 119, 210, 282, 330, 412
Ebstein, 268, 412
Ecker, 203
Eddowes, 255
Ehrlich, 10, 13, 208
Eisenlohr, 405
Englisch, 342
Eppinger, 116, 224
Erb, 366
Erichsen, 67
Erlitzky, 376
Esoff, 254
Eulenberg, 367
Eve, 344
Ewald, 93, 273

Fagge, 235
Fenwick, 313
Fenwick, F., 307
Fichtner, 268
Fischer, 425
Flechsig, 384
Fleiner, 324
Foa, 290
Fox, 302, 324, 333
Fränkel, 322
Fränkel, E., 305
Friedländer, 392
Friedmann, 379
Friedreich, 298, 324, 385
Frommann, 283

Germont, 264
Gerrard, 2, 9
Gervais, Paul, 248
Gilbert, 373
Giraldès, 142
Godlee, 280
Gombault, 261, 290, 314, 393
Goodhart, 113, 288, 294, 295
Gowers, 229, 231, 367, 379, 401, 403
Grawitz, 124, 263, 424
Gray, 404
Greenfield, 271, 336
Greenhow, 324
Gruber, 298
Gull, 219

Habershon, 313
Hadden, 113
Hamilton, 282
Harnack, 393
Hanau, 418
Hanot, 283, 314
Harley, 249
Hauser, 176, 303, 318, 319
Hayem, 208, 209, 231, 234, 236, 373
Hesse, 138
Heymann, 322
His, 371
Hoffmann, 382
Holm, 324
Hoppe-Seyler, 93
Horsley, 239, 240
Hünermann, 322
Hunter, 236

Ilg, 248
Ins, 324
Israel, 263, 406

Jaksch, 208
Johnson, 221
Johnson, Raymond, 363
Joffroy, 391, 398
Jüngst, 360

Kadyi, 200
Kahlden, 239, 260, 292, 348
Kahler, 377
Kanthack, 322
Kartulis, 413, 416
Kaufmann, 309
Kelsch, 229, 315
Kiener, 315
Klebs, 32, 87, 129, 307, 404, 418
Klein, 214, 296, 324, 333
Klob, 300
Knauff, 324
Kobierske, 260
Koch, A., 412
Koch, 41
Kocher, 364
Kolessnikow, 352
Korn, 324
Köster, 220
Krauss, 366
Krönig, 260, 292
Kronthal, 402
Krunkenberg, 93

Lancereaux, 402
Langhans, 88, 169, 406
Landseer, Sir E., 206
Lannelongue, 203
Laulanié, 111, 112, 412
Leber, 124
Lee, 3
Legg, Wickham, 290
Leissering, 418
Lesser, 261, 308
Letulle, 386
Leuckart, 408
Leva, 238
Leyden, 263, 273, 290, 384
Lewin, 324
Lewis, 414
Lingard, 120, 121
Litten, 227, 262, 288, 290
Löffler, 32, 103
Lomer, 289
Lorain, 336
Lustgarten, 120

Mackenzie, Stephen, 415
Maier, R., 315
Malassez, 119, 417
Manhot, 224
Manson, Patrick, 413
Marchand, 399
Marie, 240
Martin, 323
Megnin, 409
Mehring, 300
Mendel, 376, 382
Merkel, 324
Meschede, 376, 396
Metschnikoff, 425
Meyer, 290, 394
Meynert, 382
Minkowski, 300
Miura, K., 404
Miura, M., 112, 397
Mohnike, 376
Mondino, 288
Mott, 221, 382
Moxon, 297
Mueller, 412
Muir, 227

Nasse, 282
Neelsen, 14, 343
Neisser 417
Neuberger, 260
Neumann, 232, 360, 365
Nicati, 291
Nicolaier, 412
Niehus, 343
Nikiforoff, 425
Nothnagel, 324

Obersteiner, 376
Obolensky, 229, 292
Ogle, 328
Orth, 227
Osler, 288, 412
Otto, 396

Paget, 184, 244, 342, 364
Pal, 15, 19
Patenko, 346
Pernice, 351
Pfeffer, 426
Pfleger, 396
Piana, 200
Pisenti, 268
Pitres, 394
Platen, 263
Podwyssozki, 425
Poirier, 189
Pollard, 249
Popoff, 282, 380
Popow, 393
Posner, 322, 343
Powell, Douglas, 228
Pringle, 253
Provost, 393
Pütz, 365, 418
Pye-Smith, 302

Quincke, 282, 303

Rabe, 413
Ranvier, 73, 372, 404
Rattone, 288
Rauber, 206
Raynaud, 289
Recklinghausen, 224, 307, 343, 324, 401
Redlich, 377
Reichenbach, 302
Rein, 352
Renvers, 302
Rheiner, 322

Ribbert, 278, 426
Richard, 364
Richaud, 291
Riesinger, 399
Rindfleisch, 236
Ringer, 245
Ritschl, 319
Robert, 373
Robin, 336
Rokitansky, 342
Rosenbach, 378
Roth, 344
Rupperts, 324
Rütimeyer, 385

Sabourin, 286, 295
Sack, 220
Salvioti, 290
Schachmann, 283
Schaffer, 380
Scheube, 395
Schmaus, 478
Schmidt, 363
Schmorl, 296, 339
Schönlein, 240
Schuchardt, 253, 364
Schulthess, 363
Schultze, 367
Schütz, 282
Semon, 340
Shaper, 415
Shattock, 418
Sherrington, 425
Siedamgrotsky, 418
Silcock, 113, 344
Simon, 398
Slavjanski, 324
Smirnow, 307
Solowieff, 288
Souza-Leite, 240
Sparks, 252, 409
Spencer, 249
Steinhaus, 419
Steudner, 406
Stilling, 239, 243, 343
Störk, 322
Straus, 264, 292, 302
Streckeisen, 200
Stroebe, 419
Ssudakewitsch, 65
Sutton, 160, 217, 219

Tait, Lawson, 203
Talma, 263
Taylor, 348
Thiede, 352
Thoma, 211, 219, 220, 224
Thompson, 324, 342, 343
Tigges, 382
Tizzoni, 239
Traube, 324
Treves, 312, 317
Tschisch, 376
Turner, 402

Unna, 251, 255

Vaillard, 229
Vignal, 119
Vincenzi, 280
Virchow, 49, 82, 139, 248, 280, 397
Volkmann, Rudolf, 160
Vulpian, 366, 383

Wagner, 266, 298
Waldstein, 411
Weichselbaum, 390
Weigert, 14, 19, 315, 335
Werra, 263
Wertheim, 254
West, S., 288
Westphal, 394
Wickham, 165, 417
Wilks, 243, 297
Willach, 413
Williams, John, 167, 348, 349
Williams, Roger, 202
Wilson, Erasmus, 195
Witla, 302
Wolfenden, 323
Woodhead, 377
Wooldridge, 288
Wyss, 290

Zancarol, 317
Zanda, 402
Ziehl, 14
Zeller, 348
Zenker, 81, 300, 324, 368
Ziegler, 342, 344, 345,
Zuckerkandl, 200
Zwaardemaker, 291, 415

INDEX OF SUBJECTS.

Abscess, formation of, 35
chronic, structure of, 57, 58
tubercular, 58
Absorption of dead tissue. *See* also giant cells.
of ligatures, 65
of muscle fibre, 67
Acarus, 252
folliculorum, 172
scabiei, 409 (fig. 122)
Achorion schönleinii, 124
Acne rosacea, 172, 409, 410
Acne vulgaris, 252
Acromegaly, 200, 240
minute structure of hypophysis in, 437
Actinomyces, staining, 14, 115
Actinomycosis, 113, 116, 313, 335 (fig. 39)
pus in, 114
pleomorphism, 115
lardaceous degeneration in, 82
Acute yellow atrophy, liver in, 77, 293
Addison's disease, 91, 238
Adenitis, 226
Adeno-fibromata, 134
Adenoid tissues, 225
Adenoma, 172, 352
stroma of, 174
of breast, varieties of, 173 (fig. 69)
of the cervix, 348
of kidney,
malignant, of liver, 298
of lung, 158
of prepuce, 343
sebaceum, 253
Adenoma destruens of uterus, 350 (fig. 74)
Adenomata malignant, 167, 318
Adenomata of alimentary canal, 317
Adeno-myxoma of testis, 344
Adeno-sarcoma, 136, 148, 357
Ague cake, 109
Alimentary canal, adenomata of, 317
absorption of silver in, 87
chronic inflammation and pre-cancerous changes, 172
cystic tumours of, 317
diverticula of, 316
effects of toxic agents on, 314
hyperplasia, adenoma and cancer of, 176
hypertrophy of coats of, 316
inflammation and necrosis of, 305
inflammation of, in sapræmia, 102
leiomyomata in, 130
lympho-sarcoma of, 150, 317
malignant adenoma, 177 (fig. 75, typical columnar epithelioma)
tumours of, 316
Amyloid degeneration, 81
of stroma of muscle, 368
Amylum bodies, 85, 377
Anæmia, pernicious, blood in, 236
marrow in, 236
red corpuscles in, 208
Anæmia, splenic, 235
Anchylostoma, 413
Aneurism, causes of, 221, 222
endarteritis as a cause of, 223
from mesarteritis, 224
Angioma, cavernous, of spleen, 169
colloid, changes in, 169
Angiomata, 130
cystic, colloid in, 200
Angio-sarcoma, 132, 151, 170, 361
Angio-sarcomata of brain, 403
Anguillula stercoralis, 413
Animal parasites, 408
Anthracosis, 87, 327
Anthrax bacilli, 107, 312 (fig. 37)
Arachnida, 408
Arcus senilis, 77
Argyria, 87
Arterial coat, tumours of (endothelioma, fibroma, myoma), 131, 132

Arteries and veins, degenerative changes in, 217
Arterio-capillary fibrosis, 217
Arthritis deformans, 245
Ascaris lumbricoides, 413
Ascites, chylous, 302, 303
Aspergilli, 124
in lung, 335
Aspergillus fumigatus, 119
Atelectasis and collapse, 329, 336
Atheroma, 95, 218 (figs. 87 and 88)
Atrophic changes in neuroses, 405, 406
proliferation of muscle fibre, 79, 392
Atrophy and dilatation of stomach, 315
from disease, 366
of bowel, 315

Bacilli, staining, 17
Bacillus of diphtheria, 32
lepræ, 119
mallei, 106
syphilis, 120
tubercle, 116
typhoid, 116
Bacteria, tissue reaction against, 118, 425
Beri-beri, 394
Basedow's or Grave's disease, 240
Bile duct, congenital myxomyoma of, 297
ligature of, 290
new formation of, 286
obstruction of, 289
congenital, syphilitic obstruction of, 289
Bile pigmentation, 90
Bilharzia, ova of, 317, 416 (fig. 129)
disease, 416
Bilirubin infarct in kidney, 90
Black spit, 86, 326
Black tongue, 91
Bladder, epithelioma of, 280
papilloma of, 137, 148, 280 (fig. 61)

Blister, 250
Blood, the coverslip method of preparing, 208
clot, changes in, 88
in leukæmia, 231
leucocytes in, 234
Blood (*continued*)
in lymphadenoma, 231
in malaria, 90
in pernicious anæmia, 236
pigments, 87
Bone, atrophy of, from nerve lesions, 246
cutting sections of, 4
cystic fibromata in, 135
diseases of, 241
necrosis, syphilis and tubercle in, 246
union of fractured, 69, 70
Bothriocephalus latus, 410
Brain and cord, tumours of, 401
ciliated cyst of, 190
endothelioma of, 168
epithelial rests in, 166
in malaria, 90
Branchial chondromata, 203
sinuses, cause of cysts, 181
Breast, adenoma and carcinoma of, 173
atypical carcinoma of, 174 (fig. 71)
carcinoma of, 174 (fig. 70)
cysts of, 187
duct cancer of, 174
fibro-adenoma of, 135, 136 (fig. 52)
fibro-myxoma of, 136
myxo-adenoma of, 136
tumours of, 352
Breasts, accessory, 201
Bright's disease, nephritis of, 270
Bronchi, tumours of, 323
Bronchial glands, 86
Bronchiectasis, 329
congenital, 337
Bronchitis, acute, 29, 30
Bronchocele, pulsating, 240
Broncho-pneumonia, 25, 30, 31 (fig. 5)
acute miliary, 328 (fig. 10)
chronic, 328, 329 (fig. 5)
Brown atrophy of heart, 91
induration of lung, 43, 88
Burns, influence on kidney, 261
Bursal cysts, 188

Cachectic conditions, lardaceous degenerations in, 82. *See* also fatty and fibroid degeneration and atrophic proliferation
Cachexia strumipriva, 239
Calcareous deposits, reactions of, 96

Calcification, 94
Calcium salts deposited in kidney, 260
Callus, 70, 71 (fig. 27)
" Callus hypertrophied," 143
Cancer, 55, 160
acinous, of breast, 174 (fig. 71)
atypical, 318 (fig. 66)
metastasis in, 319
cells, bodies in, 419
colloid, 80, 319
of omentum, 304
duct, of breast, 174 (fig. 71)
encephaloid, 175 (fig. 73)
glandular, in lung, 339
of cervix, 161 (figs. 62, 63)
of neck of gall-bladder, 297
of ovary, 346
of pancreas, 299
of pleura, 341
of prostate, 342
of stomach, 313
of testis, 344
of tongue, 113
of uterus, 349
scirrhus, 175 (fig. 72)
sporozoon of, 418
typical glandular, of rectum, 318 (fig. 75)
Cancers, Hauser's classification of, 318
Cantharidin on kidney, 259
Capillaries in repair, 45, 66, 67
Carcinoma, branchiogenous, 164. *See* Cancer
Caries, calcification in, 95
tubercular, 247
Cartilage, gouty, 92
hyperplasias of, 141
in dura mater, 402
rests in kidney, 278
in testis, 184, 344
Caseation and caseous material, 41, 52
Casts, renal, 33, 77, 84
Catarrhal inflammation, 53, 251, 320
Cavernous angioma of spleen, 169
lymphomata, 169
tumours from endothelioma, 169
Cellulitis, 34 (fig. 14)
Cerebro-spinal meningitis, parasite in, 116, 389
Cervix, chondro-sarcoma of, 352
Cestodes, 410
Chancre, hard, 120
soft, 100
Charcot's crystals, 236
in bone, 96
in marrow, 96
in spleen, 96
Cholera, 102, 104, 311
Cholesteatomata, 165, 404
Cholesterin, 78, 93, 94
Chondroblasts, 70
Chondroma, chordal, 139
of larynx, 323
Chondromata, 320, 138
mode of origin, 139
rachitic, 243
Chondro-sarcoma of cervix, 352
Choroid, cysts of, 191
Chronic infective processes, 110
Chylangiomata, 133, 191
Chyluria from filaria, 414
Cirrhoses of liver, zooparasitical, 291
Cirrhosis, a cause of cysts in liver, 187
biliary origin of, hypertrophic (liver), 290
fatty hypertrophic, of liver, 289
of liver, alcoholic, 292
from coccidia, 416
from parasites, 411
periportal, 292
syphilitic, of liver, 122 (fig. 45)
Cladothrix, 115
Clasmatocyte of Ranvier, 73
Classification of tumours, 126, 352
Clot, organisation of, 46, 67
Cloudy swelling, 74
Coagulation necrosis, 81, 97, 315
Coccidia, 113, 416, 417
Coccygeal cysts, 181
Coccyx, dermoid in region of, 206, 207
tumours of, 203
Colitis Polyposa, 54, 137
Colloid, cancer of peritoneum, 302, 303
degeneration, 80, 178, 200
excretion of pituitary body, 180
tumours, 361
Condyloma, 155
Condylomata of nasal cavity, 320
of skin, 137
syphilitic, 121
Congenital diverticula and sinuses, 202
epithelial rests, 159

Congenital (*continued*)
elephantiasis, 133
formations, 198
tag-like and polypoid processes, 203
tumours, 132, 204, 356
Conjunctivitis, 56
Connective tissue in repair, 66
atrophy, 255
Corn, 154
Corneal ulcers, 56
Cornification, 354
Corpora amylacea, origin of, 82, 85, 377
Cowper's glands, 343
Cretinism, 239
Cretins, lipomata in, 143
Croupous inflammation, 31
Cylindromata, 80, 151, 164, 178, 319, 361, 402
Cyst wall, muscle in, 192
of tongue from lingual sinus, 181
Cystic adenoma, 174
adenomata of kidney, 186
degeneration, general, 188
degeneration of kidney, 185 (fig. 78)
disease of bones, 179
diverticula of peritoneum, 189
fibroid, 129
hygromata, 188, 191
origin of, 192
intra, growths, 174
kidney, congenital, 186
its causes, 186
sarcoma of testis and ovary, 184
Cysticercus, 65, 113
Cystin, 93
Cystitis acute, 56
Cystoglioma, 398
Cystolipomata, 133
Cystomata, congenital lymphatic, 191
Cysto-sarcoma, 192
Cysts, atheromatous, 194 (fig. 81)
bursal, 188
ciliated, 193
dermoid, from branchial sinuses, 181
dermoid, from Graafian follicle, 182
epithelial, in pineal body, 180
femoral, 189
from epithelial inclusions, 180
from rests, duct, 180
Cysts from rests (*continued*)
gland, 180
sinus, 180
in fibrous and cartilaginous tumours, 179
in tumours, 179
involution, 187
lymphatic, 191
near umbilicus, 181
of alimentary canal, 317
of brain and spinal cord and membranes, 189, 190
of breast, 187
of choroid, 191
of coccyx, 181
of corpora lutea, 182
of glands, 193
of hair follicles, 194
of liver, 187, 286
of lung, 338
of mucous membranes, 192
of omentum, 304
of ovary and testis, 182
of pancreas, 187, 299
of pituitary body, 180
of prostate, 342
of salivary glands, 188
of skin and epithelial appendages, 194
of sweat glands, 194
of teeth sacs, 195
of testis, 183, 184, 344
of thyroid, 188
of vagina, 183, 352
of urinary system, 84, 185
oil cysts, 196
retention, 185
sebaceous, 172, 194
serous, 189
spermatic, 184, 344
synovial, 189
varieties of, 179. *See* also Dermoids
vascular, 190

Degeneration, amyloid and lardaceous, 2, 11, 81, 111
colloid, 80
fatty, 76, 111
fatty, of renal epithelium, 84
glassy, 81
hyaline, 80
œdematous, 75
Zenker's, 81

Demodex folliculorum, 252, 253, 409. *See* also Acarus
Dermatomyomata, 130, 369
Dermoid changes in larynx, 322
cyst, 202
in abdomen, 205
of ovary, 182, 204
plates, 204
pigmented, of tongue, 91
Dermoids, simple, 168, 194, 195
branchial, 196
classification of, 204
cranial, 203
facial, 196, 203
scalp, 196
from rudimentary embryos, 206
of floor of mouth, 197
of omentum and peritoneum, 304
structure of, 205
thoracic, 205
Diabetes, 79
kidney in, 268
liver in, 296
pigmented liver in, 283
pancreas in, 299
Diphtheria, Loeffler's bacillus in, 103
Diphtheritic inflammation, 320
membranes, 97
pharyngitis, 31
Diphtheritis verminosa, 413
Distoma and distomatosis, 415
Bilharzia, 292
Distomata, causing cirrhosis of liver, 291
Diverticula of alimentary canal, 316
Dupuytren's contracture, 255
Dura mater, tumours of, 402
Dust inhalation, 86, 225, 324
Dysentery, croupous and diphtheritic, 30, 311

Echinococcus multilocularis, 411
Ecchondroses, 140
Eczema, 251
Egyptian chlorosis, 413
Eichhorst's corpuscles, 236
Eleidin granules, staining of, 255
Elephantiasis arabum, 134
congenital, 133
neuromatosa, 134, 136
filarial, 414
Embolism, 212
fat, 212 (fig. 83)
of lung, 212, 338 (fig. 83)
Embolism *(continued)*
infective, 104
malignant, in lung, 339
Embryonic "faults and irregularities," 370
Emphysema, 53, 329, 337, 338 (figs. 19, 22, 111, 112)
Empyæma, 333
Enamel germ tumours, 318
organ tumours, 164
Encapsulation, meaning of, 356
Encephalitis, 378
Enchondroma, traumatic, 141
Enchondromata branchial (embryonal), 140
ossifying, 141
Endarteritis, 217 (fig. 87)
compensatory, 220
in chronic pneumonia, 329
in kidney, 273 (fig. 46)
pulmonary, 220
syphilitic, 121, 123, 221 (fig. 46)
verminosa, 298
views as to causes, 219
Endocarditis, chronic, heart muscle in, 215
ulcerative, micro-organisms in, 216
valvular, 216 (fig. 86)
Endometritis, 175, 347
Endothelioma causing cavernous tumours, 169
extravascular, 170
from parasitic irritation, 168
intravascular, of veins, 168
giant cells in, 169
miliary, of pia mater, 168
of brain,
of dura mater, 168, 402, 403
of penis, 344
of periosteum of skull, 168
Endotheliomata, 131
hyaline changes in, 80
lymphatic, 132
resembling miliary tubercle, 167
Enteritis, cases of, 309
chronic, 314
verminosa, 413
Epididymitis, 344
Epilepsy, changes in essential, 387
Epithelial (cancer) inoculation, 340
hyperplasia, 157, 353, 354
nests, 156 (fig. 64)
rests, congenital, 159
tumours, simple, 153

Epithelioma, columnar atypical, 166, 177
typical, 357
cysts in, 194 (fig. 80)
of bladder, 280
of bronchi, 324
of glans penis, 344
of nipple, 364
of trachea, 323
scirrhoid squamous, 352 (fig. 63)
squamous, 162, 164, 318 (fig. 64)
in lung, 340
Epitheliomata, 162
coccidia in, 165
melanotic, 164
of alimentary canal, 317, 318
Epithelium, action of arsenic on, 157
changes in chronic inflammation of serous, 158
in margins of ulcers, 157
in repair, 66
irritation of, 154
Erysipelas (cutaneous, phlegmonous), 100, 101, 250
Erythemata, 250
Erythrophages, 88
Exostoses, periosteal, origin of, 141
Exostosis, eburnated, 141
ivory, 250
Eye, black choroidal polypi, 137
bone in, 142

Fallopian tubes, inflammation of, 347
Farcy, 106
Fat, 11, 67
crystals, 96
embolism, 43
Fatty changes in liver, 77, 78, 281 (fig. 29)
degeneration and infiltration, 76-78
in diphtheria, 102
of heart, 76, 79, 236 (fig. 28)
of kidney, 77, 259
Favus, 124, 252
Fevers, parenchymatous changes in, 81, 102, 214, 226, 269, 281
Fibroadenosarcoma of breast, 136, 174
Fibroadenomata, 135, 137, 138, 357
of breast, 135, 173 (figs. 52, 69)
of liver, 298
Fibroblasts, 42, 61, 67, 70
Fibroid, cystic, 129
lung, 87. *See* also Lung, Liver, Kidney, &c.
of uterus, 129 (figs. 48, 49)
recurrent of Paget, 152
Fibroma, 129 (fig. 50)
of skin, 133 (fig. 50)
of tongue, 317
Fibromata benign, 355
cystic, 135
fibroma-like hyperplasia, 133 (fig. 50)
of cord, 403
periacinous, 358
Fibromyxoma of breast, 136
Fibroneuromata, 128, 229
Fibropapillomata of larynx, 323
relation to chronic inflammation, 137
Fibrosarcomata, 146
Fibrous epulis, 134
Filaria immitis, a cause of miliary granulomata, 413
medinensis, 414
sanguinis hominis (Bancroftii), 414
Fistulæ, cervical, 202
Fractures, hyperplasias in, 72
Fränkel's bacillus or micrococcus, 103
Friedländer's pneumococcus, 103
Friedreich's disease, 385
Fungi, higher pathogenic, 124

Galactocele, 187
Gall bladder, diseases of, 297
precancerous change in, 171
Ganglionic neuromata, 128
Gangrene spreading, 36, 41, 102 (fig. 15)
Gastritis, 306, 307
chronic, 192, 313
eczematous, 307
emphysematous, 307
in burns, 307
in hydrophobia, 307
mycotic, 307
Giant cells, 23, 42, 51, 112, 118, 345, 365
as osteoclasts, 241
in atheroma, 219
in cornea, 65
in epithelioma, 163

Giant cells (*continued*)
in hydatid of liver, 411
in intravascular endothelioma, 169
in thrombi, 212
round foreign bodies, 65
tubercle, 50 (fig. 20)
Glabella coccygea, 203
Gland, adeno-fibroid changes in, 135
Gland tissues, 170
tumours, 170
Glanders, 106
Glands in lymphadenoma, 230
pigmented, 226
Glans penis, epithelioma of, 344
Glioma and syringomyelia, 397
of orbit, 405
Gliomata, 128, 150, 404
Glomerular capillaries in lardaceous kidney, 83 (fig. 30)
Glomeruli, absorption of silver in, 87
calcification of, 94
pseudo, 278
Glomerulo-nephritis, 32 (fig. 12)
Glomerulus of kidney, changes in, 274 (figs. 30, 79, 97, 98, 99, 103)
Glossitis, 306, 313
Glottis, acute œdema of, 321
Gluge's corpuscles, 44, 68
Glycogenous formation, 79
Gmelin's test for bile pigment, 90
Goitre, 80, 240
Gouty cartilage, 92
Granulation tissue, 45, 54, 57
union by, 63
Granule cells, 44
Granuloma, 110, 119, 252
fungoides, 355
of lung from inhalation of dust, 335
retrogressive changes in, 112
tubercular, 49, 50 (figs. 19, 20)
Granulomata, calcification of, 95
Graves' disease, 240
Guanin, 93
Guinea worm, 414
Gummata in liver, 121, 122 (fig. 42, 43)
in lung, 336
miliary, 124
of central nervous system, 391

Hæmangiomata, 130
Hæmatoidin, 62, 88, 155
Hæmatomonas, 90, 108, 209
Hæmaturia from filaria, 414
Hæmochyluria, blood in, 414 (fig. 128)
Hæmoglobin in scab, 63
Hæmorrhages in diphtheria, 103
Hair follicle cysts, 253
Healing by first intent, 60
Heart, brown atrophy of, 91
fatty degeneration, 79, 214 (fig. 28)
fibres, degeneration of, 75
infiltrating sarcoma of, 150
muscle, calcification, 215
fatty infiltration, 214
hyaline change in, 214
in chronic endocarditis, 216 (fig. 85)
pigmentary degeneration, 214
rupture of, 222
Hepatic rests, 298
Hepatisation, lung, 26
Herpes, 251
Herxheimer's spirals, staining of, 255
Hodgkin's disease, 229
Horn, epithelial, 155
Horny growths from atheromatous cysts, 195
Hospital gangrene, 101
Howship's lacunæ, 71
Hyaline bodies in nervous system, 377
casts, 84
changes, 80, 81
in fibromata, 134
in meningeal tumour, 402
in muscle, 214, 368
in nervous system, 382
material, gentian voilet reaction of, 361
transformation, 346
in periacinous stroma, 361
of adult tumour stroma, 359
Hydatid, 410 (figs. 125, 126)
cysts, 65, 113
Hydrocephalus, 190
Hydromyelia, 397
Hydronephrosis, 185
Hydrophobia, 380
pigmentation of nerve cells in, 376
Hyoid glands, embryonic, 200
Hyperostosis, 248
Hyperplasia, due to parasites, 418
epithelial, in lung, in syphilis, 336

Hyperplasia (*continued*)
glandular, in distomatosis, 415
in chronic laryngitis, 321
inflammatory of muscle, 365, 369
in glands, 226
in tubercular ulcer of intestine, 312
nerve, 127
of Bowman's capsule, 274 (fig. 78)
of gland tissue of uterus, 348
of liver cells, 296, 298
of oophoron, 345
of spider cells, 379, 382
Hyperplasias, cystic, 193
endothelium of peritoneum, 303
epithelial, 157, 158, 251, 353
fibroma-like, 133, 137, 253, 354 (fig. 50)
in chronic inflammation, 54
in fracture of bone, 72
in lung, 339
of alimentary canal, 306
of cartilage, 141
of fat, 144, 368
of kidney, glandular, 297
precancerous, 154, 171
Hyperplastic changes in chronic pneumonia, 330
Hyperpyrexia, 74
Hypertrophy of coats of alimentary tract, 316
Hypophysis, 401
and the thyroid, 199
dermoid and teratoma in region of, 206, 207
in acromegaly, 200 and Note, 437

Ichthyosis, 253
linguæ, 157, 253
Icterus neonatorum, a cause of, 291
Infarct bilirubin, 90, 291
calcareous, 95
infective, 104, 213
pulmonary, 106
uric acid in kidney, 93
Infarction, pyæmic, 106
Infarcts, 212 (fig. 84)
of kidney, 213
Infective granulomata, 110
processes, acute local, 100
parasites in, 98
Infiltration, fatty, 78
Inflammation, acute, 21
acute, of larynx and trachea, 320
chronic, 47

Inflammation (*continued*)
chronic, causing precancerous changes, 171
croupous, 31
diphtheritic, 31, 321
lymphatic cysts from, 191
of mucous surfaces, 29
of parenchyma, 32
of serous surfaces, 26
productive, 23
relation to cancer, 167
repair in, 38
spreading, 100
Inflammatory lesions due to higher fungi, 124
stages in broncho-pneumonia, 31
Inflamed areolar tissue, 34
Inhalation dust, 86
Intestine, atrophy and fibroid degeneration of, 315
tubercular ulceration of, 312 (fig. 110)
Iron in convoluted tubules, 90
in liver, 89 (fig. 33)
in pernicious anæmia, 236
Irritative properties of coccidia, 418
Irritation and tumour stroma, 178
causing precancerous changes, 171
changes from parasites, 408
influence of, 354
phenomena, 255

Jaw, fibroma of lower, 134

Kak-ke or Beri-beri, 394
Keloid, 55, 136
Keratitis, 56
suppurative, aspergillus in, 124
Keratosis, 157
Kidney, after ligature of branch of renal artery, 263 (fig. 84)
after ligature of renal vein, 262 (fig. 101)
after ligature of ureter, 264
anatomy of, 257
alcoholic, 272, 276
amyloid degeneration, 83, 268, 273 (fig. 30)
anthrax in, 107 (fig. 38)
bilirubin, infarct in, 90, 291
calcification in, 94, 260
carcinoma of, 278
cartilage formations in, 140, 278

KIDNEY *(continued)*
changes in parenchyma of, 83, 275 (figs. 30, 79, 96, 99)
changes in pelvis of, 274, 280
cloudy swelling of, 33, 75
compensatory hypertrophy of, 263
congenital cystic, 186
cystic adenomata of, 186
cystic degeneration of, 185, 264, 274 (fig. 78)
endarteritis in, 273 (fig. 46)
fatty degeneration, 77
glandular hyperplasias of, 279
glycogen in, 79
gouty, 272, 274, 276
granular contracted, 267, 271, 272 (fig. 96)
in cardiac disease, 263
in diabetes, 268
infarct in, in endarteritis, 264
in fever, 269 (fig. 12)
influence of burns on, 261
inflammation of, 32
influence of lead salts on, 261
in leukæmia, 233
in malaria, 90
in phosphorus poisoning, 261 (fig. 102)
in pyæmia, 261 (fig. 36)
interstitial changes, 84
large red, 277
soft white, 271 (fig. 103)
white, 263, 277 (fig. 103)
albuminoid, 277 (fig. 30)
lipomata of, 279
myo-sarcomata of, 279
nævoid tumours of, 279
necrosis, 263
pigmentation, 87
poisons on, 259, 260
precancerous changes in, 171
rests in, 198, 278
sarcomata of, 278
secondary infective foci in, 105 (fig. 36)
small red fibroid, 276
pale granular, 276 (fig. 96)
supra-renal rest in, 213, 258, 279
surgical, 266 (fig. 100)
syphilitic, 269
tubercle of, 277, 278
tumours of, 278
urate of soda in, 92
KUPFFER'S STAR CELLS, 292
LANDRY'S PARALYSIS, 394
LARDACEOUS DEGENERATION, 81
hardening, 2
of alimentary tract, 85
of kidney, 83, 273
of lymphatics, 84
staining, 11
Lardaceous liver, 84 (fig. 31)
spleen, 84 (fig. 32)
LARYNGITIS, acute, chronic, hypertrophic, 320
chronic, epithelial changes in, 322
LARYNX, malignant changes in, 323
minute anatomy of, 322
syphilis of, 321
tubercle of, 321
tumours of, 322
LEAD PALSY, degeneration in, 393
SALTS on kidney, 261
poisoning, intestinal plexuses, sclerosis of, 315
LEIOMYOMATA, 129 (figs. 48, 49)
LEONTIASIS OSSEA, 248
Lepra mutilans, 405
LEPROSY, 119
bacillus staining, 14
lardaceous degeneration in, 82
LEPTO-MENINGITIS, 389
LEUCIN spheres, 96
LEUCOCYTES, 22, 34, 36, 101, 225
as phagocytes, 41
division of, 73
in infective foci, 105 (fig. 36)
in repair, 39
LEUCOCYTOSIS, 226
and lymphatic hyperplasia, 227
in inflammation, 22
LEUCOCYTHÆMIA, red corpuscles in, 209. *See* Leukæmia
LEUCOPLACIA, 157, 313
LEUKÆMIA, blood in, 234
Charcot's crystals in, 96
karyokinesis in, 235
kidney in, 233
liver in, 233 (figs. 89, 90)
lymphatic, medullary, splenic, 228
LICHEN PILARIS, 254
LIME METASTASES, 95
LIPOMA NASI, 172, 194, 409
LIPOMATA, 143
of brain and cord, 401
of kidney, 279
of peritoneum, 304
retro-peritoneal, 304

Lipomatosis luxurians, 367
Lithopædion, 96
Liver, abscess in, 295
acute yellow atrophy of, 293, 295
adenoma of, 298
atrophic cirrhosis of, 284 (fig. 104)
atrophy of, 281
bacterial necrosis of, 282
biliary origin of hypertrophic cirrhosis of, 290
cirrhosis of, 283
cloudy swelling of, 75
cysts of, 187, 286
echinococcus in, 295
fatty degeneration of, 77, 78, 285
fatty hypertrophic cirrhosis of, 289
golden corpuscles in, 287
granular degeneration of, 281, 282
hypertrophic cirrhosis of (Charcot) 283, 285
hypertrophy of, 281
in acute specifics, 296
in argyria, 283
in diabetes, 296
in eclampsia, 296
infarct in, 214
infection of, from alimentary canal, 295
influence of occlusion of portal vein on, 288
in leukæmia, 233 (figs. 89, 90)
in melanæmia, 282
in peritonitis, 295
in pernicious anæmia, 89
in phosphorus poisoning, 292, 293
in rickets, 296
interstitial changes in enteritis, 295
lardaceous, 84 (fig. 31)
ligature of hepatic artery, 287
pigment in, 87, 89, 283
metastatic epithelium in, 177
nævi in, 131, 169
nutmeg, 281, 287
parenchyma, primary tumours of, 297
parenchymatous degeneration of, 281, 293
perivenous fibrosis in, 286
precancerous changes in, 171
red atrophy of, 287, 293
rests in, 199
supra-renal rest in, 298
syphilitic, 122, 288, 296
tuberculosis of, 296
Lung, adenoma of, 158
adenopapilloma of, 138, 330
brown induration of, 43, 88
catarrhal inflammation of, 25
chronic inflammation of, 327
collapse of, 337
compensatory hypertrophy in, 338
consolidation of, in tubercle, 329 (fig. 111)
embolism, 111, 212, 338, 339
endarteritis in, 329
ether vapour on, 26, 326
glandular cancer of, 339
hyperplasias in, 339
infarction, 106, 338
papilloma of, 138, 158
pigmentation in, 327
pneumonic, 23, 26
squamous epithelioma in, 340
syphilitic fibrosis of, 336
thyroid tissue in, 206
Lungs, inhalation experiments, 324
inhalation of irritant gases, 326
lymphatics of, 324
lymphosarcoma in, 138
osteomata, 240, 249
tumours of, 339
Lupus, 56, 117, 119
Luschka's glands, dilatation of, 289
Lymphadenoma, 228, 230
Lymphadenomata, miliary, of peritoneum, 303
Lymphangiomata, 130, 132, 191
Lymphatics, chronic inflammation of, 236
Lymphocystosarcoma, 192
Lymphoma of larynx, 323
Lymphomata, 169, 228
of lungs, 325
Lymphosarcoma, 150, 227, 344
Lymphosarcomata of brain, 404

Macrocytes and Macrophages, 41, 42, 43, 44, 51, 62, 225, 328
Macroglossia, 132
Macroheilia (hypertrophy of lips), 132
Macromelia (hypertrophy of cheeks), 133
Malaria, parasite in, 90, 108
pigment in, 89, 109
Malignant pustule, 107, 108
transformation, 161, 350
Mamma, tumours of, 352

Mammary abscess, chronic, 58
tumour, types of, 362
analysis of, 363
Marrow, changes in cancer, 237
changes in phthisis (chronic), 237
in leukæmia, 232
in pernicious anæmia, 236
Mastitis, carcinomatosa, 364
Mediastinal tumours, 340
Melanæmia, 90
Melanin, 91
Melanosis of arachnoid, 376
Melanotic dermoids, 317
epithelioma, 164
sarcoma, 91, 147, 151
tongue, 91
tumour of liver, 283
Meningitis, 389
chronic, 390
syphilitic, 390
tubercular, 390
Meningocele, 190
Meningo-encephalocele, 190
Mercury, a cause of enteritis, 309
poisoning, calcification in kidney in, 94
Metastases, epithelial, 163
leucocytic in leukæmia, 235
Methæmoglobin, 88
Microsporon furfur, 125
Miescher's Tubes, 417
Mitoses in repair, 72
Mitosis, demonstration of, 60
Molluscum contagiosum, 156
fibrosum, 133, 136
Morphœa, 255
Morvan's disease, 406
Mucin, 79, 80
Mucous membranes, 30, 81, 157. *See* also Special Tracts.
membranes, cysts of, 192
Muscle, atrophy of, cause of, 366
classification of tumours of, 368
degenerations of, 75, 368
fibre, atrophic proliferation of, 392
in pseudo-hypertrophic paralysis, 79
regeneration of, 67, 68, 365
Muscular hypertrophy, 366
system, 365
Mycosis or Granuloma fungoides, Note, 433
mucorina, 124
Myelitis, acute, 377, 378, 380
Myelitis, acute, *(continued)*
compression, 377, 378
concussion, 378
of hydrophobia, 380 (fig. 119)
Myeloid sarcomata, 146
Myelospongium, 370
Myocarditis, acute and chronic, 215
Myocardium, hyaline change in, 81
Myofibroma, 129, 369
Myolipoma, 367
Myolipomata of spinal cord, 401
Myomata, congenital, 368
(leiomyomata, rhabdomyomata), 128
of muscle of artery, 132
uterine, 129
Myosarcoma, 279, 369
of uterus, 350
Myositis ossificans progressiva, 142
Myxangioitis hyalinosa, 343
Myxochondromata, 139
Myxœdema, 80, 239
Myxomata, 136, 145, 360

Nasal Polypus, 134
cavity, tumours of, 320
Necrobiosis, 97
Necrosis, 31, 35
coagulation, 97, 216
Nævi, cysts in, 190
in liver, 169
Nævo-lipoma, 132
Nævus, 130, 317
muscle fibres in, 310
Neck, cystic glands in, 199
Nematodes, 65, 336, 411
Neoplasms, in chronic inflammation, 35, 47, 48
Nephritis, 33
diffuse, (phthisis), 267 (fig. 96)
hydro-, 264, 265
in diphtheria, 103
interstitial, 185, 262, 264, 271
of Bright's disease, 270
parenchymatous, 277 (fig. 103)
pyelo-, 264, 265
scarlatinal, 271
streptococcus in, 262
suppurative, 266
Nerve, atrophic proliferation of, 382
cells, swelling, vacuolation and fatty degeneration of, 376

Nerve (*continued*)
changes in peripheral after section, 372, 373
degeneration, 11, 68, 377, 392
hyaline changes in, 382
round-celled sarcoma of optic, 149 (fig. 55)
tissue, staining, 14, 371
tumours, 400
multiple embryonic origin of, 400
Nerves, regeneration of, 393
Nervous system, 369
heterotopia of grey matter, 396, 397
Neural canal, abnormalities of, 399
double, 397
Neuritis, 392
alcoholic, 396
cutaneous, 396
diphtheritic, 394
in diabetes and phthisis, 396
infective multiple, 395
of hydrophobia, 395
of leprosy, 395
peripheral, from metallic poisoning, 392
Neuroblasts, 371, 373
Neurofibromata, 133, 136, 400, 402
Neuroglia hyperplasia, 387
Neuroma, amputation, 127, 373, 400
amyelinic, 128
Neuromata, 69, 127, 357, 404
ganglionic, 128
Neuromycosis, 395
Noma, 101, 305
Nutmeg liver, 89

Odontomata, 141, 207, 250
Œdema of serous cavities, 302
Œdematous degeneration, 75
Oidium albicans, 306
Oil cysts, 196
Omentum, cancer of, 304
cysts of, 304
in chronic peritonitis, 301
origin of, cancer of, 200
Oosarcomata, 345
Orbit, glioma of, 404
Orchitis, 344
Osseous metaplasia, in muscle, 368
Ossification, 71, 95
Osteitis, deformans, 244
osteoplastic, 247
rarefactive, 246
Osteo-arthritis, hypertrophic, 241
Osteoblasts, 70
Osteoclasts, 65, 71, 241
Osteogenesis imperfecta, 243
Osteomalacia, 242, 294
Osteomata, 141, 249, 402
Osteomyelitis, 104
increase of leucocytes in, 226
Osteophytes, 140, 142
Osteosarcomata, 113, 143, 249
Otitis suppurativa, aspergillus in, 124
Ovary, adenofibroma of, 134
corpora fibrosa of, 346
cysts of, 182, 345
dermoids of, 205
follicular hypertrophy of, 345
solid tumours of, 345, 346
Ovula nabothi, 193
Oxalic acid, 94
Oxyuris vermicularis, 413
Ozæna, 320

Pachydermia laryngis, 157, 322
Pachymeningitis, 389
hypertrophic annular, 391
Paget's disease of bone, 244
of epithelium, 165, 417
Pancreas, cysts of, 187, 299
in diabetes, 299
malignant tumours of, 299
parenchymatous changes in, 299
rests of, 300
Pancreatic duct, occlusion of, 299
Pancreatitis, acute, 299
chronic, 299
Papilloma, 137, 155, 158, 172, 253
of bladder, 280 (fig. 61)
of lung, 138, 158, 330
of ovary, 346
Papillomata in pelvis of kidney, 280
intracystic, 182
Papillo-sarcoma of lung, 255
Parasites, a cause of cysts in liver, 187
animal, 408
calcification of, 96
Pelvis of kidney, changes in, 280
Pemphigus, 250
Penis, cavernous endothelioma of, 344

Periacinous tissue, glandular, in congenital tumours, 357
Periarteritis, miliary cause of aneurism, 222
Peri-bronchitis, 329
Pericanalicular hyaline transformation, 360
Pericarditis, acute exudative, 27
Perichondroma, 139
Perihepatitis, 296, 301
Perimetritis, 301
Periostitis, infective, 104
Peripheral neuritis, 69
Peritoneum, dermoid of, 204
hyperplasias of, 303
miliary lympho-adenomata of, 303
œdema of, 302
origin of growths in, 200
pseudo-tuberculosis of, 413
rests in, 304
Peritonitis, acute, 28, 300
chronic, 301
malignant, 301, 302
tubercular, 301, 302
Perityphlitis, 301
Pernicious anæmia, blood in, 236
liver in, 89
marrow in, 236
Phagedæna, sloughing, 35, 101
Phagocytes, 23, 26, 41, 43, 425
Pharyngitis, 306, 313
diphtheritic, 31
Phleboliths, 95, 212
Phlebosclerosis, 220
Phlegmasia alba dolens, 39
Phlegmonous erysipelas, 100
Phosphorus poisoning, 74, 77
Phthisis, 52, 117, 334
and pneumokoniosis, 237, 238
atrophic cirrhosis of stomach in, 313
thyroid in, 240
Pigment in fatty degeneration, 76
in glands, 226
Pigmentation, 56, 66, 85, 87, 91
bile, 90
in epithelial rests, 159
in lung, 331, 337
in malaria, 90, 109
in nervous system, 376
in sarcoma, 147, 151
of liver cells, 77, 282
Pigmented dermoid of tongue, epithelioma of liver, 298
Pigment in old wounds, 67
in warts, 156
Pineal gland, 128, 180
Pituitary body, 180
in acromegaly, 240, and Note, 437
Pityriasis rubra, 254
Pityriasis versicolor, 125, 252
Placenta, hæmoidin in, 88
Plasma cells, 44, 425
Pleura, tumours of, 340
Pleurisy, 27, 329, 332
Pleuro-pneumonia, 332
Pneumococcus, Fränkel's, 331
Pneumonia, 23, 102, 331
collapse of lung in chronic, 337
hypostatic, 330
pleurogenous, 332
verminosa, 330, 412
Pneumokoniosis, 324, 327
Pneumonomycosis, 336
Poliomyelitis, 378
Polypi, 80, 129, 134, 144
Portal obstruction, 78, 288
Portal vessels, endophlebitis of, 298
Precancerous changes, 154, 171, 354, 363, 364
in mucous membranes, 157
Precancerous conditions in larynx, 323
in uterus, 347
Prepuce, cholesteatomata of, 343
Productive inflammation, 23
Prostate, enlargements of, 342
fibro-myoma of, 280
tumours of, 280
Prostatic concretions, 342
Prostatitis chronic, 343
Psammomata, 404
Pseudo-hypertrophic paralysis, 367
Pseudo-tuberculosis, 112, 118, 119, 124, 335
of peritoneum, 413
Psoriasis, 251
lingualis, 157
nasalis, 157, 320
preputialis, 156
Psorospermosis, 291, 253
Psorosperms, 408
Pulmonary gregarinosis, 417
Pus, 35, 40
absorption of, 41
in actinomycosis, 114
Pustule, small-pox, 251 (fig. 95)
Pyæmia, constitutional changes in, 106

Pyæmic processes, 104
Pyelitis, 265 (fig. 97)
Pyogenic membrane, 58
Pyo-nephrosis, 278
Peyer's patches in typhoid, 103

Rainey's corpuscles, 418
Rankenangioma, 132
Ranken-neuroma, 136
Ranulæ, 188
Rarefaction in fractures of bone, 71
Rathke's pouch, 180
Raynaud's disease, 401
Red corpuscles, changes in, 208
  nucleated in leukæmia, 234
  staining of, 10, 15, 19
Red nucleated corpuscles in pernicious anæmia, 236
  in repair, 39
Repair, capillaries, 66, 67
  fate of exudates in, 38
  hyperplasias in, 38
  mitoses in, 72
  of wounds, 60
  tissue in, 22, 42
Relapsing fever, parasite in, 109
Respiratory system, 320
Rests, 130
  becoming sarcomatous, 146, 149
  cartilage, 139, 179
  description, 198
  enamel germ, 195
  epithelial, 159
  epithelial in brain, 166, 168
  giving rise to cysts, 180
  gland and duct, and their tumours, 170, 171
  in brain and spinal cord, 201, 401
  in kidney, 198
  in mamma, 187, 353
  in mediastinum, 340
  in neck, 199
  in peritoneum, 200, 304
  in testis, 183, 201, 344
  liver, 187, 199, 298
  of pancreas, 300
  oophoritic, 183
  origin of, 370
  striped muscle, in uterus, 351
  suprarenal, in liver, 298
  Wolffian body, 186
Retrogressive changes, 112
Retroperitoneal tumours, 304
Rhabdomyoma, of testis, 344
  of uterus, 351
  pigmented, 352
Rhabdomyomata, 79, 130
Rheumatoid arthritis, 245
Rhinoscleroma, 320
Rickets, 242
  fœtal, 243
  liver in, 296
Rodent ulcer, 164 (fig. 65)

Saccharomyces albicans, 125
Salpingitis, 347
Sapræmia, 102
Sarco-carcinomata, 167
Sarcoma, dissemination of, 148
  infiltrating heart, 150
  melanotic, 91, 151
    of vagina, 352
  myeloid, 152 (fig. 57)
  necrosis in, 97, 149
  of ovary, 346
  of skin, 148
  of testis, 344
  periacinous, 358
  plexiforme, 151, 164
  round-celled, 149 (fig. 54)
  spindle-celled, 151
  stroma of, 147
  vessels of, 147
Sarcomata, 145
  calcifying, 153
  classification of, 146
  congenital, muscle and nerve-fibres in, 148
  (melanotic), of alimentary canal, 317
  mixed, from rests, 149
  of kidney, 278
  periacinous, 358
Sarcomatous changes in neurofibromata, 136
Scab, healing under, 63
Scabies, 252
Scalp, atheromatous cysts of, (Wens), 194
  papilloma of, 155 (fig. 59)
Scirrhus, cancer, 175, 359
Sclerodactyly, 406
Scleroderma, 254

Scleroderma, 406
Scleroses of brain and spinal cord, 381, 382
Sclerosis, as a neoplasm, 382
disseminated, 383
neuroglia, 386
of cord, staining, 15
of Goll's column, 384 (fig. 116)
of posterior columns, 384 (fig. 117)
system, 384
Sclerostoma in monkeys, 413
Scrotum, rodent ulcer of, 165
Sebaceous cyst, 154, 160 (fig. 81)
cysts, papillomata of, 137
glands, hypertrophy and adenoma of, 172
Septicæmia, tyrosin in, 96
Sequestrum, 55, 66
Serous surfaces, 27, 29, 38
Sesamoid bones, 140
Siderosis, 86
Silicosis, 86
Silk ligatures, 66
Sinus, 59
Skin, condylomata of, 137
disease of, 250
inflammation of, 250
multiple fibromata of, 136
neurofibroma of, 133
papilloma of, 137 (fig. 53)
sarcoma of, 148
ulceration of, 252
Skull, tumours of base of, 320
Slough, 36, 55, 64
Smegma præputii, 166
Solar plexus, and bronzing of skin, 231
in Addison's disease, 238
Soot-cell, 43
Sphacelation, 37
Spider cells in dementia paralytica, 382
Spina bifida, 190
Spinal cord, disseminated fibromata in, 384
rests in, 201
systems, (morphological), 384
Spirillum Obermeieri, 110
Spleen, cavernous angioma of, 169
in anthrax, 108
in leukæmia, 233
in lymphadenoma, 230
in malaria, 109
in pernicious anæmia, 236
in pernicious anæmia, pigmentation of, 237
leucin in, 96
sago or lardaceous, 84 (fig. 32)
Spleens, accessory, 199
Splenic anæmia, 235
fever, 107
Sponge-grafting, 64
Spreading gangrene, 35
Staphylococci, 40
in suppuration, 104
Staphylococcus in kidney of malignant endocarditis, 105
Stasis in inflammation, 22
Stomach, atrophy and dilatation of, 315
cancer of, 313
cirrhosis of, in phthisis, 313
post-mortem digestion of, 308
ulceration, 307
ulceration of, in anæmia, 308
Stomatitis, 305
Streptococci in abscesses, 104
in hospital gangrene, 101
in phlegmonous cutaneous erysipelas, 101
in wound diphtheria, 101
staining of, 101
Stricture of urethra, 343
Stroma of adenoma, 174
of ovarian and testicular cysts, 184
of tumours, 353-359
surrounding tumour, nature and changes in, 177, 178
Strongylus vasorum, 111
Suppuration, chronic, 81
Suprarenal rests in kidney, 258, 279
in liver, 298
Suprarenals, accessory, 198, 239
diseases of, 238
Synovial cysts, 189
Syphilis, 120
a cause of enteritis, 309
congenital, 123
hereditary, 389
lardaceous degeneration in, 82
of bone, 248
of larynx, 321
of lung, 336
of testis, 345
small round cells in, 49
Syphilitic cirrhosis of vessels of liver, 124, 296

Syphilitic (*continued*)
endarteritis, 121
hyperplasia, 390
inflammation, diffuse chronic, 122 (figs. 44 and 45)
kidney, 269
liver, 288, 296
Syringomyelia, 369, 397
atrophic changes in, 406
congenital, 398
in compression myelitis, 398
Syringo-myelocele, 190
Sweat glands, hypertrophy and adenoma of, 172

Tabes dorsalis, 384, 388
perivascular fibrosis in, 388
neuritis in, 396
Tæniæ, 410
Teeth sacs, cysts of, 195
Teratomata, 144, 206, 207
Testicular rests, 344, 201
Testis, cancer of, 344
cartilage formations in, 140
cysts of, 183, 184, 344
ovarian rests in, 183, 184
sarcoma of, 344
Thomsen's disease, 366, 368
Thorax, ciliated cysts in, 193
Thrombosis, 45, 209
Thrombi, changes in and fate of, 211
vascularisation, 211
Thrombus, hyaline, 210
Thrush, 125
Thymus, in acromegaly, 240
Thyroid, cancer of, 240
cysts of, 188
extirpation of, 332
gland, colloid in, 80
in acromegaly and phthisis, 240
in myxœdema, 239
tissue in lung, 200
Thyroids, accessory, 199
Tinea tonsurans, 124
Tongue, black, 317
cancer of, 113
cyst of, 181
fibroma of, 317
nævi of, 317
pigmented dermoid of, 91
precancerous changes in, 157
ulcers of, 306
ulcus migrans of, 306
Tonsillitis, 306
Trachea, 320
epithelioma of, 323
inflammation of, 320
nematodes in, 413
tumours of, 322
Trauma (excessive callus), 143
Traumatic gangrene, spreading, 37
Trematodes, 415
Trichina spiralis, 414 (fig. 127)
Trichinosis, 413
Tricophyton tonsurans, 124
Trophoneuroses, 405
Tubercle bacilli, 17, 44, 116
caseous material, 52
crude, in central nervous system, 391
hyaline changes in, 81
lardaceous degeneration in, 81
of larynx, 321
of liver, 296
of lung, 329, 333
of lung, emphysema, 53
macrocytes in, 44
of testis, 345
variations in different animals of the, 334
Tubercular abscess, 58
granuloma, 49
granulomata, situations in lungs of, 335
inflammation, fibrous nodules in, 52 (fig. 22)
peritonitis, pseudo-, 113
ulceration of intestine, 312 (fig. 110)
Tuberculosis, acute miliary, 117, 334
Tumours, 126
congenital and acquired, 355, 357
of alimentary canal, 316
of brain and spinal cord, 401
of kidney, 278
of liver capsule, 297
of lungs, 339
of male breast, 364
of muscle, 368, 369
of nerves, 400, 402
of peritoneum, 303
of pleura, 340
simple, of framework tissue, 133
time of origin of congenital, 369, 370
types of mammary, 362, 363
Typhilitis, 309

Typhoid, 102
gland hyperplasia, in 226
intestine in, 310
parenchymatous changes in, 81, 311
Typhus, pigmentation in, 89
Tyrosin crystals, 96

Ulceration, 54
corneal, 56
dysenteric, 55
of stomach, 307
Ulcerative endocarditis, 104
stomatitis, 305
Ulcer perforating, 252, 406
Ulcers, marginal epithelium of, 157
Ulcer, typhoid, 310 (fig. 109)
Union by granulation, 63
of cut nerves, 68
of fractured bone, 69, 70
Urachus, cysts of, 185
Urate of soda in kidney, 92
in muscle, 92 (fig. 34)
reactions, 93
Urethra, stricture of, 343
Urinary system, 257
cysts of, 184
Urobilin, 89
Urticaria, 250
Uterine myomata, 129
papilloma of, 137
polypi, 129, 348
tumours, stratification of, 348, 349
Uterus, 347
adenofibroma of, 134
adenoma destruens of, 176, 350 (fig. 74)
atypical epithelioma of, 176
carcinoma of, 167
chronic inflammatory processes in, 167, 347
Uterus (*continued*)
cysts of mucous membrane of, 193
epithelial proliferation in, 157
hyperplasia, 175
myofibroma of, 129, 350
myosarcoma of, 350
papilloma of, 137
precancerous conditions in, 171, 347
rhabdomyoma, 351

Vagina, cysts of, 183, 352
epithelial changes in, 352
Vascular system, 208
Vascularisation of exudate, 45
of thrombi, 211
Vesical diverticula, 185
Vocal cords, adenofibroma of, 134
Vulva, scirrhoid squamous epithelioma of, 352 (fig. 63)

Wandering cells, pigmented, in Addison's disease, 91
Wart, 156
Warts, congenital, 355
Wens, 133, 194
White corpuscles, changes in, 209
eosinophilous, 209
Wooldridge's thymus extract, 210, 214
Wound diphtheria, 101
of fourth day, 66
of tenth day, 61 (fig. 24)
Wounds, healing of, 60
of alimentary canal, 319

Xanthoma, 145

Zenker's degeneration, 81, 102

London: Printed by H. K. Lewis, 136 Gower Street, W. C.

CATALOGUE OF WORKS

PUBLISHED BY

H. K. LEWIS

136 GOWER STREET, LONDON, W.C.

Established 1844.

SIR WILLIAM AITKEN, KNT., M.D., F.R.S.
Professor of Pathology in the Army Medical School.

ON THE ANIMAL ALKALOIDS, THE PTOMAINES, LEUCOMAINES, AND EXTRACTIVES IN THEIR PATHOLOGICAL RELATIONS. Second edition, Crown 8vo, 3s. 6d. [*Now ready.*

E. CRESSWELL BABER, M.B. LOND.
Surgeon to the Brighton and Sussex Throat and Ear Dispensary.

A GUIDE TO THE EXAMINATION OF THE NOSE, WITH REMARKS ON THE DIAGNOSIS OF DISEASES OF THE NASAL CAVITIES. With Illustrations, small 8vo, 5s. 6d.

G. GRANVILLE BANTOCK, M.D., F.R.C.S. EDIN.
Surgeon to the Samaritan Free Hospital for Women and Children.

I.

ON THE USE AND ABUSE OF PESSARIES. Second Edit., with Illustrations, 8vo, 5s.

II.

ON THE TREATMENT OF RUPTURE OF THE FEMALE PERINEUM IMMEDIATE AND REMOTE. Second Edition, with Illustrations, 8vo, 3s. 6d.

III.

A PLEA FOR EARLY OVARIOTOMY. Demy 8vo, 2s.

FANCOURT BARNES, M.D., M.R.C.P.
Physician to the Chelsea Hospital for Women; Obstetric Physician to the Great Northern Hospital, &c.

A GERMAN-ENGLISH DICTIONARY OF WORDS AND TERMS USED IN MEDICINE AND ITS COGNATE SCIENCES. Square 12mo, Roxburgh binding, 9s.

1000
21/3/90

ASHLEY W. BARRETT, M.B. LOND., M.R.C.S., L.D.S.

Dental Surgeon to, and Lecturer on Dental Surgery and Pathology in the Medical School of, the London Hospital.

DENTAL SURGERY FOR GENERAL PRACTITIONERS AND STUDENTS OF MEDICINE. Second edition, With Illustrations, cr. 8vo. [*Just ready.*

[LEWIS'S PRACTICAL SERIES.]

ROBERTS BARTHOLOW, M.A., M.D., LL.D.

Professor of Materia Medica and Therapeutics in the Jefferson Medical College of Philadelphia, &c., &c.

I.

A PRACTICAL TREATISE ON MATERIA MEDICA AND THERAPEUTICS. Seventh Edition, Revised and Enlarged, 8vo, 18s. [*Just published.*

II.

A TREATISE ON THE PRACTICE OF MEDICINE, FOR THE USE OF STUDENTS AND PRACTITIONERS. Fifth Edition, with Illustrations, large 8vo, 21s.

H. CHARLTON BASTIAN, M.A., M.D., F.R.S.

Examiner in Medicine at the Royal College of Physicians; Professor of the Principles and Practice of Medicine in University College, London; Physician to University College Hospital, &c.

PARALYSES: CEREBRAL, BULBAR, AND SPINAL. A MANUAL OF DIAGNOSIS FOR STUDENTS AND PRACTITIONERS. With numerous Illustrations, 8vo, 12s. 6d.

GEO. M. BEARD, A.M., M.D.

Fellow of the New York Academy of Medicine, &c.

AND

A. D. ROCKWELL, A.M., M.D.

Professor of Electro-Therapeutics in the New York Post Graduate Medical School.

I.

A PRACTICAL TREATISE ON THE MEDICAL AND SURGICAL USES OF ELECTRICITY. Including Localized and General Faradization; Localized and Central Galvanization; Franklinization; Electrolysis and Galvano-Cautery. Sixth Edition. With nearly 200 Illustrations, roy. 8vo, 28s. [*Just published.*

II.

NERVOUS EXHAUSTION (NEURASTHENIA) ITS HYGIENE, CAUSES, SYMPTOMS AND TREATMENT. Second edition, 8vo, 7s. 6d.

E. H. BENNETT, M.D., F.R.C.S.I.

Professor of Surgery, University of Dublin.

AND

D. J. CUNNINGHAM, M.D., F.R.C.S.I.

Professor of Anatomy and Chirurgery, University of Dublin.

THE SECTIONAL ANATOMY OF CONGENITAL CŒCAL HERNIA. With coloured plates, sm. folio, 5s. 6d.

A. HUGHES BENNETT, M.D., M.R.C.P.
Physician to the Hospital for Epilepsy and Paralysis, Regent's Park, and Assistant Physician to the Westminster Hospital.

I.

A PRACTICAL TREATISE ON ELECTRO-DIAGNOSIS IN DISEASES OF THE NERVOUS-SYSTEM. With Illustrations, 8vo, 8s. 6d.

II.

ILLUSTRATIONS OF THE SUPERFICIAL NERVES AND MUSCLES, WITH THEIR MOTOR POINTS; a knowledge of which is essential in the Art of Electro-Diagnosis. (Extracted from the above). 8vo, paper cover, 1s. 6d.; cloth, 2s.

HORATIO R. BIGELOW, M.D.
Permanent Member of the American Medical Association; Fellow of the British Gynæcological Society, &c.

GYNÆCOLOGICAL ELECTRO-THERAPEUTICS. With an Introduction by Dr. Georges Apostoli. With Illustrations, demy 8vo, 8s. 6d.

DR. THEODOR BILLROTH.
Professor of Surgery in Vienna.

GENERAL SURGICAL PATHOLOGY AND THERAPEUTICS. In Fifty-one Lectures. A Text-book for Students and Physicians. With additions by Dr. Alexander von Winiwarter, Professor of Surgery in Luttich. Translated from the Fourth German edition with the special permission of the Author, and revised from the Tenth edition, by C. E. Hackley, A.M., M.D. Copiously illustrated, 8vo, 18s.

DRS. BOURNEVILLE AND BRICON.

MANUAL OF HYPODERMIC MEDICATION. Translated from the Second Edition, and Edited, with Therapeutic Index of Diseases, by ANDREW S. CURRIE, M.D. Edin., &c. With Illustrations, crown 8vo, 6s.

G. H. BRANDT, M.D.

I.

ROYAT (LES BAINS) IN AUVERGNE, ITS MINERAL WATERS AND CLIMATE. With Frontispiece and Map. Second edition, crown 8vo, 2s. 6d.

II.

HAMMAM R'IRHA, ALGIERS. A Winter Health Resort and Mineral Water Cure Combined. With Frontispiece and Map, crown 8vo, 2s. 6d.

GURDON BUCK, M.D.

CONTRIBUTIONS TO REPARATIVE SURGERY: Showing its Application to the Treatment of Deformities, produced by Destructive Disease or Injury; Congenital Defects from Arrest or Excess of Development; and Cicatricial Contractions from Burns. Illustrated by numerous Engravings, large 8vo, 9s.

MARY BULLAR & J. F. BULLAR, M.B. CANTAB., F.R.C.S.

RECEIPTS FOR FLUID FOODS. 16mo, 1s.

STEPHEN SMITH BURT, M.D.
Professor of Clinical Medicine and Physical Diagnosis in the New York Post-graduate School and Hospital.

EXPLORATION OF THE CHEST IN HEALTH AND DISEASE. With Illustrations, crown 8vo, 6s.

DUDLEY W. BUXTON, M.D., B.S., M.R.C.P.
Administrator of Anæsthetics at University College Hospital and the Hospital for Women, Soho Square.

ANÆSTHETICS THEIR USES AND ADMINISTRATION. Crown 8vo, 4s. [LEWIS'S PRACTICAL SERIES.]

HARRY CAMPBELL, M.D., B.S. LOND., M.R.C.S.
Assistant Physician and Pathologist to the North-West London Hospital.

THE CAUSATION OF DISEASE: An exposition of the ultimate factors which induce it. Demy 8vo, 12s. 6d.

ALFRED H. CARTER, M.D. LOND.
Member of the Royal College of Physicians; Physician to the Queen's Hospital, Birmingham; late Examiner in Medicine for the University of Aberdeen, &c.

ELEMENTS OF PRACTICAL MEDICINE. Fifth Edition, crown 8vo, 9s. [*Just published.*

P. CAZEAUX.
Adjunct Professor in the Faculty of Medicine of Paris, &c.
AND
S. TARNIER.
Professor of Obstetrics and Diseases of Women and Children in the Faculty of Medicine of Paris.

OBSTETRICS: THE THEORY AND PRACTICE; including the Diseases of Pregnancy and Parturition, Obstetrical Operations, &c. Seventh Edition, edited and revised by ROBERT J. HESS, M.D., with twelve full-page plates, five being coloured, and 165 wood-engravings, 1081 pages, roy. 8vo, 35s.

F. H. CHAMPNEYS, M.A., M.D. OXON., F.R.C.P.
Obstetric Physician and Lecturer on Obstetric Medicine at St. George's Hospital: Examiner in Obstetric Medicine in the University of London, &c.

EXPERIMENTAL RESEARCHES IN ARTIFICIAL RESPIRATION IN STILLBORN CHILDREN, AND ALLIED SUBJECTS. Crown 8vo, 3s. 6d.

W. BRUCE CLARKE, M.A., M.B. OXON., F.R.C.S.
Assistant Surgeon to, and Senior Demonstrator of Anatomy and Operative Surgery at, St. Bartholomew's Hospital; Surgeon to the West London Hospital; Examiner in Surgery to the University of Oxford.

THE DIAGNOSIS AND TREATMENT OF DISEASES OF THE KIDNEY AMENABLE TO DIRECT SURGICAL INTERFERENCE. Demy 8vo, with Illustrations, 7s. 6d.

JOHN COCKLE, M.A., M.D.
Physician to the Royal Free Hospital.

ON INTRA-THORACIC CANCER. 8vo, 4s. 6d.

ALEXANDER COLLIE, M.D. ABERD., M.R.C.P. LOND.
Medical Superintendent of the Eastern Hospitals.

ON FEVERS: THEIR HISTORY, ETIOLOGY, DIAGNOSIS, PROGNOSIS, AND TREATMENT. Illustrated with Coloured Plates, crown 8vo, 8s. 6d. [LEWIS'S PRACTICAL SERIES.]

M. P. MAYO COLLIER, M.B., M.S. LOND., F.R.C.S. ENG.
Professor of Comparative Anatomy and Physiology at the Royal College of Surgeons, England, &c.

THE PHYSIOLOGY OF THE VASCULAR SYSTEM. Illustrations, 8vo, 3s. 6d.

WALTER S. COLMAN, M.B., M.R.C.P. LOND.
Pathologist and Registrar to the National Hospital for the Paralysed and Epileptic; Formerly Assistant to the Professor of Pathology in the University of Edinburgh.

SECTION CUTTING AND STAINING: A Practical Guide to the Preparation of Normal and Morbid Histological Specimens. Crown 8vo, 3s. [*Now ready.*

ALFRED COOPER, F.R.C.S.
Surgeon to the St. Mark's Hospital for Fistula and other Diseases of the Rectum.

A PRACTICAL TREATISE ON THE DISEASES OF THE RECTUM. Crown 8vo, 4s.

W. H. CORFIELD, M.A., M.D. OXON.
Professor of Hygiene and Public Health in University College, London.

DWELLING HOUSES: their Sanitary Construction and Arrangements. Second Edit., with Illustrations. Cr. 8vo, 3s. 6d.

J. LEONARD CORNING, M.A., M.D.
Consultant in Nervous Diseases to St. Francis Hospital.

A PRACTICAL TREATISE ON HEADACHE, NEU-RALGIA, SLEEP AND ITS DERANGEMENTS, AND SPINAL IRRITATION. With an Appendix—Eye Strain, a Cause of Headache. By DAVID WEBSTER, M.D. Second edition, Demy 8vo, 7s. 6d.

EDWARD COTTERELL, M.R.C.S. ENG., L.R.C.P. LOND.
Late House Surgeon, University College Hospital.

ON SOME COMMON INJURIES TO LIMBS; their Treatment and After-treatment, including Bone-setting (so-called). With Illustrations, small 8vo, 3s. 6d.

CHARLES CREIGHTON, M.D.

I.

ILLUSTRATIONS OF UNCONSCIOUS MEMORY IN DISEASE, including a Theory of Alteratives. Post 8vo, 6s.

II.

CONTRIBUTIONS TO THE PHYSIOLOGY AND PATHOLOGY OF THE BREAST AND LYMPHATIC GLANDS. New Edition with additional chapter, with wood-cuts and plate, 8vo, 9s.

III.

BOVINE TUBERCULOSIS IN MAN: An Account of the Pathology of Suspected Cases. With Chromo-lithographs and other Illustrations, 8vo, 8s. 6d.

H. RADCLIFFE CROCKER, M.D. LOND., B.S., F.R.C.P.
Physician, Skin Department, University College Hospital.

DISEASES OF THE SKIN; THEIR DESCRIPTION, PATHOLOGY, DIAGNOSIS, AND TREATMENT. With 76 Illustrations, 8vo, 21s. [*Now ready.*

EDGAR M. CROOKSHANK, M.B. LOND., F.R.M.S.
Professor of Comparative Pathology and Bacteriology in, and Fellow of King's College, London.

I.

HISTORY AND PATHOLOGY OF VACCINATION. Vol. I., A Critical Inquiry. Vol. II., Selected Essays, (Edited) including works by Jenner, Pearson, Woodville, Henry Jenner, Loy, Rogers, Birch, Bousquet, Estlin, Ceely, Badcock, Auzias-Turenne, Dubreuilh and Layet. Two volumes, illustrated with 22 coloured plates, including reproductions of the plates illustrating Jenner's Inquiry, of selected plates from the work of Ceely and others, and with a reduced facsimile of an engraving of Mr. Jesty, a facsimile of the first folio of the manuscript of Jenner's original paper, a facsimile of an unpublished letter from Jenner to Mr. Head, Royal 8vo, 36s.

II.

MANUAL OF BACTERIOLOGY: being an Introduction to Practical Bacteriology. Illustrated with Coloured Plates from original drawings, and with other Illustrations in the text. Third Edition, 8vo. [*In preparation.*

III.

PHOTOGRAPHY OF BACTERIA. Illustrated with 86 Photographs reproduced in autotype, and wood engravings, royal 8vo, 12s. 6d.

RIDLEY DALE, M.D., L.R.C.P. EDIN., M.R.C.S. ENG.

EPITOME OF SURGERY, being a complete compendium of the Science and Art of Surgery. Large 8vo, 10s. 6d.

HERBERT DAVIES, M.D., F.R.C.P.
Late Consulting Physician to the London Hospital.

THE MECHANISM OF THE CIRCULATION OF THE BLOOD THROUGH ORGANICALLY DISEASED HEARTS. Edited by ARTHUR TEMPLER DAVIES, B.A. (Nat. Science Honours), M.B. Cantab., M.R.C.P.; Physician to the Royal Hospital for Diseases of the Chest; Crown 8vo, 3s. 6d. [*Just published.*

HENRY DAVIS, M.R.C.S. ENG.
Teacher and Administrator of Anæsthetics to St. Mary's and the National Dental Hospitals.

GUIDE TO THE ADMINISTRATION OF ANÆSTHE-TICS. Fcap. 8vo, 2s.

J. THOMPSON DICKSON, M.A., M.B. CANTAB.
Late Lecturer on Mental Diseases at Guy's Hospital.

THE SCIENCE AND PRACTICE OF MEDICINE IN RELATION TO MIND, the Pathology of the Nerve Centres, and the Jurisprudence of Insanity being a course of Lectures delivered at Guy's Hospital. Illustrated by Chromo-lithographic Drawings and Physiological Portraits. 8vo, 14s.

HORACE DOBELL, M.D.
Consulting Physician to the Royal Hospital for Diseases of the Chest, &c.

I.

ON DIET AND REGIMEN IN SICKNESS AND Health and on the Interdependence and Prevention of Diseases and the Diminution of their Fatality. Seventh Edition, 8vo, 10s. 6d.

II.

AFFECTIONS OF THE HEART AND IN ITS NEIGH-BOURHOOD. Cases, Aphorisms, and Commentaries. Illustrated by the heliotype process. 8vo, 6s 6d.

JOHN EAGLE.
Member of the Pharmaceutical Society.

A NOTE-BOOK OF SOLUBILITIES. Arranged chiefly for the use of Prescribers and Dispensers. 12mo, 2s. 6d.

JOHN ERIC ERICHSEN.
Ex-President of the Royal College of Surgeons; Surgeon Extraordinary to H.M. the Queen, etc.

MODERN SURGERY; its Progress and Tendencies. Being the Introductory Address delivered at University College at the opening of the Session 1873-74. Demy 8vo, 1s.

DR. FERBER.

MODEL DIAGRAM OF THE ORGANS IN THE THORAX AND UPPER PART OF THE ABDOMEN. With Letter-press Description. In 4to, coloured, 5s.

J. MAGEE FINNY, M.D. DUBL.
King's Professor of Practice of Medicine in School of Physic, Ireland, &c.

NOTES ON THE PHYSICAL DIAGNOSIS OF LUNG DISEASES. 32mo, 1s. 6d. [*Now ready.*

AUSTIN FLINT, M.D., LL.D.
Professor of Physiology and Physiological Anatomy in the Bellevue Hospital Medical College, New York; visiting Physician to the Bellevue Hospital, &c.

I.

A TEXT-BOOK OF HUMAN PHYSIOLOGY. Fourth edition, Illustrated by plates, and 316 wood engravings, large 8vo, 25s.

II.

THE PHYSIOLOGY OF THE SPECIAL SENSES AND GENERATION; (Being Vol. V. of the Physiology of Man). Roy. 8vo, 18s.

J. MILNER FOTHERGILL, M.D., M.R.C.P.
Late Physician to the City of London Hospital for Diseases of the Chest, Victoria Park, &c.

I.

A MANUAL OF DIETETICS. Large 8vo, 10s. 6d.

II.

THE HEART AND ITS DISEASES, WITH THEIR TREATMENT; INCLUDING THE GOUTY HEART. Second Edition, entirely re-written, copiously illustrated with woodcuts and lithographic plates. 8vo. 16s.

III.

INDIGESTION AND BILIOUSNESS. Second Edition, post 8vo, 7s. 6d.

IV.

GOUT IN ITS PROTEAN ASPECTS. Post 8vo, 7s. 6d.

V.

THE TOWN DWELLER: His Needs and His Wants. With an Introduction by B. W. RICHARDSON, M.D., LL.D., F.R.S. Post 8vo, 3s. 6d. [*Now ready.*

VI.

HEART STARVATION. (Reprinted from the Edinburgh Medical Journal). 8vo, 1s.

FORTESCUE FOX, M.D. LOND.
Fellow of the Medical Society of London.

STRATHPEFFER SPA: Its Climate and Waters. With OBSERVATIONS HISTORICAL, MEDICAL, AND GENERAL, DESCRIPTIVE OF THE VICINITY. Crown 8vo, with Map and Illustrations, 2s. 6d.

ERNEST FRANCIS, F.C.S.
Demonstrator of Practical Chemistry, Charing Cross Hospital.

PRACTICAL EXAMPLES IN QUANTITATIVE ANA-lysis, forming a Concise Guide to the Analysis of Water, &c. Illustrated, fcap. 8vo, 2s. 6d.

ALFRED W. GERRARD, F.C.S.
Examiner to the Pharmaceutical Society; Teacher of Pharmacy and Demonstrator of Materia Medica at University College Hospital.

ELEMENTS OF MATERIA MEDICA AND PHAR-MACY. Crown 8vo, 8s. 6d. [*Just published.*

HENEAGE GIBBES, M.D.
Lecturer on Physiology and on Normal and Morbid Histology in the Medical School of Westminster Hospital; etc.

PRACTICAL HISTOLOGY AND PATHOLOGY. Third Edition, revised and enlarged, crown 8vo, 6s.

C. A. GORDON, M.D., C.B.
Deputy Inspector General of Hospitals, Army Medical Department.

REMARKS ON ARMY SURGEONS AND THEIR WORKS. Demy 8vo, 5s.

JOHN GORHAM, M.R.C.S.

TOOTH EXTRACTION: a Manual on the proper mode of extracting Teeth. Third Edition, fcap. 8vo, 1s. 6d. [*Now ready.*

W. R. GOWERS, M.D., F.R.C.P., M.R.C.S.
Physician to University College Hospital, &c.

DIAGRAMS FOR THE RECORD OF PHYSICAL SIGNS. In books of 12 sets of figures, 1s. Ditto, unbound, 1s.

J. B. GRESSWELL, M.R.C.V.S.
Provincial Veterinary Surgeon to the Royal Agricultural Society.

VETERINARY PHARMACOLOGY AND THERAPEUTICS. With an Index of Diseases and Remedies. Fcap. 8vo, 5s.

SAMUEL D. GROSS, M.D., LL.D., D.C.L. OXON.
Professor of Surgery in the Jefferson Medical College of Philadelphia.

A PRACTICAL TREATISE ON THE DISEASES, INJURIES, AND MALFORMATIONS OF THE URINARY BLADDER, THE PROSTATE GLAND, AND THE URETHRA. Third Edition, revised and edited by S. W. GROSS, A.M., M.D., Surgeon to the Philadelphia Hospital. Illustrated by 170 engravings, 8vo, 18s.

SAMUEL W. GROSS, A.M., M.D.
Surgeon to, and Lecturer on Clinical Surgery in, the Jefferson Medical College Hospital, and the Philadelphia Hospital, &c.

A PRACTICAL TREATISE ON TUMOURS OF THE MAMMARY GLAND: embracing their Histology, Pathology, Diagnosis, and Treatment. With Illustrations, 8vo, 10s. 6d.

ALLAN McLANE HAMILTON, M.D.

THE MODERN TREATMENT OF HEADACHES. Square 16mo, 2s. 6d. [*Just Published.*

WILLIAM A. HAMMOND, M.D.

Professor of Mental and Nervous Diseases in the Medical Department of the University of the City of New York, &c.

I.

A TREATISE ON THE DISEASES OF THE NERVOUS SYSTEM. Seventh edition, with 112 Illustrations, large 8vo, 25s.

II.

A TREATISE ON INSANITY. Large 8vo, 25s.

III.

SPIRITUALISM AND ALLIED CAUSES AND CONDITIONS OF NERVOUS DERANGEMENT. With Illustrations, post 8vo, 8s. 6d.

ALEXANDER HARVEY, M.A., M.D.

Late Emeritus Professor of Materia Medica in the University of Aberdeen; Consulting Physician to the Aberdeen Royal Infirmary, &c.

I.

FIRST LINES OF THERAPEUTICS; as based on the Modes and the Processes of Healing, as occurring Spontaneously in Disease; and on the Modes and the Processes of Dying, as resulting Naturally from Disease. In a series of Lectures. Post 8vo, 5s.

II.

ON THE FŒTUS IN UTERO AS INOCULATING THE MATERNAL WITH THE PECULIARITIES OF THE PATERNAL ORGANISM. In a series of Essays now first collected. Fcap. 8vo, 4s. 6d.

ALEXANDER HARVEY, M.D.

Late Emeritus Professor of Materia Medica in the University of Aberdeen, &c

AND

ALEXANDER DYCE DAVIDSON, M.D., F.R.S. EDIN.

Late Regius Professor of Materia Medica in the University of Aberdeen.

SYLLABUS OF MATERIA MEDICA FOR THE USE OF STUDENTS, TEACHERS AND PRACTITIONERS. Based on the relative values of articles and preparations in the British Pharmacopœia. Eighth edition, 32mo, 1s. 6d.

K. M. HEANLEY.

Matron of Boston Cottage Hospital.

A MANUAL OF URINE TESTING. Compiled for the use of Matrons, Nurses, and Probationers. Post 8vo, 1s. 6d.

GRAILY HEWITT, M.D.

Professor of Midwifery and Diseases of Women in University College, Obstetrical Physician to University College Hospital, &c.

OUTLINES OF PICTORIAL DIAGNOSIS OF DIS- EASES OF WOMEN. Folio, 6s.

C. HIGGENS, F.R.C.S.

Ophthalmic Surgeon to Guy's Hospital; Lecturer on Ophthalmology at Guy's Hospital Medical School.

MANUAL OF OPHTHALMIC PRACTICE.
Crown 8vo, illustrations, 6s. [*Now ready.*
[LEWIS'S PRACTICAL SERIES.]

BERKELEY HILL, M.B. LOND., F.R.C.S.

Professor of Clinical Surgery in University College; Surgeon to University College Hospital and to the Lock Hospital.

THE ESSENTIALS OF BANDAGING. With directions for Managing Fractures and Dislocations; for administering Ether and Chloroform; and for using other Surgical Apparatus; with a Chapter on Surgical Landmarks. Sixth Edition, revised and enlarged, Illustrated by 144 Wood Engravings, crown 8vo, 5s.

BERKELEY HILL, M.B. LOND., F.R.C.S.

Professor of Clinical Surgery in University College; Surgeon to University College Hospital and to the Lock Hospital.

AND

ARTHUR COOPER, L.R.C.P., M.R.C.S.

Surgeon to the Westminster General Dispensary.

I.

SYPHILIS AND LOCAL CONTAGIOUS DISORDERS.
Second edition, entirely re-written, royal 8vo, 18s.

II.

THE STUDENT'S MANUAL OF VENEREAL DISEASES. Being a Concise Description of those Affections and of their Treatment. Fourth edition, post 8vo, 2s. 6d.

C. R. ILLINGWORTH, M.D. ED., M.R.C.S.

THE ABORTIVE TREATMENT OF SPECIFIC FEBRILE DISORDERS BY THE BINIODIDE OF MERCURY.
Crown 8vo, 3s. 6d.

SIR W. JENNER, Bart., M.D.

Physician in Ordinary to H.M. the Queen, and to H.R.H. the Prince of Wales.

THE PRACTICAL MEDICINE OF TO-DAY: Two Addresses delivered before the British Medical Association, and the Epidemiological Society, (1869). Small 8vo, 1s. 6d.

C. M. JESSOP, M.R.C.P.

Associate of King's College, London; Brigade Surgeon H.M. British Forces.

ASIATIC CHOLERA, being a Report on an Outbreak of Epidemic Cholera in 1876 at a Camp near Murree in India. With map, demy 8vo, 2s. 6d.

GEORGE LINDSAY JOHNSON, M.A., M.B., B.C. CANTAB.

Clinical Assistant, late House Surgeon and Chloroformist, Royal Westminster Ophthalmic Hospital, &c.

A NEW METHOD OF TREATING CHRONIC GLAUCOMA, based on Recent Researches into its Pathology. With Illustrations and coloured frontispiece, demy 8vo, 3s. 6d.

NORMAN KERR, M.D., F.L.S.

President of the Society for the Study of Inebriety; Consulting Physician, Dalrymple Home for Inebriates, etc.

INEBRIETY: its Etiology, Pathology, Treatment, and Jurisprudence. Second edition, Crown 8vo, 12s. 6d. [*Now ready.*

NORMAN W. KINGSLEY, M.D.S., D.D.S.

President of the Board of Censors of the State of New York; Member of the American Academy of Dental Science, &c.

A TREATISE ON ORAL DEFORMITIES AS A BRANCH OF MECHANICAL SURGERY. With over 350 Illustrations, 8vo, 16s.

J. WICKHAM LEGG, F.R.C.P.

Assistant Physician to Saint Bartholomew's Hospital, and Lecturer on Pathological Anatomy in the Medical School.

I.

ON THE BILE, JAUNDICE, AND BILIOUS DISEASES. With Illustrations in chromo-lithography, 719 pages, roy. 8vo, 25s.

II.

A GUIDE TO THE EXAMINATION OF THE URINE; intended chiefly for Clinical Clerks and Students. Sixth Edition, revised and enlarged, with Illustrations, fcap. 8vo, 2s. 6d.

III.

A TREATISE ON HÆMOPHILIA, SOMETIMES CALLED THE HEREDITARY HÆMORRHAGIC DIATHESIS. Fcap. 4to, 7s. 6d.

ARTHUR H. N. LEWERS, M.D. LOND., M.R.C.P. LOND.

Assistant Obstetric Physician to the London Hospital; Examiner in Midwifery and Diseases of Women to the Society of Apothecaries of London, &c.

A PRACTICAL TEXTBOOK OF THE DISEASES OF WOMEN. Second edition, Illustrations, crown 8vo, 9s. [*Just ready.*

[LEWIS'S PRACTICAL SERIES.]

DR. GEORGE LEWIN.

Professor at the Fr. Wilh. University, and Surgeon-in-Chief of the Syphilitic Wards and Skin Disease Wards of the Charité Hospital, Berlin.

THE TREATMENT OF SYPHILIS WITH SUBCUTANEOUS SUBLIMATE INJECTIONS. Translated by DR. CARL PRŒGLE, and DR. E. H. GALE, late Surgeon United States Army. Small 8vo, 7s.

LEWIS'S PRACTICAL SERIES.

Under this title Mr. LEWIS is publishing a Series of Monographs, embracing the various branches of Medicine and Surgery.

The volumes are written by well-known Hospital Physicians and Surgeons, recognized as authorities in the subjects of which they treat. The works are intended to be of a THOROUGHLY PRACTICAL nature, calculated to meet the requirements of the practitioner and student, and to present the most recent information in a compact and readable form.

HYGIENE AND PUBLIC HEALTH.

By LOUIS C. PARKES, M.D., D.P.H. LOND. UNIV., Fellow of the Sanitary Institute; Member of the Board of Examiners; Assistant Professor of Hygiene and Public Health at University College. etc. With numerous Illustrations, cr. 8vo, 9s.

MANUAL OF OPHTHALMIC PRACTICE.

By C. HIGGENS, F.R.C.S., Ophthalmic Surgeon to Guy's Hospital; Lecturer on Ophthalmology at Guy's Hospital Medical School. With Illustrations, crown 8vo, 6s.

A PRACTICAL TEXTBOOK OF THE DISEASES OF WOMEN.

By ARTHUR H. N. LEWERS, M.D. Lond., M.R.C.P. Lond., Assistant Obstetric Physician to the London Hospital; Examiner in Midwifery and Diseases of Women to the Society of Apothecaries of London, etc. Second Edition, with Illustrations, crown 8vo., 6s. *[Just ready.*

ANÆSTHETICS THEIR USES AND ADMINISTRATION.

By DUDLEY W. BUXTON, M.D., B S., M.R.C.P., Administrator of Anæsthetics in University College Hospital and the Hospital for Women, Soho Square. Crown 8vo, 4s.

TREATMENT OF DISEASE IN CHILDREN: EMBODYING THE OUTLINES OF DIAGNOSIS AND THE CHIEF PATHOLOGICAL DIFFERENCES BETWEEN CHILDREN AND ADULTS.

By ANGEL MONEY, M.D., F.R.C.P., Assistant Physician to the Hospital for Sick Children, Great Ormond Street, and to University College Hospital. Second edition, cr. 8vo, 10s. 6d. *[Just ready.*

ON FEVERS: THEIR HISTORY, ETIOLOGY, DIAGNOSIS, PROGNOSIS, AND TREATMENT.

By ALEXANDER COLLIE, M.D. Aberd., Member of the Royal College of Physicians of London; Medical Superintendent of the Eastern Hospitals; Secretary of the Epidemiological Society for Germany and Russia. Illustrated with Coloured Plates, crown 8vo, 8s. 6d.

HANDBOOK OF DISEASES OF THE EAR FOR THE USE OF STUDENTS AND PRACTITIONERS.

By URBAN PRITCHARD, M.D. Edin., F.R.C.S. Eng., Professor of Aural Surgery at King's College, London; Aural Surgeon to King's College Hospital; Senior Surgeon to the Royal Ear Hospital. With Illustrations, crown 8vo, 4s. 6d.

A PRACTICAL TREATISE ON DISEASES OF THE KIDNEYS AND URINARY DERANGEMENTS.

By CHARLES HENRY RALFE, M.A., M.D. Cantab., Fellow of the Royal College of Physicians, London; Assistant Physician to the London Hospital; Examiner in Medicine to the University of Durham, etc., etc. With Illustrations, crown 8vo, 10s. 6d.

DENTAL SURGERY FOR GENERAL PRACTITIONERS AND STUDENTS OF MEDICINE.

By ASHLEY W. BARRETT, M.B. Lond., M.R.C.S., L.S.D., Dental Surgeon to, and Lecturer on Dental Surgery and Pathology in the Medical School of, the London Hospital. Second editiou, with Illustrations, cr. 8vo. *[Just ready.*

BODILY DEFORMITIES AND THEIR TREATMENT: A HANDBOOK OF PRACTICAL ORTHOPÆDICS.

By H. A. REEVES, F.R.C.S. Edin., Senior Assistant Surgeon and Teacher of Practical Surgery at the London Hospital; Surgeon to the Royal Orthopædic Hospital, &c. With numerous Illustrations, cr 8vo, 8s. 6d.

Further volumes will be announced in due course.

LEWIS'S POCKET CASE BOOK FOR PRACTITIONERS AND STUDENTS. Designed by A. T. BRAND, M.D. Roan, with pencil, 3s. 6d. *nett.*

LEWIS'S POCKET MEDICAL VOCABULARY.
Over 200 pp., 32mo, roan, 3s. 6d.

T. R. LEWIS, M.B., F.R.S. ELECT, ETC.
Late Fellow of the Calcutta University, Surgeon-Major Army Medical Staff, &c.

PHYSIOLOGICAL AND PATHOLOGICAL RESEARCHES. Arranged and edited by SIR WM. AITKEN, M.D., F.R.S., G. E. DOBSON, M.B., F.R.S., and A. E. BROWN, B.Sc. Crown 4to, portrait, 5 maps, 43 plates including 15 chromo-lithographs, and 67 wood engravings, 30s. *nett.*

C. B. LOCKWOOD, F.R.C.S.
Hunterian Professor, Royal College of Surgeons of England; Surgeon to the Great Northern Hospital; Senior Demonstrator of Anatomy and Operative Surgery in St. Bartholomew's Hospital.

HUNTERIAN LECTURES ON THE MORBID ANATOMY, PATHOLOGY AND TREATMENT OF HERNIA. Demy 8vo, 36 illustrations, 5s.

J. S. LOMBARD, M.D.
Formerly Assistant Professor of Physiology in Harvard College.

I.

EXPERIMENTAL RESEARCHES ON THE REGIONAL TEMPERATURE OF THE HEAD, under Conditions of Rest, Intellectual Activity and Emotion. With Illustrations, 8vo, 8s.

II.

ON THE NORMAL TEMPERATURE OF THE HEAD. 8vo, 5s.

WILLIAM THOMPSON LUSK, A.M., M.D.
Professor of Obstetrics and Diseases of Women in the Bellevue Hospital Medical College, &c.

THE SCIENCE AND ART OF MIDWIFERY.
Third Edition, with numerous Illustrations, 8vo, 18s.

A. W. MACFARLANE, M.D., F.R.C.P. EDIN.
Examiner in Medical Jurisprudence in the University of Glasgow; Honorary Consulting Physician (late Physician) Kilmarnock Infirmary.

INSOMNIA AND ITS THERAPEUTICS
Medium 8vo, 12s. 6d. [*Just Published*

RAWDON MACNAMARA.

Professor of Materia Medica, Royal College of Surgeons, Ireland; Senior Surgeon to the Westmoreland (Lock) Government Hospital; Surgeon to the Meath Hospital, etc.

AN INTRODUCTION TO THE STUDY OF THE BRITISH PHARMACOPŒIA. Demy 32mo, 1s. 6d. [*Just published.*

JOHN MACPHERSON, M.D.

Inspector-General of Hospitals H.M. Bengal Army (Retired). Author of "Cholera in its Home," &c.

I.

ANNALS OF CHOLERA FROM THE EARLIEST PERIODS TO THE YEAR 1817. With a map. Demy 8vo, 7s. 6d.

II.

BATH, CONTREXEVILLE, AND THE LIME SUL-PHATED WATERS. Crown 8vo, 2s. 6d.

DR. V. MAGNAN.

Physician to St. Ann Asylum, Paris; Laureate of the Institute.

ON ALCOHOLISM, the Various Forms of Alcoholic Delirium and their Treatment. Translated by W. S. GREENFIELD, M.D., M.R.C.P. 8vo, 7s. 6d.

A. COWLEY MALLEY, B.A., M.B., B.CH. T.C.D.

PHOTO-MICROGRAPHY; including a description of the Wet Collodion and Gelatino-Bromide Processes, together with the best methods of Mounting and Preparing Microscopic Objects for Photo-Micrography. Second Edition, with Photographs and Illustrations, crown 8vo, 7s. 6d.

PATRICK MANSON, M.D., C.M.

Amoy, China.

THE FILARIA SANGUINIS HOMINIS; AND CER-TAIN NEW FORMS OF PARASITIC DISEASE IN INDIA, CHINA, AND WARM COUNTRIES. Illustrated with Plates and Charts. 8vo, 10s. 6d.

PROFESSOR MARTIN.

MARTIN'S ATLAS OF OBSTETRICS AND GYNÆCOLOGY. Edited by A. MARTIN, Docent in the University of Berlin. Translated and edited with additions by FANCOURT BARNES, M.D., M.R.C P., Physician to the Chelsea Hospital for Women; Obstetric Physician to the Great Northern Hospital; and to the Royal Maternity Charity of London, &c. Medium 4to, Morocco half bound, 31s. 6d. *nett.*

WILLIAM MARTINDALE, F.C.S.

Late Examiner of the Pharmaceutical Society, and late Teacher of Pharmacy and Demonstrator of Materia Medica at University College.

AND

W. WYNN WESTCOTT, M.B. LOND.

Deputy Coroner for Central Middlesex.

THE EXTRA PHARMACOPŒIA with the additions introduced into the British Pharmacopœia, 1885, with Medical References, and a Therapeutic Index of Diseases and Symptoms. Sixth Edition, limp roan, med. 24mo, 7s. 6d. [*Just ready.*

WILLIAM MARTINDALE, F.C.S.

Late Examiner of the Pharmaceutical Society, &c.

COCA, COCAINE, AND ITS SALTS: their History, Medical and Economic Uses, and Medicinal Preparations. Fcap. 8vo, 2s.

MATERIA MEDICA LABELS.

Adapted for Public and Private Collections. Compiled from the British Pharmacopœia of 1885. The Labels are arranged in Two Divisions:—

Division I.—Comprises, with few exceptions, Substances of Organized Structure, obtained from the Vegetable and Animal Kingdoms.

Division II.—Comprises Chemical Materia Medica, including Alcohols, Alkaloids, Sugars, and Neutral Bodies.

On plain paper, 10s. 6d. *nett.* On gummed paper, 12s. 6d. *nett.*

*** Specimens of the Labels, of which there are over 450, will be sent on application.

S. E. MAUNSELL, L.R.C.S.I.

Surgeon-Major, Medical Staff.

NOTES OF MEDICAL EXPERIENCES IN INDIA PRINCIPALLY WITH REFERENCE TO DISEASES OF THE EYE. With Map, post 8vo, 3s. 6d.

J. F. MEIGS, M.D.
Consulting Physician to the Children's Hospital, Philadelphia.

AND

W. PEPPER, M.D.
Lecturer on Clinical Medicine in the University of Pennsylvania.

A PRACTICAL TREATISE ON THE DISEASES OF CHILDREN. Seventh Edition, revised and enlarged, roy. 8vo, 28s.

Wm. JULIUS MICKLE, M.D., F.R.C.P. LOND.
Medical Superintendent, Grove Hall Asylum, London, &c.

I.

GENERAL PARALYSIS OF THE INSANE. Second Edition, enlarged and rewritten, 8vo, 14s.

II.

ON INSANITY IN RELATION TO CARDIAC AND AORTIC DISEASE AND PHTHISIS. Crown 8vo, 3s. 6d.

KENNETH W. MILLICAN, B.A. CANTAB., M.R.C.S.

THE EVOLUTION OF MORBID GERMS: A Contribution to Transcendental Pathology. Cr. 8vo, 3s. 6d.

ANGEL MONEY, M.D. LOND., F.R.C.P.
Assistant Physician to University College Hospital, and to the Hospital for Sick Children Great Ormond Street; Assistant Professor of Clinical Medicine in University College, London, &c.

I.

THE STUDENT'S TEXTBOOK OF THE PRACTICE OF MEDICINE. Fcap. 8vo, 6s. 6d. [*Just Published.*

II.

TREATMENT OF DISEASE IN CHILDREN: EMBODYING THE OUTLINES OF DIAGNOSIS AND THE CHIEF PATHOLOGICAL DIFFERENCES BETWEEN CHILDREN AND ADULTS. Second edition, crown 8vo, 10s. 6d. [*Just ready.*
[LEWIS'S PRACTICAL SERIES.]

E. A. MORSHEAD, M.R.C.S., L.R.C.P.
Assistant to the Professor of Medicine in University College, London.

TABLES OF THE PHYSIOLOGICAL ACTION OF DRUGS. Fcap. 8vo, 1s.

A. STANFORD MORTON, M.B., F.R.C.S. ENG.
Surgeon to the Royal South London Ophthalmic Hospital.

REFRACTION OF THE EYE: Its Diagnosis, and the Correction of its Errors. Third Edition, with Illustrations, small 8vo. 3s.

C. W. MANSELL MOULLIN, M.A., M.D. OXON., F.R.C.S. ENG.
Assistant Surgeon and Senior Demonstrator of Anatomy at the London Hospital; formerly Radcliffe Travelling Fellow and Fellow of Pembroke College, Oxford.

SPRAINS; THEIR CONSEQUENCES AND TREATMENT. Crown 8vo, 5s.

PAUL F. MUNDE, M.D.
Professor of Gynecology at the New York Polyclinic; President of the New York Obstetrical Society and Vice-President of the British Gynecological Society, &c.

THE MANAGEMENT OF PREGNANCY, PARTURITION, AND THE PUERPERAL STATE. Second edition, square 8vo, 3s. 6d.

WILLIAM MURRELL, M.D., F.R.C.P.
Lecturer on Pharmacology and Therapeutics at Westminster Hospital; late Examiner in Materia Medica to the Royal College of Physicians of London, etc.

I.

MASSOTHERAPEUTICS, OR MASSAGE AS A MODE OF TREATMENT. Fourth edition, with Illustrations, crown 8vo, 4s. 6d. [*Just published.*

II.

WHAT TO DO IN CASES OF POISONING. Sixth edition, royal 32mo, 3s. 6d. [*Just published.*

III.

NITRO-GLYCERINE AS A REMEDY FOR ANGINA PECTORIS. Crown 8vo, 3s. 6d.

IV.

CHRONIC BRONCHITIS AND ITS TREATMENT. Crown 8vo, 3s. 6d.

DR. FELIX von NIEMEYER.
Late Professor of Pathology and Therapeutics; Director of the Medical Clinic of the University of Tübingen.

A TEXT-BOOK OF PRACTICAL MEDICINE, WITH PARTICULAR REFERENCE TO PHYSIOLOGY AND PATHOLOGICAL ANATOMY. Translated from the Eighth German Edition by special permission of the Author, by GEORGE H. HUMPHERY, M.D., and CHARLES E. HACKLEY, M.D. Revised edition, 2 vols. large 8vo, 36s.

GEORGE OLIVER, M.D., F.R.C.P.

I.

THE HARROGATE WATERS: Data Chemical and Therapeutical, with notes on the Climate of Harrogate. Addressed to the Medical Profession. Crown 8vo, with Map of the Wells, 3s. 6d.

II.

ON BEDSIDE URINE TESTING: a Clinical Guide to the Observation of Urine in the course of Work. Fourth Edition, fcap. 8vo, 3s. 6d. [*Just published.*

SAMUEL OSBORN, F.R.C.S.

Assistant-Surgeon to the Hospital for Women; Surgeon Royal Naval Artillery Volunteers

I.

AMBULANCE LECTURES: FIRST AID. Second edition. with Illustrations, fcap. 8vo, 1s. 6d.

II.

AMBULANCE LECTURES: NURSING. With Illustrations, fcap. 8vo, 1s. 6d.

WILLIAM OSLER, M.D., F.R.C.P. LOND.

Professor of Clinical Medicine in the University of Pennsylvania, &c.

THE CEREBRAL PALSIES OF CHILDREN. A Clinical Study from the Infirmary for Nervous Diseases, Philadelphia. Demy 8vo, 5s. [*Just Published.*

ROBERT W. PARKER.

Surgeon to the East London Hospital for Children, and to the Grosvenor Hospital for Women and Children.

I.

TRACHEOTOMY IN LARYNGEAL DIPHTHERIA, AFTER TREATMENT AND COMPLICATIONS. Second Edition. With Illustrations, 8vo, 5s.

II.

CONGENITAL CLUB-FOOT; ITS NATURE AND TREATMENT. With special reference to the subcutaneous division of Tarsal Ligaments. 8vo, 7s. 6d.

LOUIS C. PARKES, M.D., D.P.H. LOND. UNIV.

Fellow of the Sanitary Institute; Member of the Board of Examiners; Assistant Professor of Hygiene and Public Health at University College, &c.

HYGIENE AND PUBLIC HEALTH. With numerous Illustrations, crown 8vo, 9s. [LEWIS'S PRACTICAL SERIES.]
[*Just Published.*

JOHN S. PARRY, M.D.
Obstetrician to the Philadelphia Hospital, Vice-President of the Obstetrical and Pathological Societies of Philadelphia, &c.

EXTRA-UTERINE PREGNANCY; Its Causes, Species, Pathological Anatomy, Clinical History, Diagnosis, Prognosis and Treatment. 8vo, 8s.

THEOPHILUS PARVIN, M.D.
Professor of Obstetrics and Diseases of Women and Children at the Jefferson Medical School.

LECTURES ON OBSTETRIC NURSING, Delivered at the Training School for Nurses of the Philadelphia Hospital. Post 8vo, 2s. 6d.

E. RANDOLPH PEASLEE, M.D., LL.D.
Late Professor of Gynæcology in the Medical Department of Dartmouth College; President of the New York Academy of Medicine, &c., &c.

OVARIAN TUMOURS: Their Pathology, Diagnosis, and Treatment, especially by Ovariotomy. Illustrations, roy. 8vo, 16s.

G. V. POORE, M.D., F.R.C.P.
Professor of Medical Jurisprudence, University College; Assistant Physician to, and Physician in charge of the Throat Department of, University College Hospital.

LECTURES ON THE PHYSICAL EXAMINATION OF THE MOUTH AND THROAT. With an Appendix of Cases. 8vo, 3s. 6d.

R. DOUGLAS POWELL, M.D., F.R.C.P., M.R.C.S.
Physician Extraordinary to H.M. the Queen; Physician to the Middlesex Hospital and Physician to the Hospital for Consumption and Diseases of the Chest at Brompton.

DISEASES OF THE LUNGS AND PLEURÆ, INCLUD-ING CONSUMPTION. Third edition, entirely rewritten and enlarged. With coloured plates and wood engravings, 8vo, 16s.

URBAN PRITCHARD, M.D. EDIN., F.R.C.S. ENG.
Professor of Aural Surgery at King's College, London; Aural Surgeon to King's College Hospital; Senior Surgeon to the Royal Ear Hospital.

HANDBOOK OF DISEASES OF THE EAR FOR THE USE OF STUDENTS AND PRACTITIONERS. With Illustrations, crown 8vo, 4s. 6d. [LEWIS'S PRACTICAL SERIES.]

CHARLES W. PURDY, M.D. (QUEEN'S UNIV.)
Professor of Genito-Urinary and Renal Diseases in the Chicago Polyclinic, &c., &c.

BRIGHT'S DISEASE AND THE ALLIED AFFECTIONS OF THE KIDNEYS. With Illustrations, large 8vo, 8s. 6d.

CHARLES HENRY RALFE, M.A., M.D. CANTAB., F.R.C.P. LOND.
Assistant Physician to the London Hospital; Examiner in Medicine to the University of Durham, etc., etc.

A PRACTICAL TREATISE ON DISEASES OF THE KIDNEYS AND URINARY DERANGEMENTS. With Illustrations, crown 8vo, 10s. 6d. [LEWIS'S PRACTICAL SERIES.]

AMBROSE L. RANNEY, A.M., M.D.
Professor of the Anatomy and Physiology of the Nervous System in the New York Post-Graduate Medical School and Hospital; Professor of Nervous and Mental Diseases in the Medical Department of the University of Vermont.

THE APPLIED ANATOMY OF THE NERVOUS SYSTEM. Being a Study of this portion of the Human Body from a stand-point of its general interest and practical utility in Diagnosis, designed for use as a text-book and a work of reference. Second edit., 238 Illustrations, large 8vo, 21s. [*Just published.*

H. A. REEVES, F.R.C.S. EDIN.
Senior Assistant Surgeon and Teacher of Practical Surgery at the London Hospital; Surgeon to the Royal Orthopædic Hospital.

BODILY DEFORMITIES AND THEIR TREATMENT: A HANDBOOK OF PRACTICAL ORTHOPÆDICS. With numerous Illustrations, crown 8vo, 8s. 6d.
[LEWIS'S PRACTICAL SERIES].

RALPH RICHARDSON, M.A., M.D.
Fellow of the College of Physicians, Edinburgh.

ON THE NATURE OF LIFE: An Introductory Chapter to Pathology. Second edition, revised and enlarged. Fcap. 4to, 10s. 6d.

W. RICHARDSON, M.A., M.D., M.R.C.P.

REMARKS ON DIABETES, ESPECIALLY IN REFERENCE TO TREATMENT. Demy 8vo, 4s. 6d.

SAMUEL RIDEAL, D.SC. (LOND.), F.I.C., F.C.S., F.G.S.
Fellow of University College, London.

PRACTICAL ORGANIC CHEMISTRY; The Detection and Properties of some of the more important Organic Compounds. 12mo, 2s. 6d. [*Just published.*

E. A. RIDSDALE.
Associate of the Royal School of Mines.

COSMIC EVOLUTION; being Speculations on the Origin of our Environment. Fcap. 8vo, 3s.

SYDNEY RINGER, M.D., F.R.S.

Professor of the Principles and Practice of Medicine in University College; Physician to and Professor of Clinical Medicine in, University College Hospital.

I.

A HANDBOOK OF THERAPEUTICS. Twelfth Edition, thoroughly revised, 8vo, 15s.

II.

ON THE TEMPERATURE OF THE BODY AS A MEANS OF DIAGNOSIS AND PROGNOSIS IN PHTHISIS. Second edition, small 8vo, 2s. 6d.

FREDERICK T. ROBERTS, M.D., B.SC., F.R.C.P.

Examiner in Medicine at the University of London; Professor of Therapeutics and of Clinical Medicine in University College; Physician to University College Hospital; Physician to Brompton Consumption Hospital, &c.

I.

A HANDBOOK OF THE THEORY AND PRACTICE OF MEDICINE. Seventh edition, with Illustrations, in one volume, large 8vo, 21s.

*** *Copies may also be had bound in two volumes cloth for 1s. 6d. extra.*

II.

THE OFFICINAL MATERIA MEDICA.
Second edition, entirely rewritten in accordance with the latest British Pharmacopœia, fcap. 8vo, 7s. 6d.

R. LAWTON ROBERTS, M.D., M.R.C.S.

Honorary Life Member of, and Lecturer and Examiner to, the St. John Ambulance Association.

ILLUSTRATED LECTURES ON AMBULANCE WORK.
Third edition copiously Illustrated, crown 8vo, 2s. 6d.

D. B. St. JOHN ROOSA, M.A., M.D.

Professor of Diseases of the Eye and Ear in the University of the City of New York; Surgeon to the Manhattan Eye and Ear Hospital.

A PRACTICAL TREATISE ON THE DISEASES OF THE EAR, including the Anatomy of the Organ. Sixth edition, Illustrated by wood engravings and chromo-lithographs, large 8vo, 25s.

ROBSON ROOSE, M.D.
Fellow of the Royal College of Physicians in Edinburgh.

I.

GOUT, AND ITS RELATIONS TO DISEASES OF THE LIVER AND KIDNEYS. Sixth Edition, crown 8vo, 3s. 6d.

II.

NERVE PROSTRATION AND OTHER FUNCTIONAL DISORDERS OF DAILY LIFE. Crown 8vo, 10s. 6d.

III.

LEPROSY AND ITS TREATMENT: as Illustrated by Norwegian Experience. Crown 8vo, 3s. 6d.

BERNARD ROTH, F.R.C.S.
Fellow of the Medical Society of London; Member of the Clinical and Pathological Societies, and of the Medical Officers of Schools' Association.

THE TREATMENT OF LATERAL CURVATURE OF THE SPINE. With Photographic and other Illustrations, demy 8vo, 5s.

J. BURDON SANDERSON, M.D., LL.D., F.R.S.
Jodrell Professor of Physiology in University College, London.

UNIVERSITY COLLEGE COURSE OF PRACTICAL EXERCISES IN PHYSIOLOGY. With the co-operation of F. J. M. PAGE, B.Sc., F.C.S.; W. NORTH, B.A., F.C.S., and AUG. WALLER, M.D. Demy 8vo, 3s. 6d.

W. H. O. SANKEY, M.D. LOND., F.R.C.P.
Late Lecturer on Mental Diseases, University College, London, etc.

LECTURES ON MENTAL DISEASE. Second Edition, with coloured plates, 8vo, 12s. 6d.

JOHN SAVORY.
Member of the Society of Apothecaries, London.

A COMPENDIUM OF DOMESTIC MEDICINE AND COMPANION TO THE MEDICINE CHEST: Intended as a source of easy reference for Clergymen, Master Mariners, and Travellers; and for Families resident at a distance from professional assistance. Tenth Edition, sm. 8vo, 5s.

E. SCHMIEGELOW, M.D.
Consulting Physician in Laryngology to the Municipal Hospital and Director of the Oto-Laryngological Department in the Polyclinic at Copenhagen.

ASTHMA: Especially in its Relation to Nasal Disease.
Demy 8vo, 4s. 6d. [*Now ready.*

DR. B. S. SCHULTZE.
Professor of Gynecology; Director of the Lying-in Hospital, and of the Gynecological Clinic at Jena.

THE PATHOLOGY AND TREATMENT OF DISPLACEMENTS OF THE UTERUS. Translated by J. J. MACAN, M.A., M.R.C.S. and edited by A. V. MACAN, M.B., M.Ch., Master of the Rotunda Lying-in Hospital, Dublin. With 120 Illustrations, medium 8vo, 12s. 6d. [*Now ready.*

JOHN V. SHOEMAKER, A.M., M.D.
Professor of Skin Diseases in the Medico-Chirurgical College and Hospital of Philadelphia; Physician to the Philadelphia Hospital for Diseases of the Skin.

A PRACTICAL TREATISE ON DISEASES OF THE SKIN. Coloured Plates and other Illustrations, large 8vo, 24s.

WM. JAPP SINCLAIR, M.A., M.D.
Honorary Physician to the Manchester Southern Hospital for Women and Children, and Manchester Maternity Hospital.

ON GONORRHŒAL INFECTION IN WOMEN.
Post 8vo, 4s.

A. J. C. SKENE, M.D.
Professor of Gynecology in the Long Island College Hospital, Brooklyn, New York.

TREATISE ON THE DISEASES OF WOMEN, FOR THE USE OF STUDENTS AND PRACTITIONERS. Nine coloured plates and 251 engravings, large 8vo, 28s.

ALDER SMITH, M.B. LOND., F.R.C.S.
Resident Medical Officer, Christ's Hospital, London.

RINGWORM: Its Diagnosis and Treatment.
Third Edition, enlarged, with Illustrations, fcap. 8vo, 5s. 6d.

J. LEWIS SMITH, M.D.
Physician to the New York Infants' Hospital; Clinical Lecturer on Diseases of Children in Bellevue Hospital Medical College.

A TREATISE ON THE DISEASES OF INFANCY AND CHILDHOOD. Fifth Edition, with Illustrations, large 8vo, 21s.

FRANCIS W. SMITH, M.B., B.S.

THE SALINE WATERS OF LEAMINGTON. Second Edit., with Illustrations, crown 8vo, 1s. *nett.*

JOHN KENT SPENDER, M.D. LOND.

Physician to the Royal Mineral Water Hospital, Bath.

THE EARLY SYMPTOMS AND THE EARLY TREATMENT OF OSTEO-ARTHRITIS, commonly called Rheumatoid Arthritis, with special reference to the Bath Thermal Waters. Sm. 8vo. 2s. 6d.

LOUIS STARR, M.D.

Clinical Professor of Diseases of Children in the Hospital of the University of Pennsylvania; Physician to the Children's Hospital, Philadelphia, &c.

HYGIENE OF THE NURSERY. Including the General Regimen and Feeding of Infants and Children, and the Domestic Management of the Ordinary Emergiences of Early Life. Second edition, with Illustrations, crown 8vo, 3s. 6d. [*Just published.*

JAMES STARTIN, M.B., M.R.C.S.

Surgeon and Joint Lecturer to St. John's Hospital for Diseases of the Skin.

LECTURES ON THE PARASITIC DISEASES OF THE SKIN. VEGETOID AND ANIMAL. With Illustrations, crown 8vo, 2s. 6d.

W. R. H. STEWART, F.R.C.S., L.R.C.P. EDIN.

Aural Surgeon to the Great Northern Central Hospital; Surgeon to the London Throat Hospital, &c.

EPITOME OF DISEASES AND INJURIES OF THE EAR, with a Chapter on Naso-Pharyngeal Diseases causing Deafness. Demy 32mo, 2s. 6d.

LEWIS A. STIMSON, B.A., M.D.

Surgeon to the Presbyterian and Bellevue Hospitals; Professor of Clinical Surgery in the Medical Faculty of the University of the City of New York, &c.

A MANUAL OF OPERATIVE SURGERY.
Second Edition, with three hundred and forty-two Illustrations, post 8vo, 10s. 6d.

ADOLF STRÜMPELL.

Director of the Medical Clinic in the University of Erlangen.

A TEXT-BOOK OF MEDICINE FOR STUDENTS AND PRACTITIONERS. Translated from the latest German edition by Dr. H. F. VICKERY and Dr. P. C. KNAPP, with Editorial Notes by Dr. F. C. SHATTUCK, Visiting Physician to the Massachusetts General Hospital, etc. Complete in one large vol., imp. 8vo, with 111 Illustrations, 28s.

JUKES DE STYRAP, M.K.Q.C.P., ETC.

Physician-Extraordinary, late Physician in Ordinary, to the Salop Infirmary; Consulting Physician to the South Salop and Montgomeryshire Infirmaries, etc.

THE MEDICO-CHIRURGICAL TARIFFS PREPARED FOR THE LATE SHROPSHIRE ETHICAL BRANCH OF THE BRITISH MEDICAL ASSOCIATION. Fourth Edition, fcap. 4to, revised and enlarged, 2s. *nett.*

C. W. SUCKLING, M.D. LOND., M.R.C.P.

Professor of Materia Medica and Therapeutics at the Queen's College, Physician to the Queen's Hospital, Birmingham, etc.

ON THE DIAGNOSIS OF DISEASES OF THE BRAIN, SPINAL CORD, AND NERVES. With Illustrations, crown 8vo, 8s. 6d.

JOHN BLAND SUTTON, F.R.C.S.

Lecturer on Comparative Anatomy, Senior Demonstrator of Anatomy, and Assistant Surgeon to the Middlesex Hospital; Erasmus Wilson Lecturer, Royal College of Surgeons, England.

LIGAMENTS: THEIR NATURE AND MORPHOLOGY. With numerous Illustrations, post 8vo, 4s. 6d.

HENRY R. SWANZY, A.M., M.B., F.R.C.S.I.

Examiner in Ophthalmic Surgery in the Royal University of Ireland, and to the Conjoint Board of the King and Queen's College of Physicians and Royal College of Surgeons, Ireland; Surgeon to the National Eye and Ear Infirmary, Dublin, etc.

A HANDBOOK OF THE DISEASES OF THE EYE AND THEIR TREATMENT. Second Edition, Illustrated with wood-engravings, colour tests, etc., small 8vo, 10s. 6d.

EUGENE S. TALBOT, M.D., D.D.S.

Professor of Dental Surgery in the Woman's Medical College; Lecturer on Dental Pathology and Surgery in Rush Medical College, Chicago.

IRREGULARITIES OF THE TEETH AND THEIR TREATMENT. With 152 Illustrations, royal 8vo, 10s. 6d.

H. COUPLAND TAYLOR, M.D.

Fellow of the Royal Meteorological Society.

WANDERINGS IN SEARCH OF HEALTH, OR MEDICAL AND METEOROLOGICAL NOTES ON VARIOUS FOREIGN HEALTH RESORTS. Crown 8vo, with illustrations, 6s.

[*Just ready*

JOHN DAVIES THOMAS, M.D. LOND., F.R.C.S. ENG.
Physician to the Adelaide Hospital, S. Australia

I.

HYDATID DISEASE, WITH SPECIAL REFERENCE TO ITS PREVALENCE IN AUSTRALIA. Demy 8vo, 10s. 6d.

II.

HYDATID DISEASE OF THE LUNGS. Demy 8vo, 2s.

HUGH OWEN THOMAS, M.R.C.S.

I.

DISEASES OF THE HIP, KNEE, AND ANKLE JOINTS, with their Deformities, treated by a new and efficient method. Third Edition, 8vo, 25s.

II.

CONTRIBUTIONS TO SURGERY AND MEDICINE:—

PART 1.—Intestinal Obstruction; with an Appendix on the Action of Remedies. 10s.

" 2.—The Principles of the Treatment of Joint Disease, Inflammation, Anchylosis, Reduction of Joint Deformity, Bone Setting. 5s.

" 3.—Fractures, Dislocations, Diseases and Deformities of the Bones of the Trunk and Upper Extremities. 10s.

4.—The Collegian of 1666 and the Collegians of 1885; or what is recognised treatment? Second Edition, 1s.

5.—On Fractures of the Lower Jaw. 1s.

" 6.—The Principles of the Treatment of Fractures and Dislocations. 10s.

" 8.—The Inhibition of Nerves by Drugs. Proof that Inhibitory Nerve-Fibres do not exist. 1s.

(Parts 7, 9 and 10 are in preparation).

J. ASHBURTON THOMPSON, M.R.C.S.
Late Surgeon at King's Cross to the Great Northern Railway Company.

FREE PHOSPHORUS IN MEDICINE WITH SPE-CIAL REFERENCE TO ITS USE IN NEURALGIA. A contribution to Materia Medica and Therapeutics. An account of the History, Pharmaceutical Preparations, Dose, Internal Administration, and Therapeutic uses of Phosphorus; with a Complete Bibliography of this subject, referring to nearly 200 works upon it. Demy 8vo, 7s. 6d.

J. C. THOROWGOOD, M.D.

Assistant Physician to the City of London Hospital for Diseases of the Chest

THE CLIMATIC TREATMENT OF CONSUMPTION AND CHRONIC LUNG DISEASES. Third Edition, post 8vo, 3s 6d.

FREDERICK TREVES, F.R.C.S.

Hunterian Professor at the Royal College of Surgeons of England; Surgeon to and Lecturer on Anatomy at the London Hospital.

THE ANATOMY OF THE INTESTINAL CANAL AND PERITONEUM IN MAN. Hunterian Lectures, 1885. 4to, 2s. 6d.

D. HACK TUKE, M.D., LL.D.

Fellow of the Royal College of Physicians, London.

THE INSANE IN THE UNITED STATES AND CANADA. Demy 8vo, 7s. 6d.

DR. R. ULTZMANN.

ON STERILITY AND IMPOTENCE IN MAN. Translated from the German with notes and additions by ARTHUR COOPER, L.R.C.P., M.R.C.S., Surgeon to the Westminster General Dispensary. With Illustrations, fcap. 8vo, 2s. 6d.

W. H. VAN BUREN, M.D., LL.D.

Professor of Surgery in the Bellevue Hospital Medical College.

DISEASES OF THE RECTUM: And the Surgery of the Lower Bowel. Second Edition, with Illustrations, 8vo, 14s.

RUDOLPH VIRCHOW, M.D.

Professor in the University, and Member of the Academy of Sciences of Berlin, &c., &c.

INFECTION-DISEASES IN THE ARMY, Chiefly Wound Fever, Typhoid, Dysentery, and Diphtheria. Translated from the German by JOHN JAMES, M.B., F.R.C.S. Fcap. 8vo, 1s. 6d.

ALFRED VOGEL, M.D.
Professor of Clinical Medicine in the University of Dorpat, Russia.

A PRACTICAL TREATISE ON THE DISEASES OF CHILDREN. Third Edition, translated and edited by H. RAPHAEL, M.D., from the Eighth German Edition, illustrated by six lithographic plates, part coloured, royal 8vo, 18s.

A. DUNBAR WALKER, M.D., C.M.

THE PARENT'S MEDICAL NOTE BOOK. Oblong post 8vo, cloth, 1s. 6d.

JOHN RICHARD WARDELL, M.D. EDIN., F.R.C.P. LOND.
Late Consulting Physician to the General Hospital Tunbridge Wells.

CONTRIBUTIONS TO PATHOLOGY AND THE PRACTICE OF MEDICINE. Medium 8vo, 21s.

W. SPENCER WATSON, F.R.C.S. ENG., B.M. LOND.
Surgeon to the Great Northern Hospital; Surgeon to the Royal South London Ophthalmic Hospital.

I.

DISEASES OF THE NOSE AND ITS ACCESSORY CAVITIES. Profusely Illustrated. Demy 8vo, 18s.

II.

EYEBALL-TENSION: Its Effects on the Sight and its Treatment. With woodcuts, p. 8vo, 2s. 6d.

III.

ON ABSCESS AND TUMOURS OF THE ORBIT. Post 8vo, 2s. 6d.

FRANCIS H. WELCH, F.R.C.S.
Surgeon Major, A.M.D.

ENTERIC FEVER: as Illustrated by Army Data at Home and Abroad, its Prevalence and Modifications, Ætiology, Pathology and Treatment. 8vo, 5s. 6d.

W. WYNN WESTCOTT, M.B.
Deputy Coroner for Central Middlesex.

SUICIDE; its History, Literature, Jurisprudence, and Prevention. Crown 8vo, 6s.

E. G. WHITTLE, M.D. LOND., F.R.C.S. ENG.
Senior Surgeon to the Royal Alexandra Hospital for Sick Children, Brighton

CONGESTIVE NEURASTHENIA, OR INSOMNIA AND NERVE DEPRESSION. Crown 8vo, 3s. 6d.
[*Just published.*

JOHN WILLIAMS, M.D., F.R.C.P.
Professor of Midwifery in University College, London; Obstetric Physician to University College Hospital; Physician Accoucheur to H.R.H. Princess Beatrice, etc.

CANCER OF THE UTERUS: Being the Harveian Lectures for 1886. Illustrated with Lithographic Plates, royal 8vo, 10s. 6d.

E. T. WILSON, B.M. OXON., F.R.C.P. LOND.
Physician to the Cheltenham General Hospital and Dispensary.

DISINFECTANTS AND HOW TO USE THEM. In Packets of one doz. price 1s.

DR. F. WINCKEL.
Formerly Professor and Director of the Gynæcological Clinic at the University of Rostock.

THE PATHOLOGY AND TREATMENT OF CHILD-BED: A Treatise for Physicians and Students. Translated from the Second German edition, with many additional notes by the Author, by J. R. CHADWICK, M.D. 8vo, 14s.

BERTRAM C. A. WINDLE, M.A., M.D. DUBL.
Professor of Anatomy in the Queen's College, Birmingham; Examiner in Anatomy in the Universities of Cambridge and Durham.

A HANDBOOK OF SURFACE ANATOMY AND LAND-MARKS. Post 8vo, illustrations, 3s. 6d.

EDWARD WOAKES, M.D. LOND.

Senior Aural Surgeon and Lecturer on Aural Surgery at the London Hospital; Surgeon to the London Throat Hospital.

I.

ON DEAFNESS, GIDDINESS AND NOISES IN THE HEAD.

VOL. I.—POST-NASAL CATARRH, AND DISEASES OF THE NOSE CAUSING DEAFNESS. With Illustrations, cr. 8vo, 6s. 6d.

VOL. II.—ON DEAFNESS, GIDDINESS AND NOISES IN THE HEAD. Third Edition, with Illustrations, cr. 8vo. [*In preparation.*

II.

NASAL POLYPUS: WITH NEURALGIA, HAY-FEVER, AND ASTHMA, IN RELATION TO ETHMOIDITIS. With Illustrations, cr. 8vo, 4s. 6d.

DAVID YOUNG, M.C., M.B., M.D.

Licentiate of the Royal College of Physicians, Edinburgh; Licentiate of the Royal College of Surgeons, Edinburgh, etc.

ROME IN WINTER AND THE TUSCAN HILLS IN SUMMER. A CONTRIBUTION TO THE CLIMATE OF ITALY. Small 8vo, 6s.

HERMANN VON ZEISSL, M.D.

Late Professor at the Imperial Royal University of Vienna,

OUTLINES OF THE PATHOLOGY AND TREAT-MENT OF SYPHILIS AND ALLIED VENEREAL DISEASES. Second Edition, revised by M. VON ZEISSL, M.D., Privat-Docent for Diseases of the Skin and Syphilis at the Imperial Royal University of Vienna. Translated, with Notes, by H. RAPHAEL, M.D., Attending Physician for Diseases of Genito-Urinary Organs and Syphilis, Bellevue Hospital, Out-Patient Department. Large 8vo, 18s. [*Just published*

Clinical Charts For Temperature Observations, etc.

Arranged by W. RIGDEN, M.R.C.S. 50s. per 1000, 28s. per 500, 15s. per 250, 7s. per 100, or 1s. per dozen.

Each Chart is arranged for four weeks, and is ruled at the back for making notes of Cases; they are convenient in size, and are suitable both for hospital and private practice.

THE NEW SYDENHAM SOCIETY'S PUBLICATIONS.

President :—W. T. Gairdner, M.D., LL.D.
Honorary Secretary :—Jonathan Hutchinson, Esq., F.R.S.
Treasurer :—W. Sedgwick Saunders, M.D., F.S.A.

Annual Subscription, One Guinea.

The Society issues translations of recent standard works by continental authors on subjects of general interest to the profession.

Amongst works recently issued are "Cohnheim's Pathology," "Henoch's Children," "Spiegelberg's Midwifery," "Hirsch's Historical and Geographical Pathology," "Essays on Micro-Parasites," works by Charcot, Duchenne, Begbie, Billroth, Graves, Koch, Hebra, Guttmann, etc.

The Society also has in hand an Atlas of Pathology with Coloured Plates, and a valuable and exhaustive "Lexicon of Medicine and the Allied Sciences."

The Annual Report, with full list of works published, and all further information will be sent on application.

PERIODICAL WORKS PUBLISHED BY H. K. LEWIS.

THE BRITISH JOURNAL OF DERMATOLOGY. Edited by Malcolm Morris and H. G. Brooke. Published monthly, 1s. Annual Subscription 12s. post free.

THE NEW YORK MEDICAL JOURNAL. A Weekly Review of Medicine. Annual Subscription, One Guinea, post free.

THE THERAPEUTIC GAZETTE. A Monthly Journal, devoted to the Science of Pharmacology, and to the introduction of New Therapeutic Agents. Edited by Drs. H. C. Wood and R. M. Smith. Annual Subscription, 10s., post free.

THE GLASGOW MEDICAL JOURNAL. Published Monthly. Annual Subscription 20s., post free. Single numbers, 2s. each.

LIVERPOOL MEDICO-CHIRURGICAL JOURNAL, including the Proceedings of the Liverpool Medical Institution. Published twice yearly, 3s. 6d. each number.

TRANSACTIONS OF THE COLLEGE OF PHYSICIANS OF PHILADELPHIA. Volumes I. to VI., 8vo, 10s. 6d. each.

MIDDLESEX HOSPITAL, REPORTS OF THE MEDICAL, SURGICAL, AND Pathological Registrars for 1883 to 1888. Demy 8vo, 2s. 6d. *nett* each volume.

*** Mr. Lewis is in constant communication with the leading publishing firms in America, and has transactions with them for the sale of his publications in that country. Advantageous arrangements are made in the interests of Authors for the publishing of their works in the United States.

Mr. Lewis's publications can be procured of all Booksellers in any part of the world.

London: Printed by H. K. Lewis, 136 Gower Street, W.C.

12

8.A.262
A textbook of morbid histology 1892
Countway Library
BDM6570
3 2044 045 438 025

8.A.262
A textbook of morbid histology 1892
Countway Library BDM6570
3 2044 045 438 025